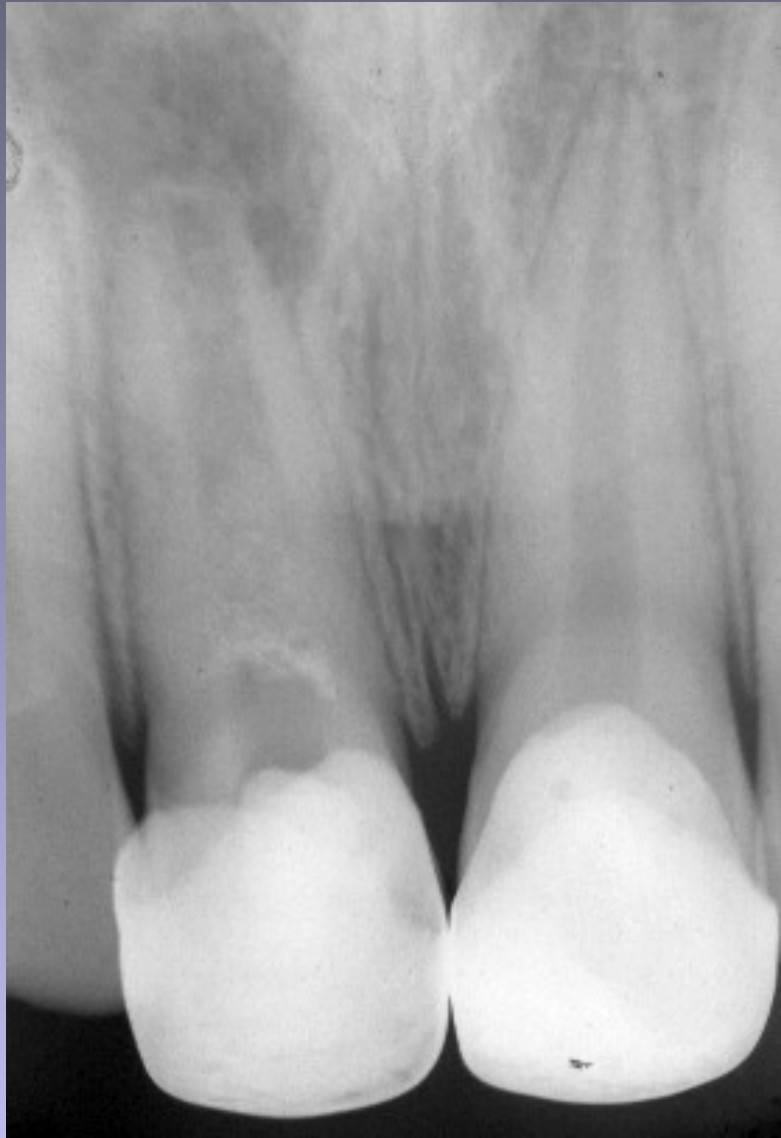

TRAUMATISMO

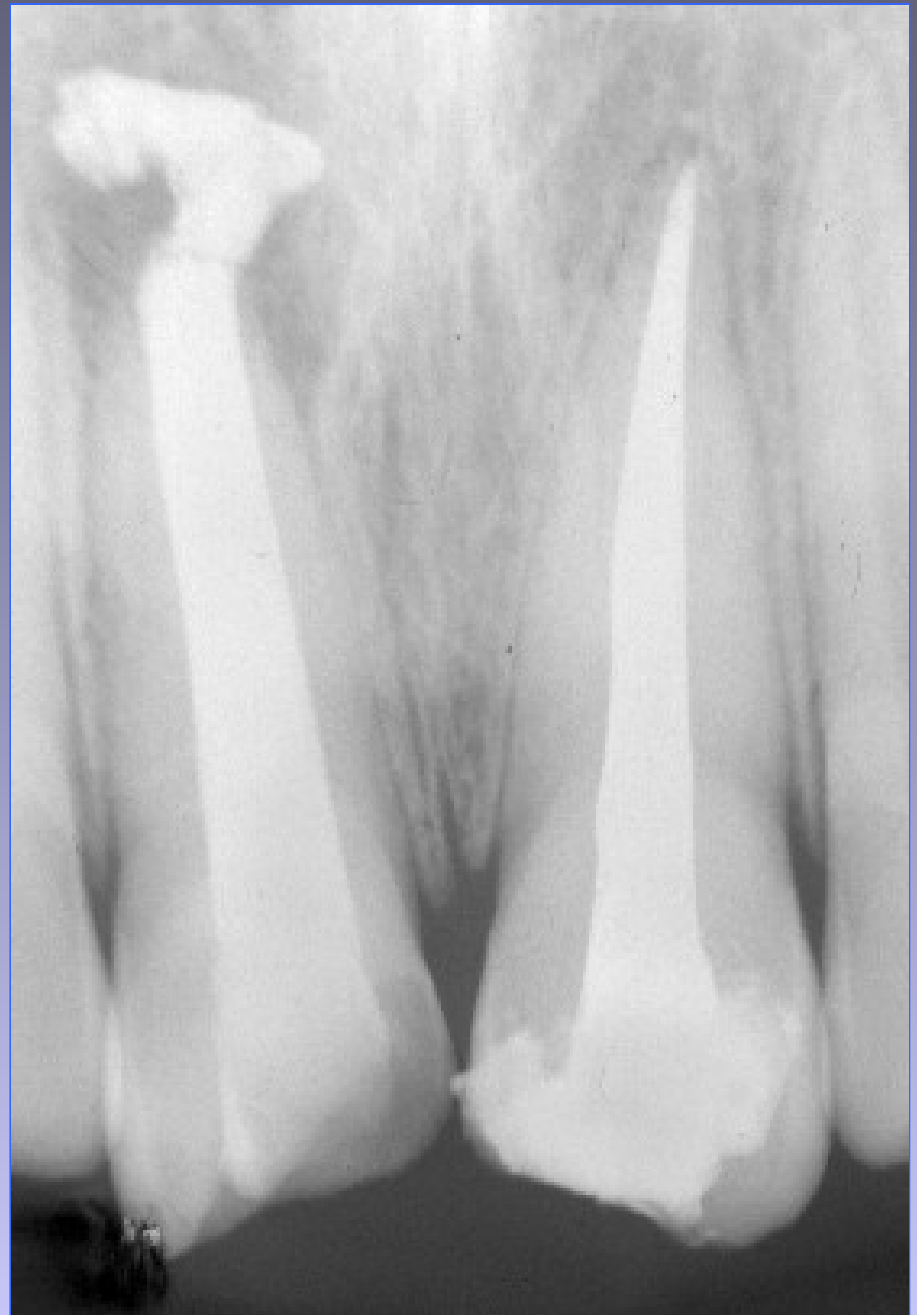CLÍNICO

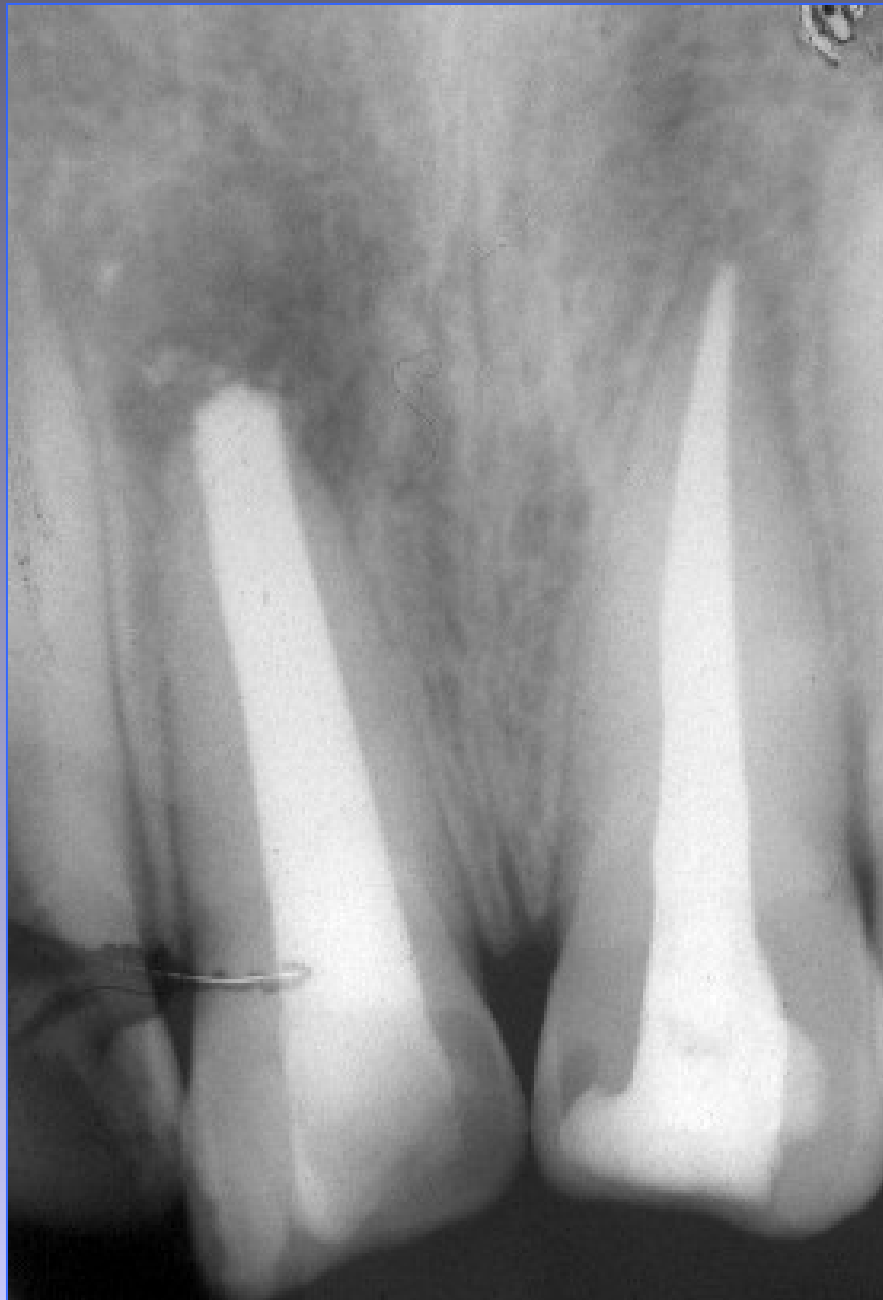Fracturas Coronarias



**Fractura coronaria con
muerte pulpar.**

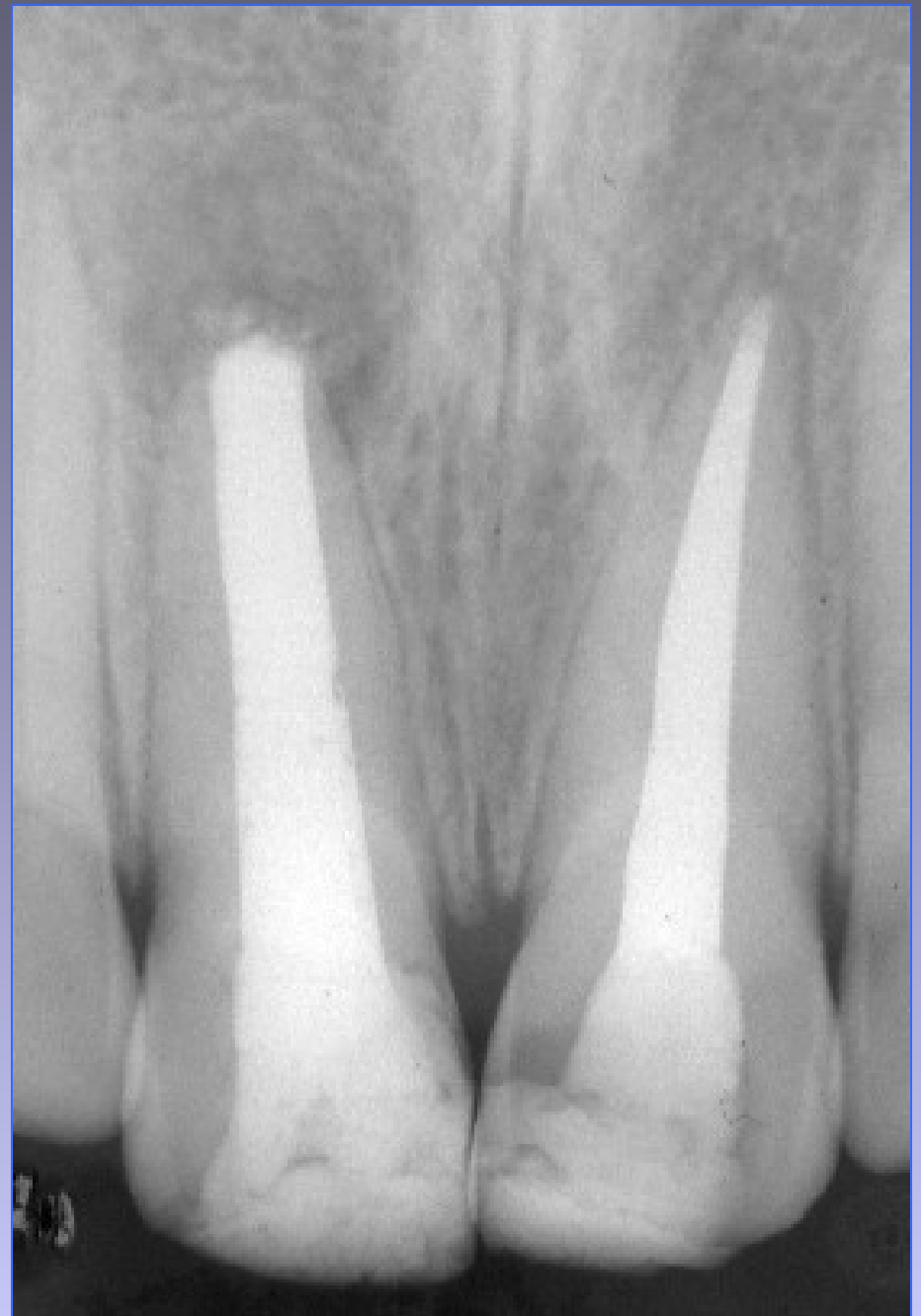**Tratamiento intermedio
Con protocolo de
Apicoformación**

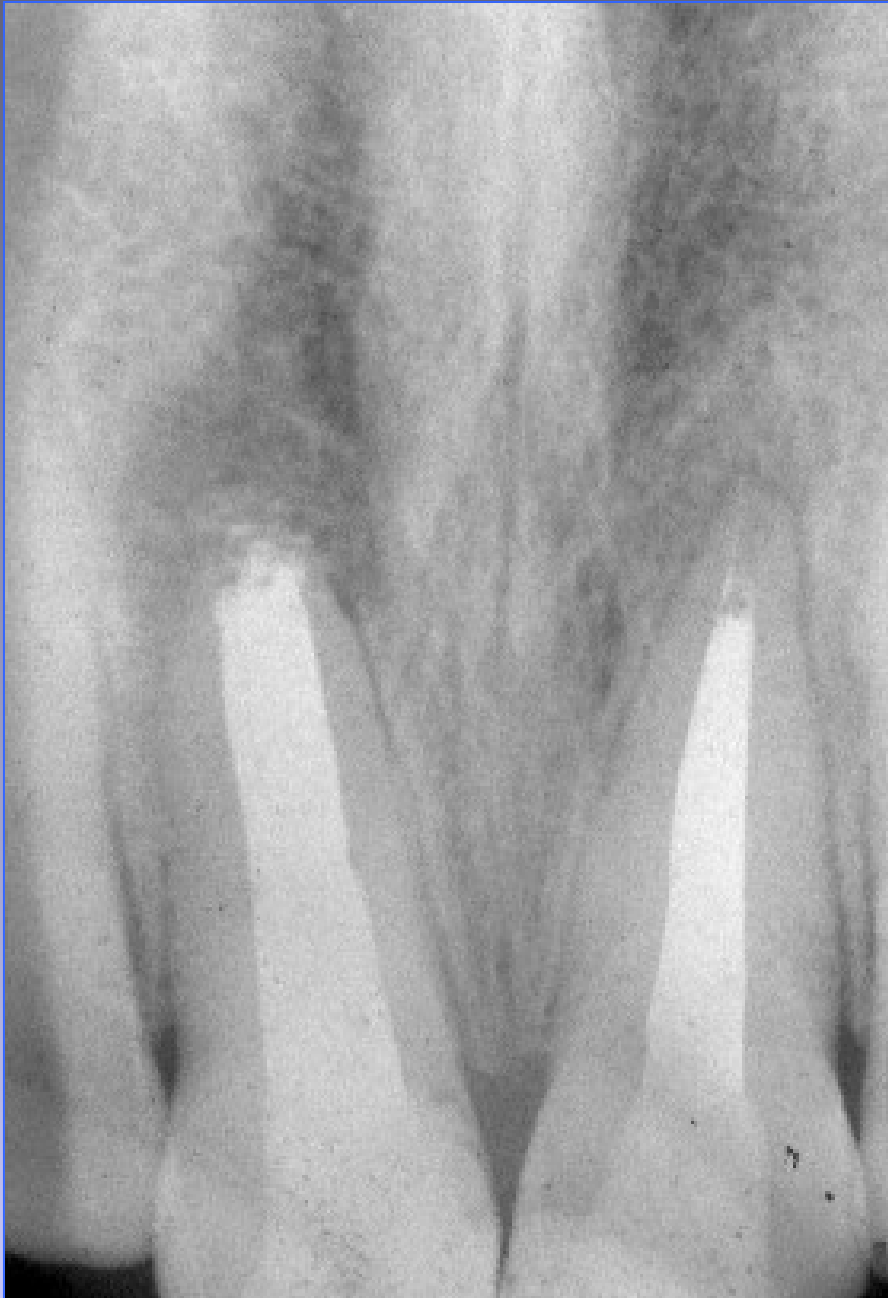



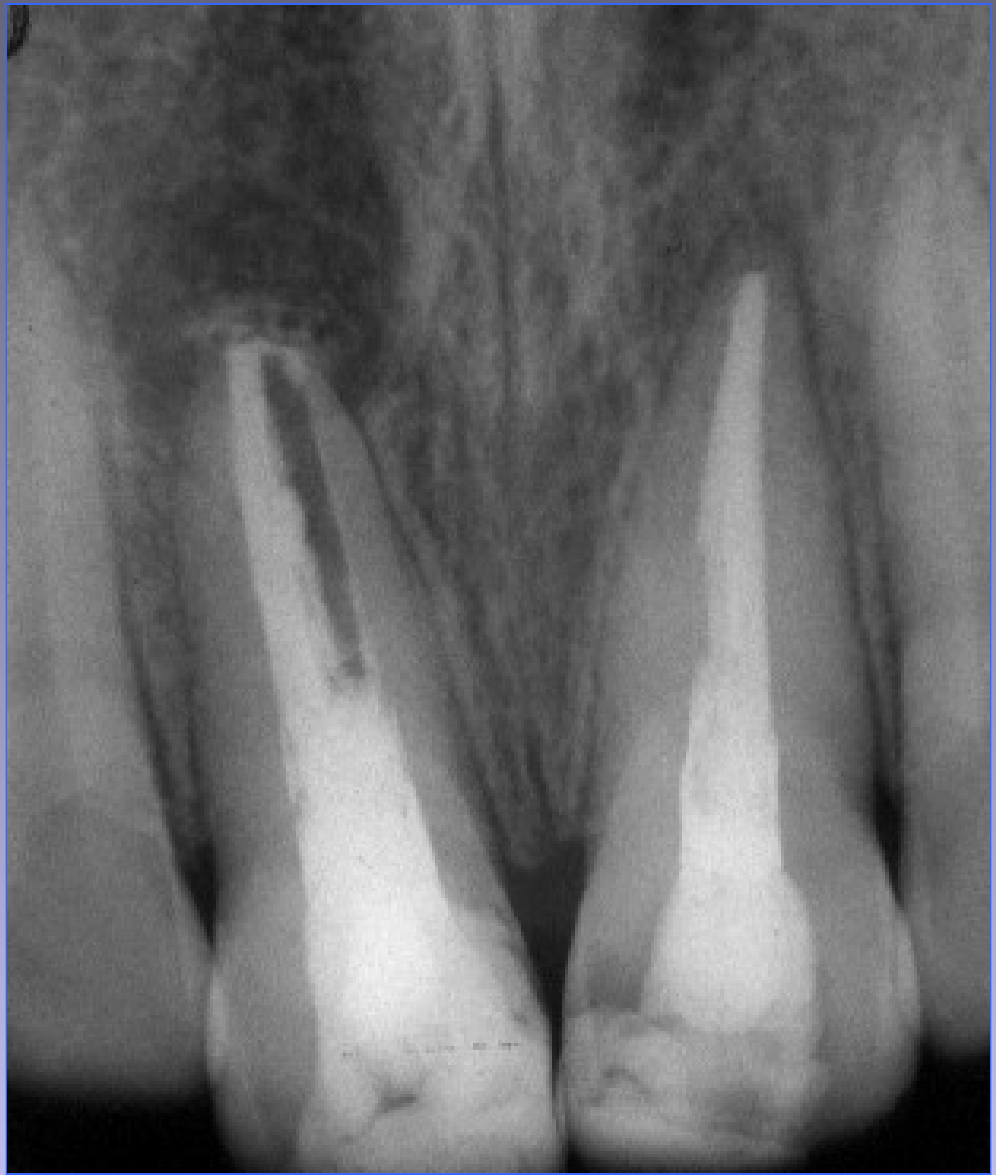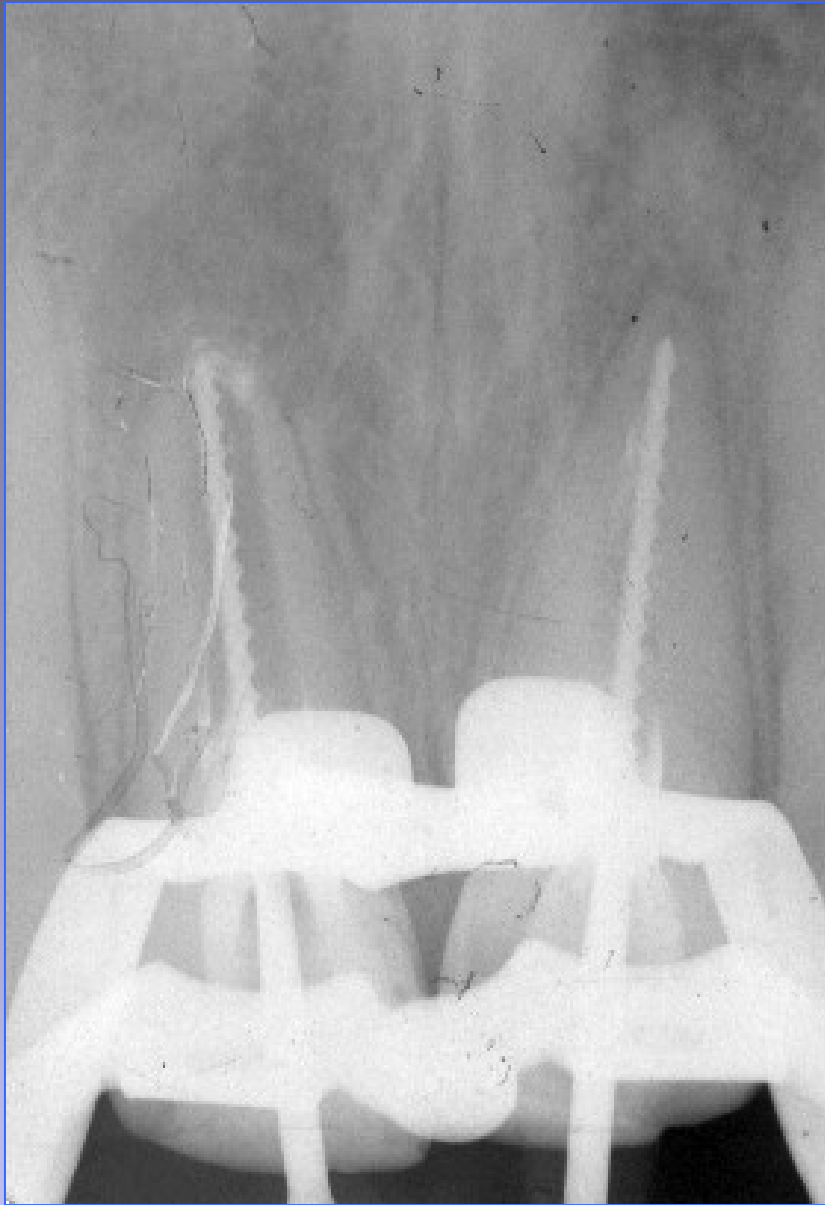
**Controles
a distancia**

**Curación del proceso
periapical y cierre apical.**

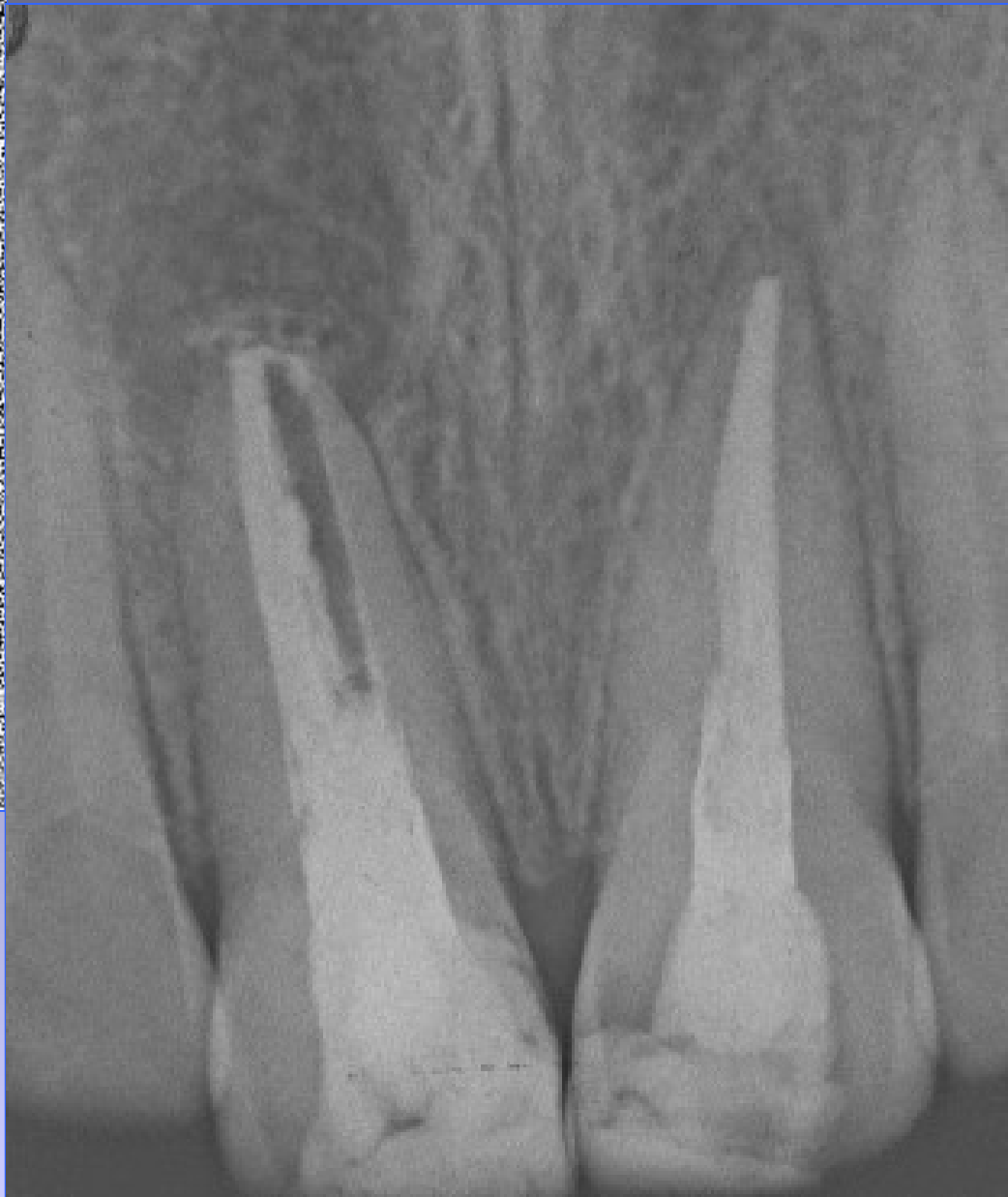

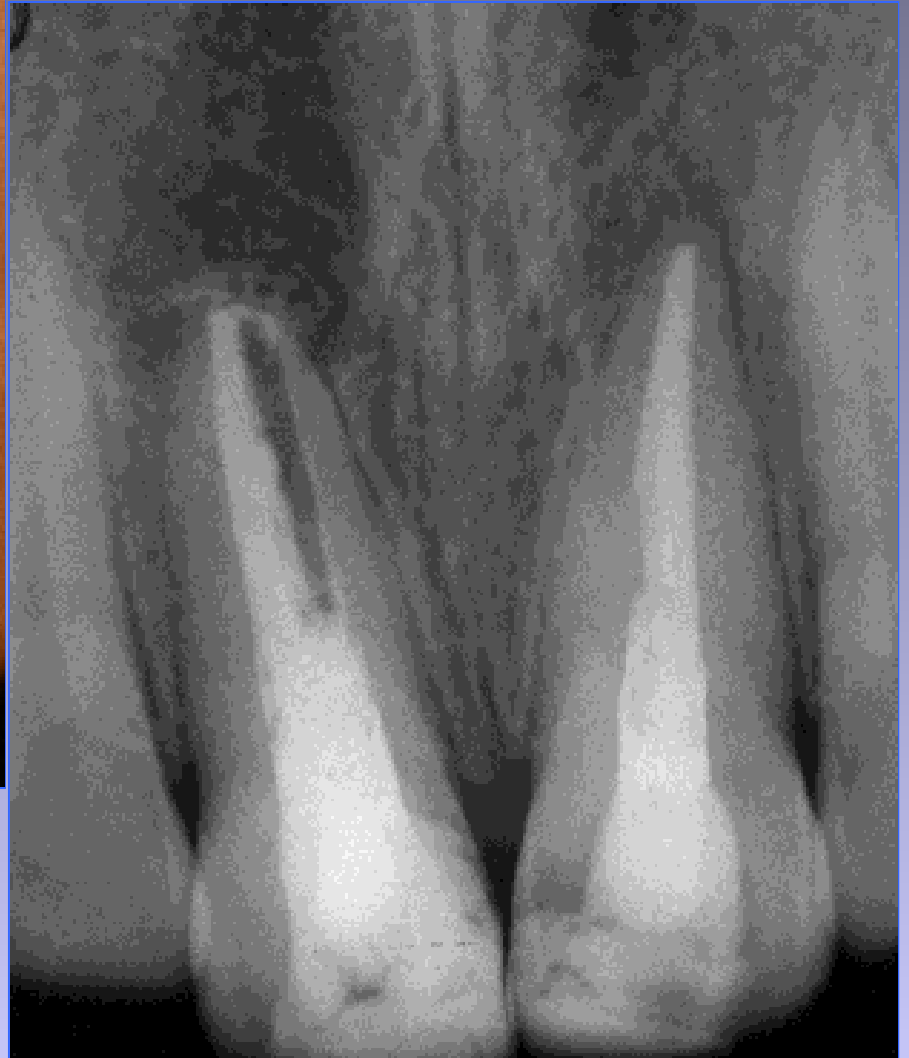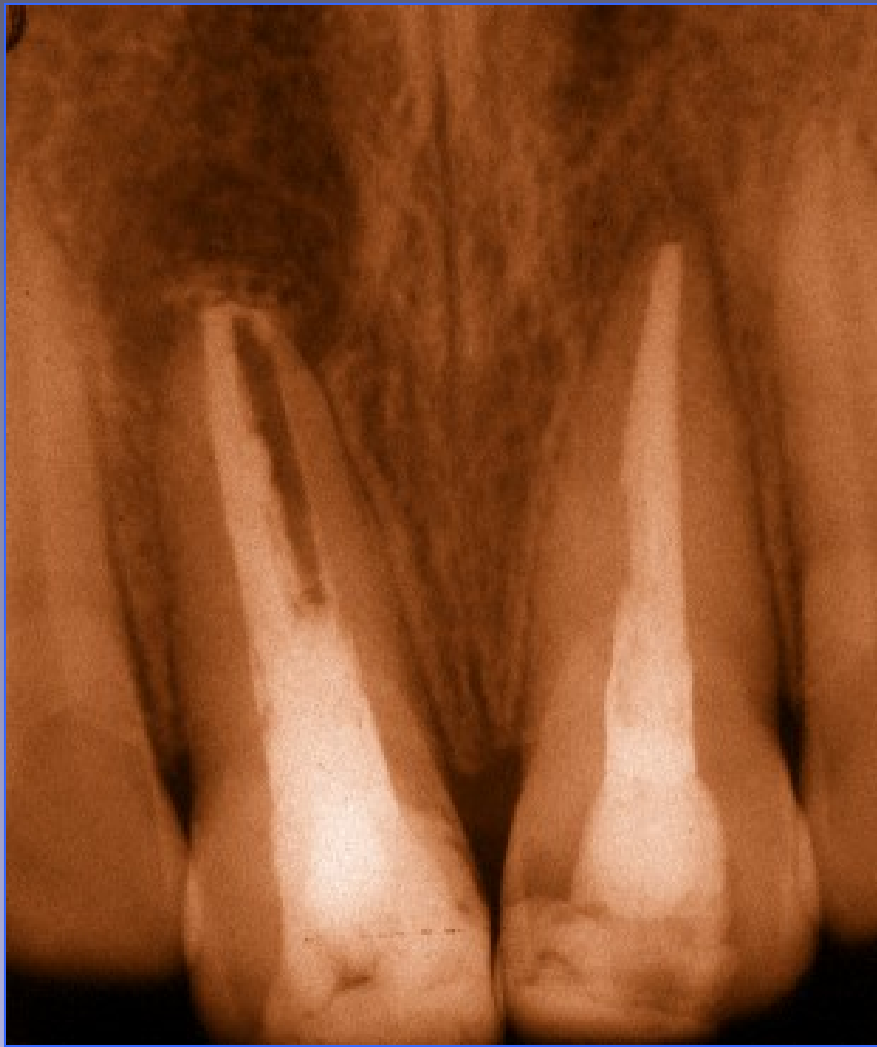


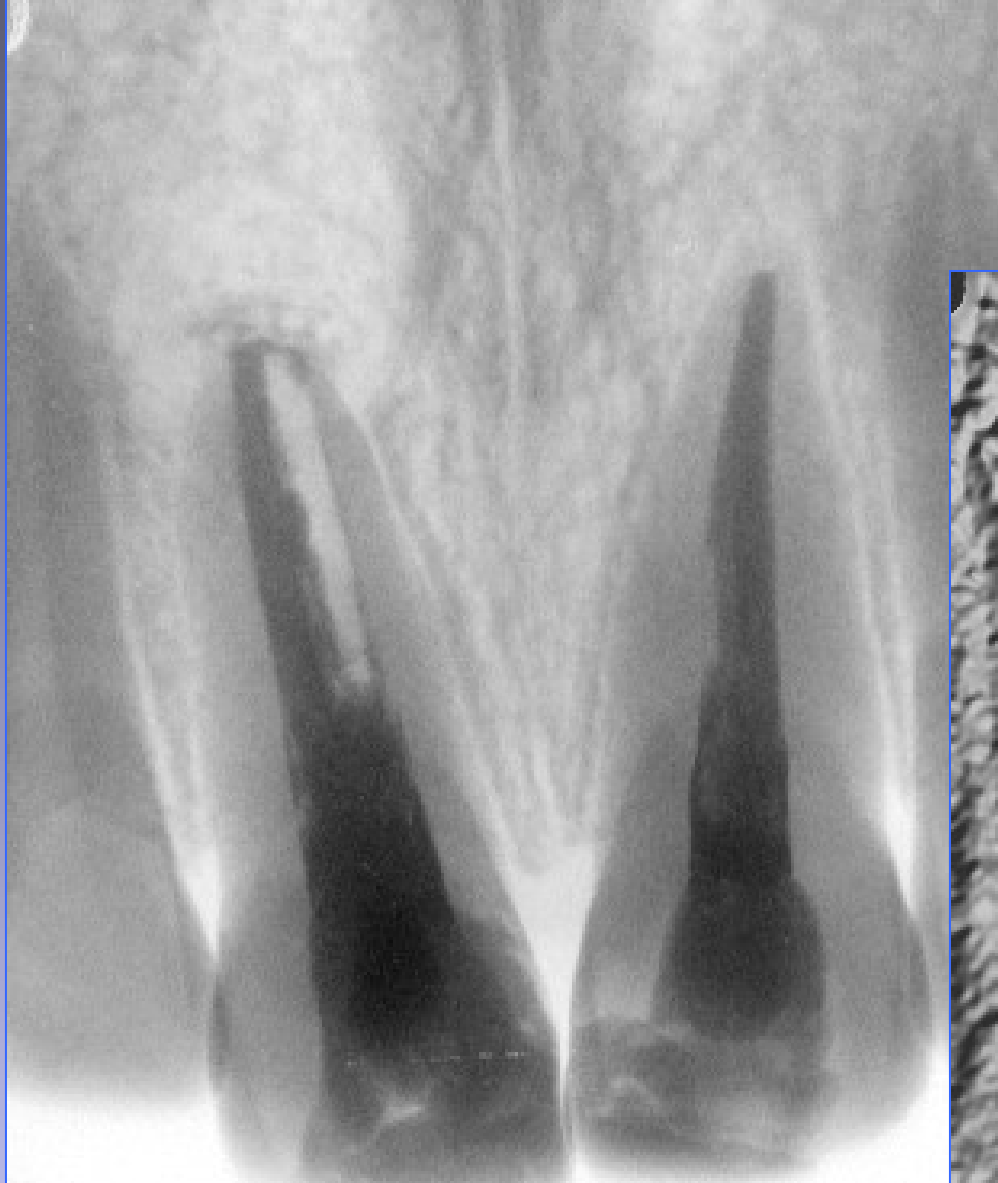Control

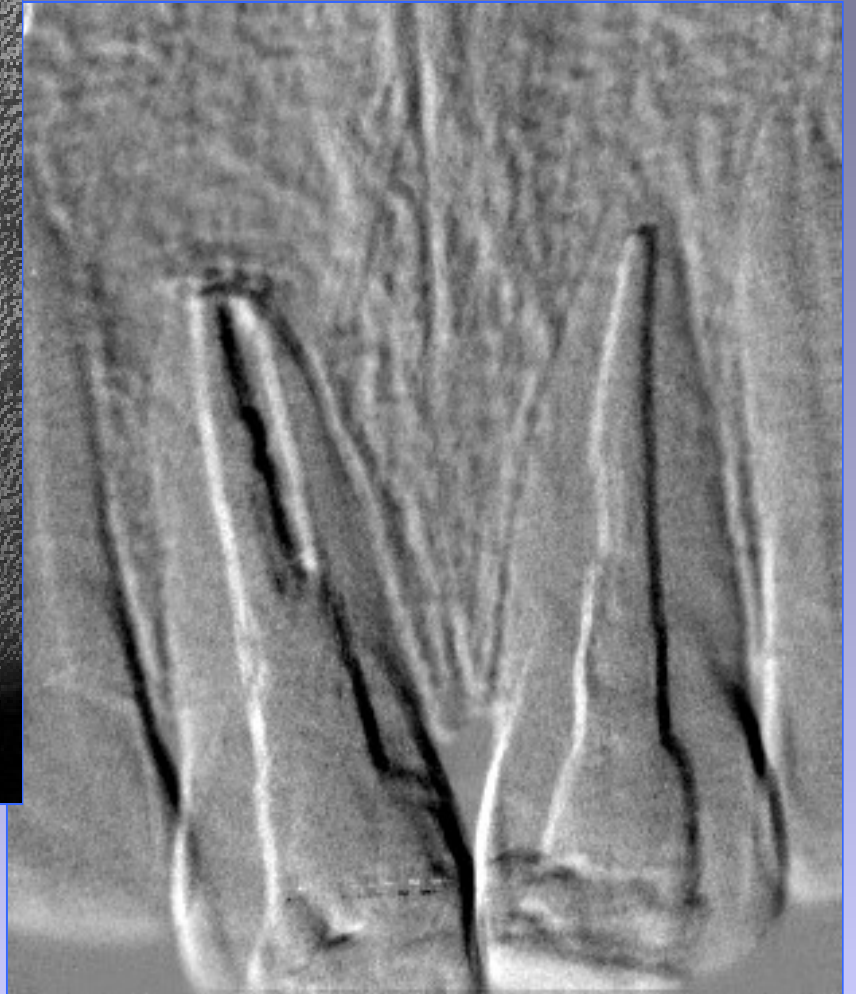
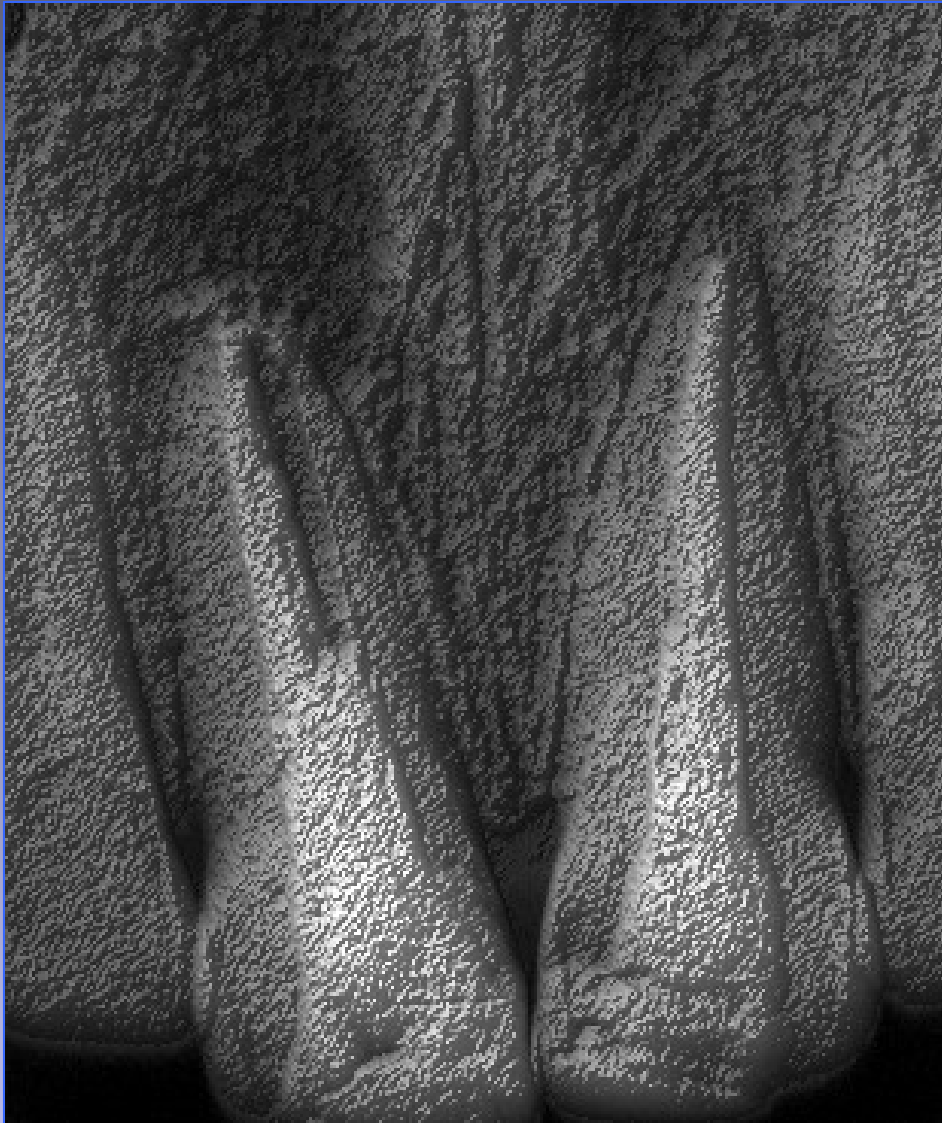

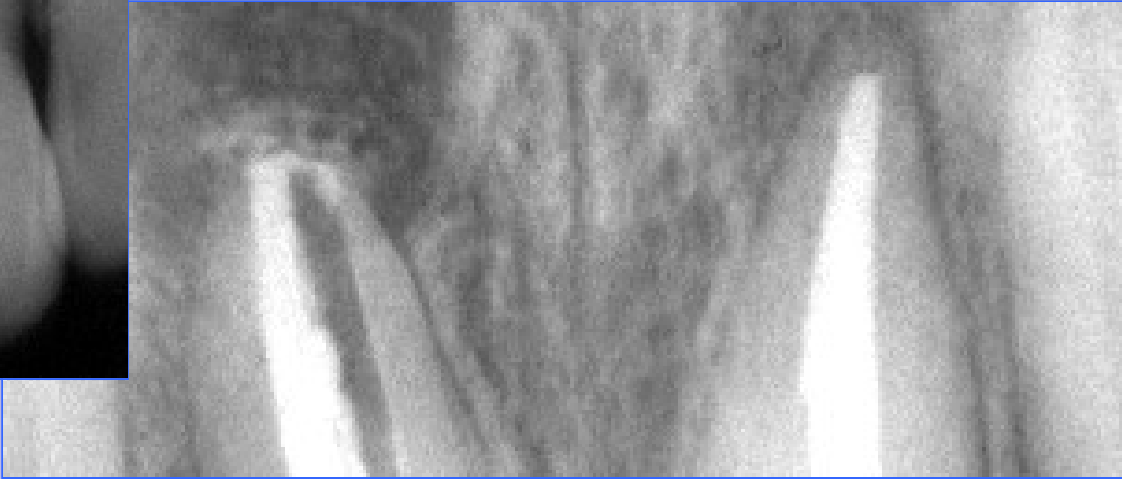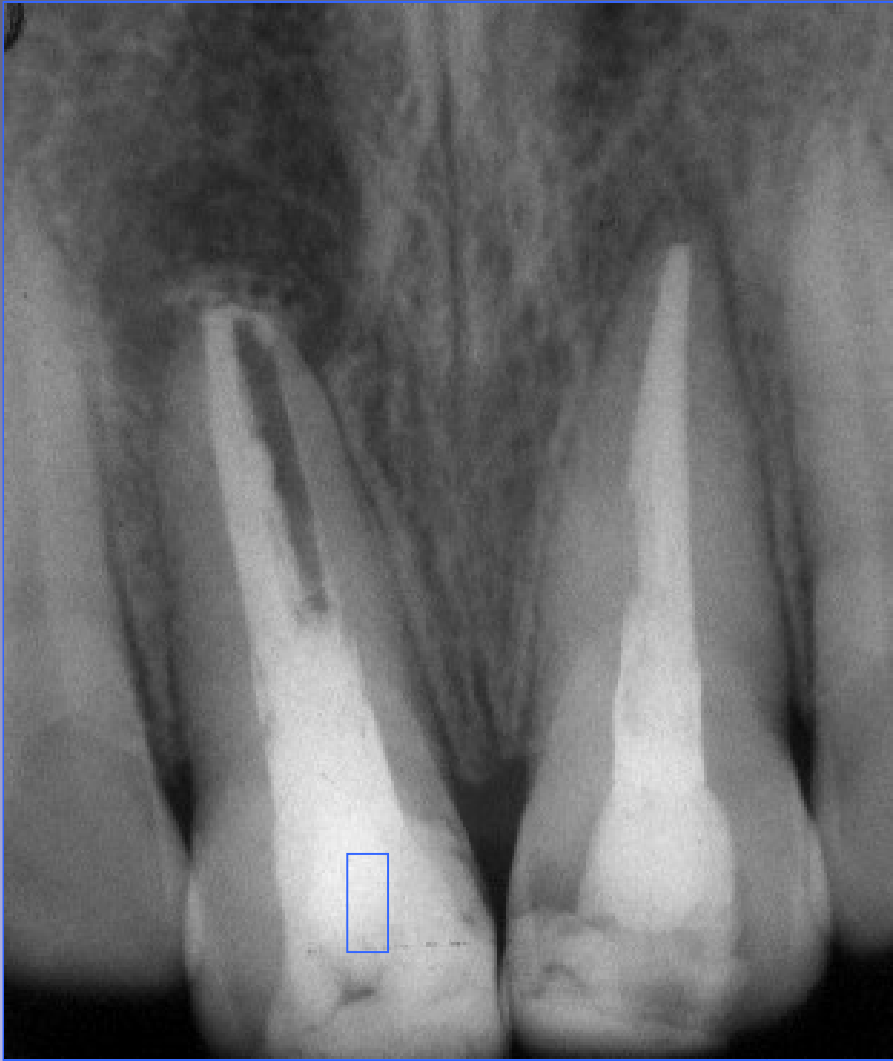Tratamiento Definitivo.



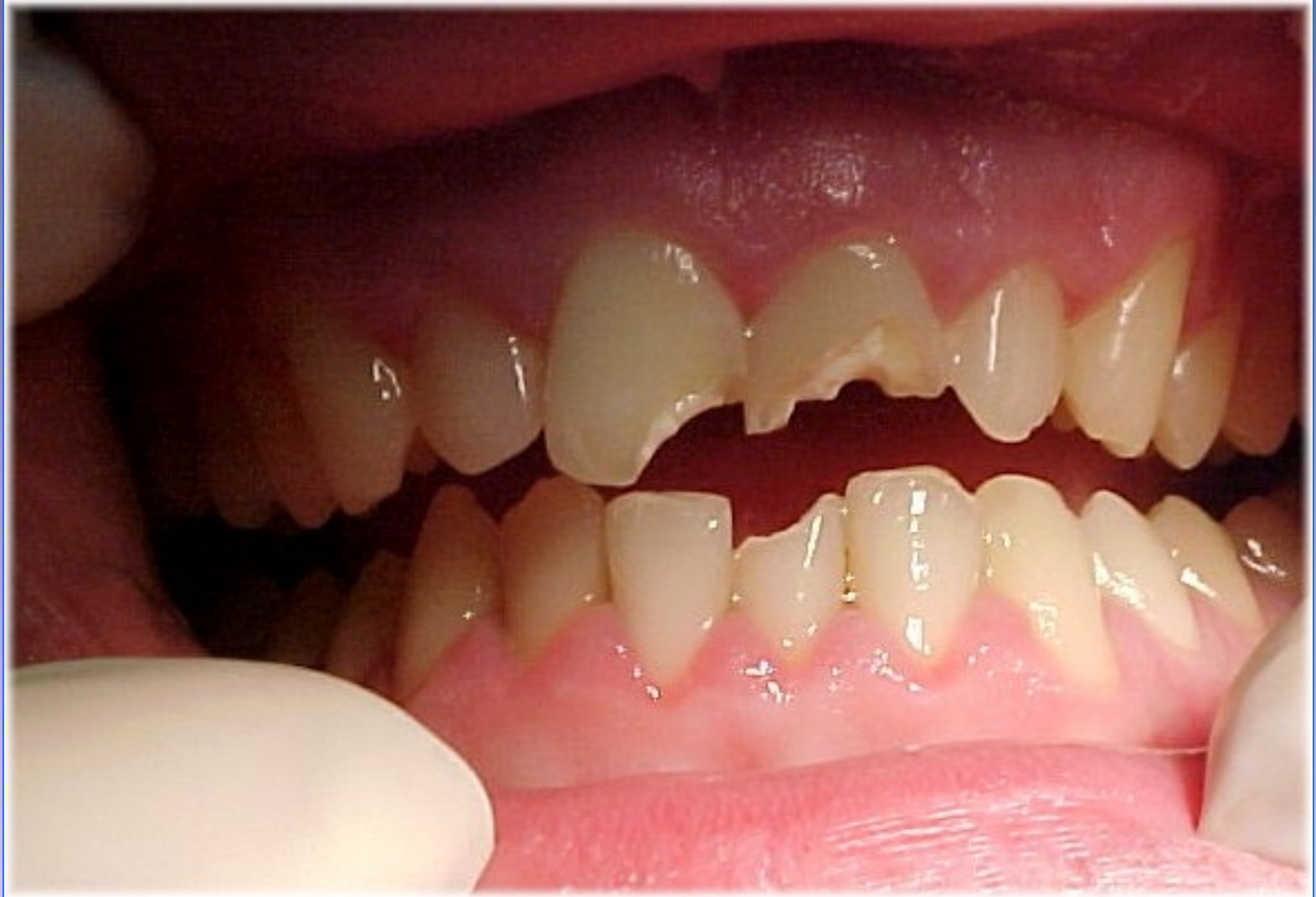


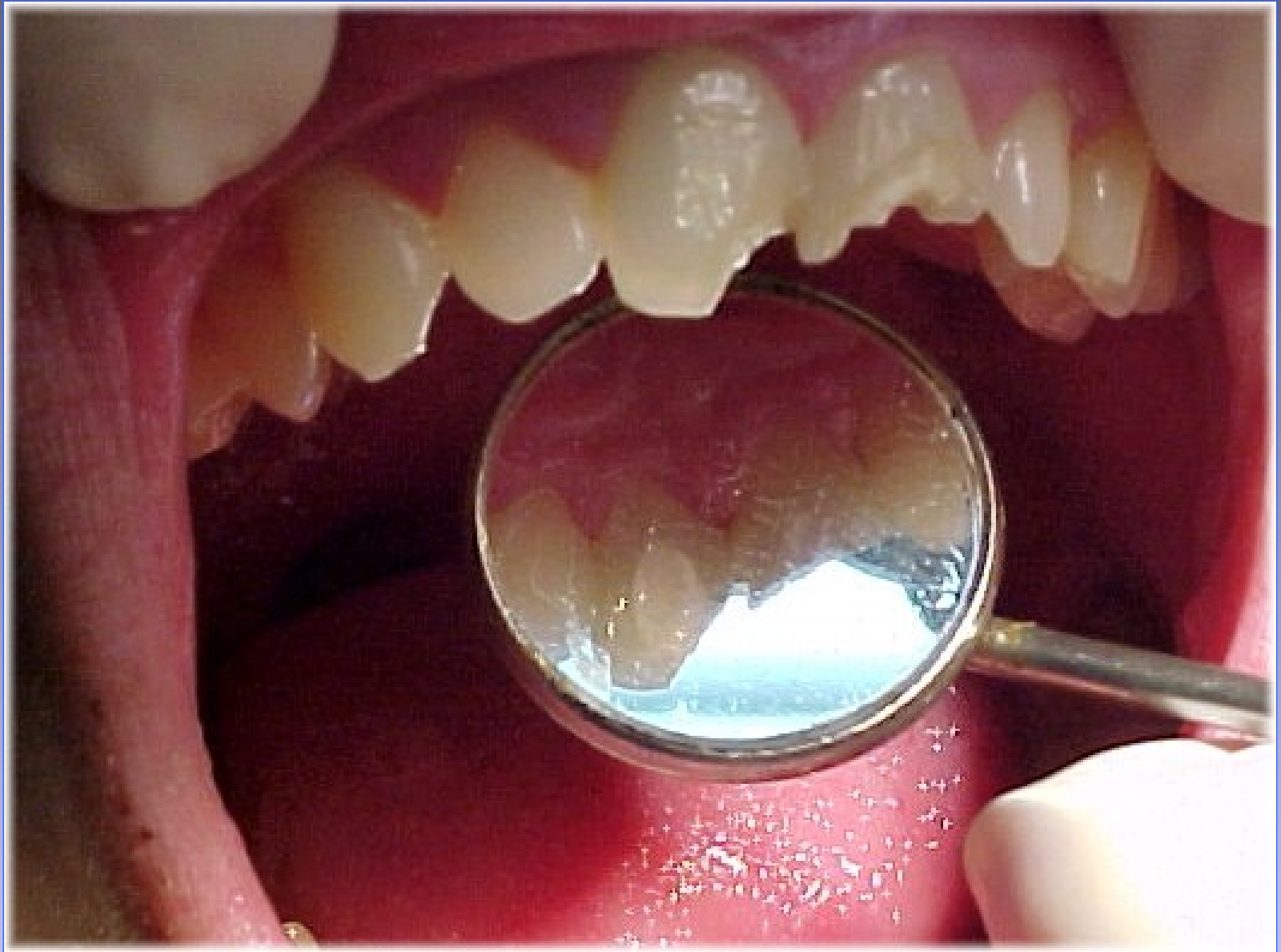


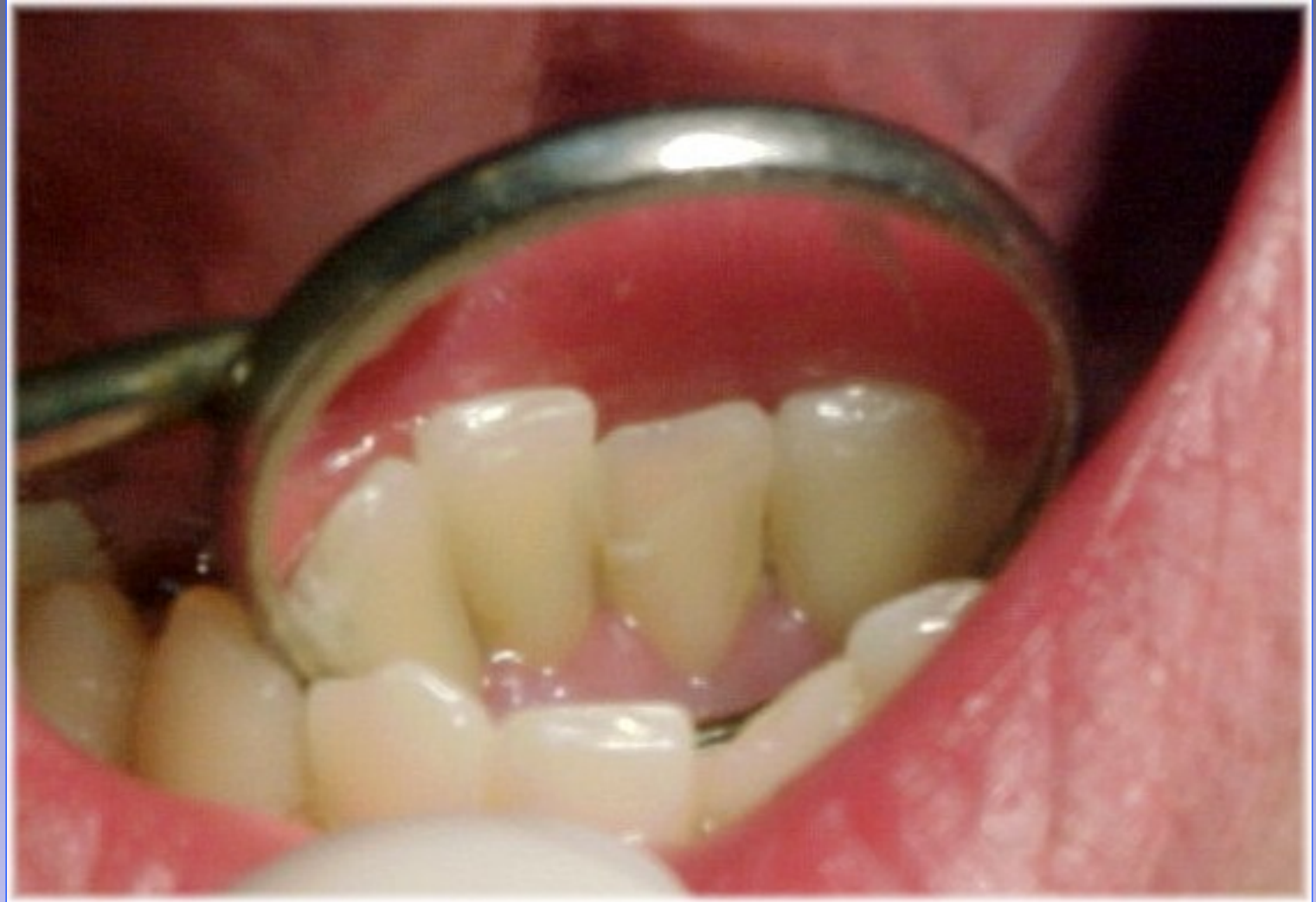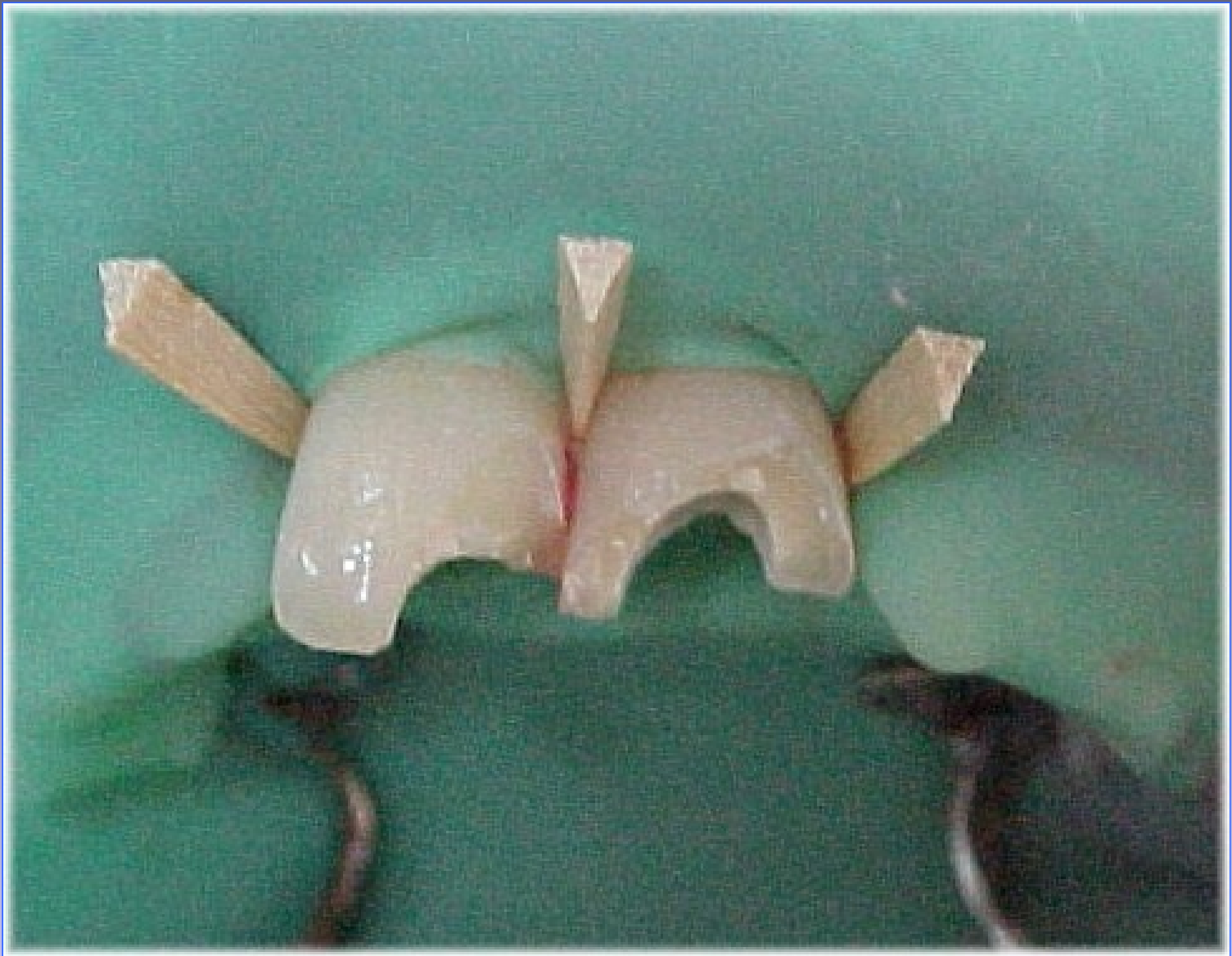


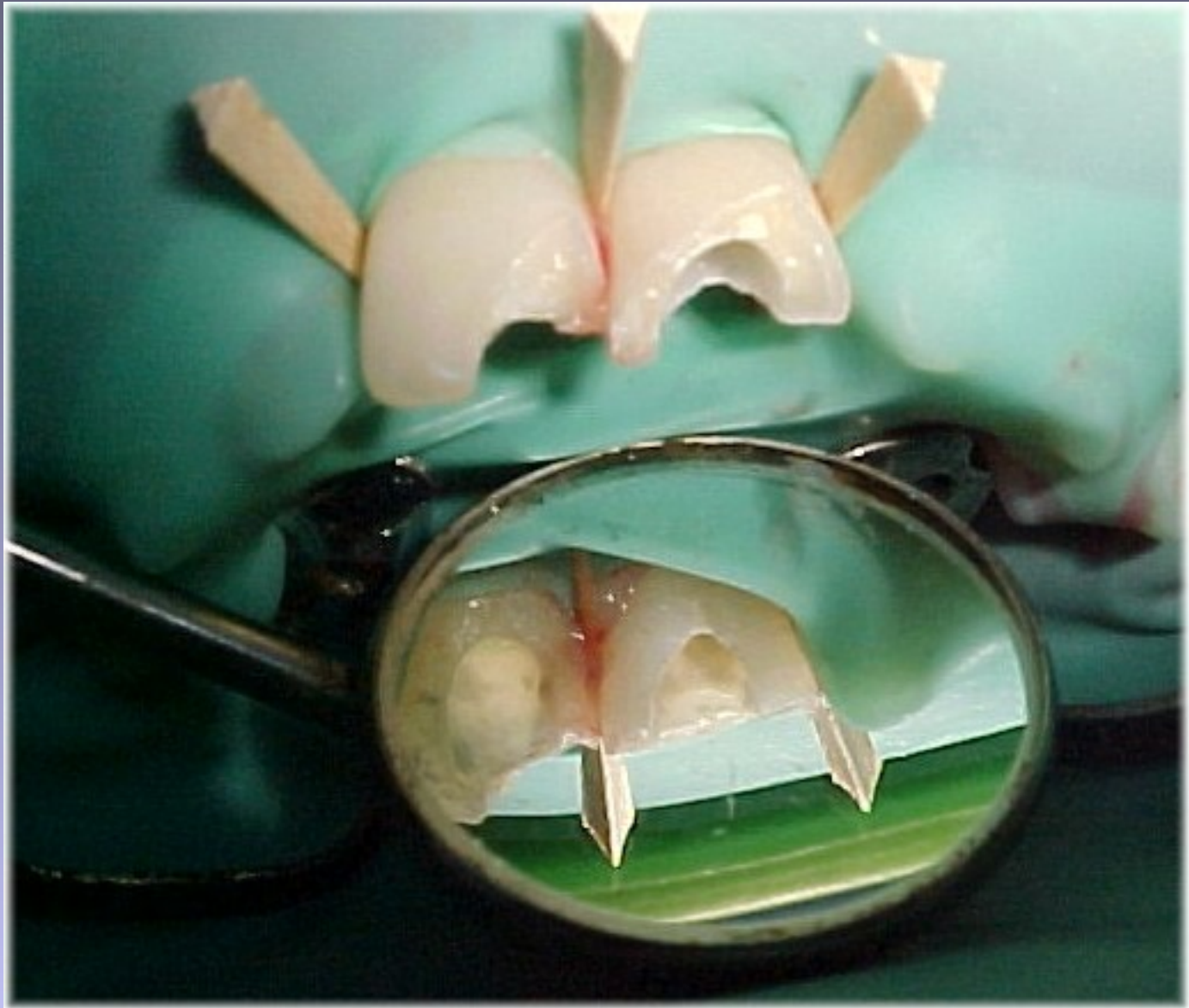
Fracturas Coronarias Múltiples.

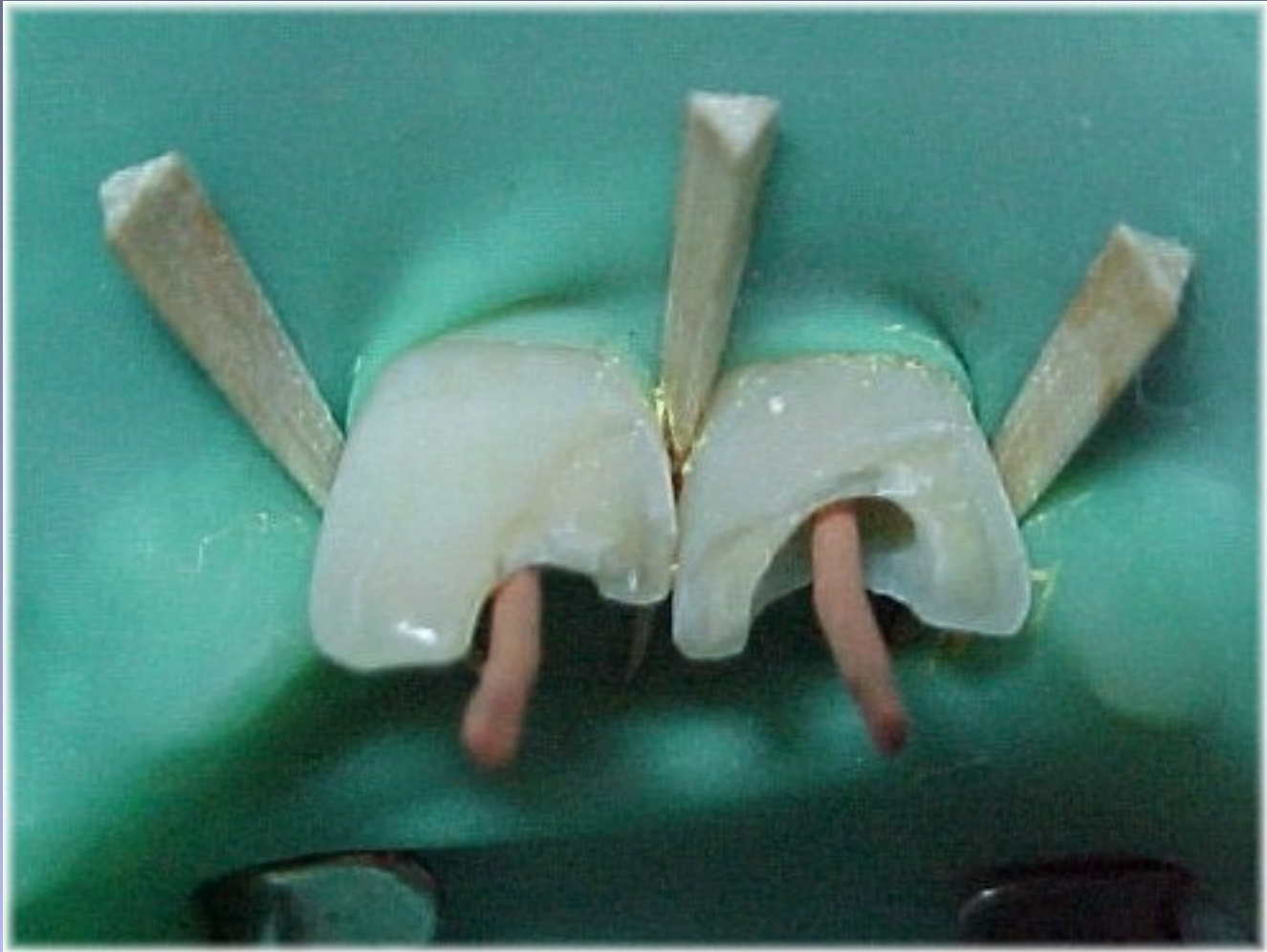


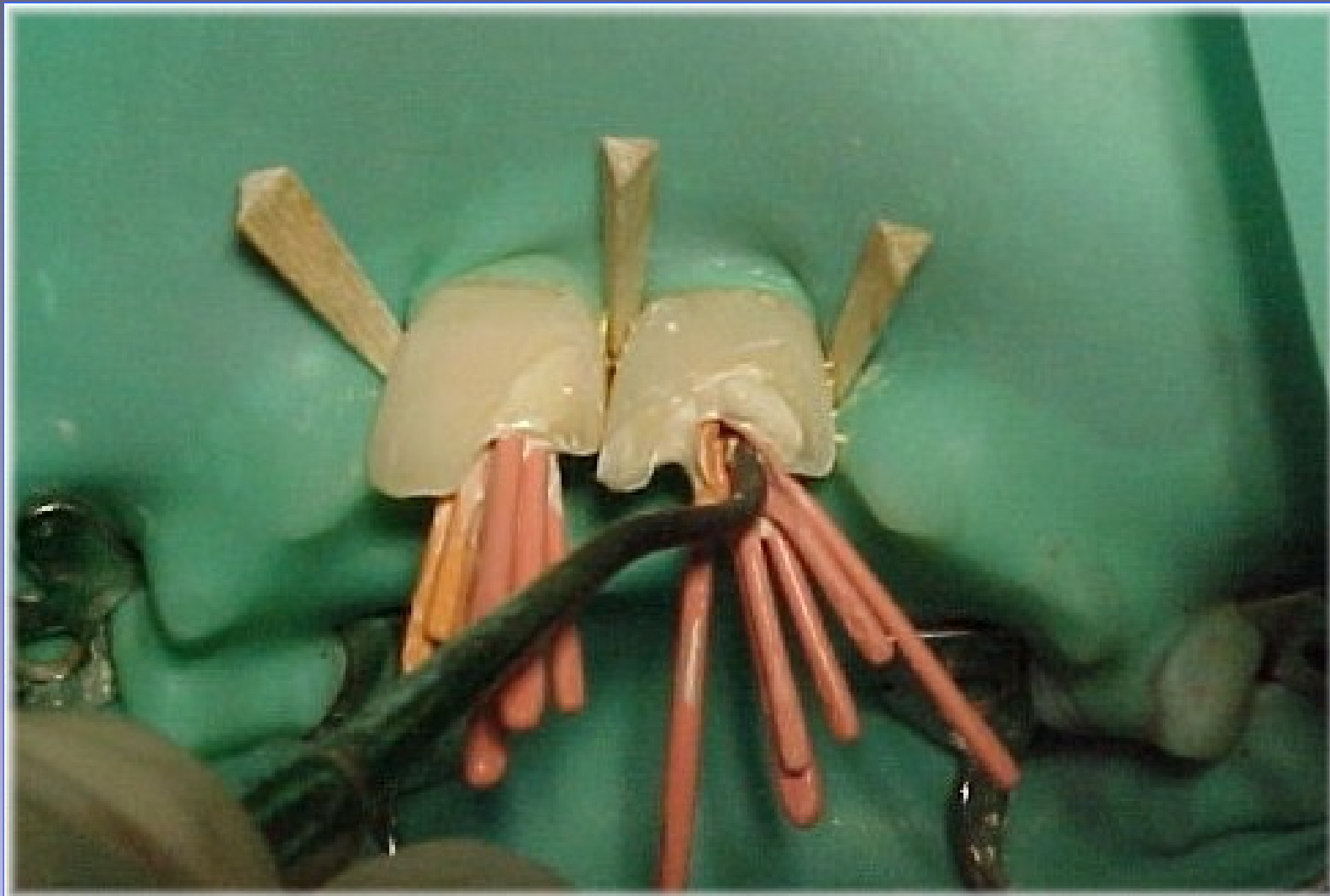


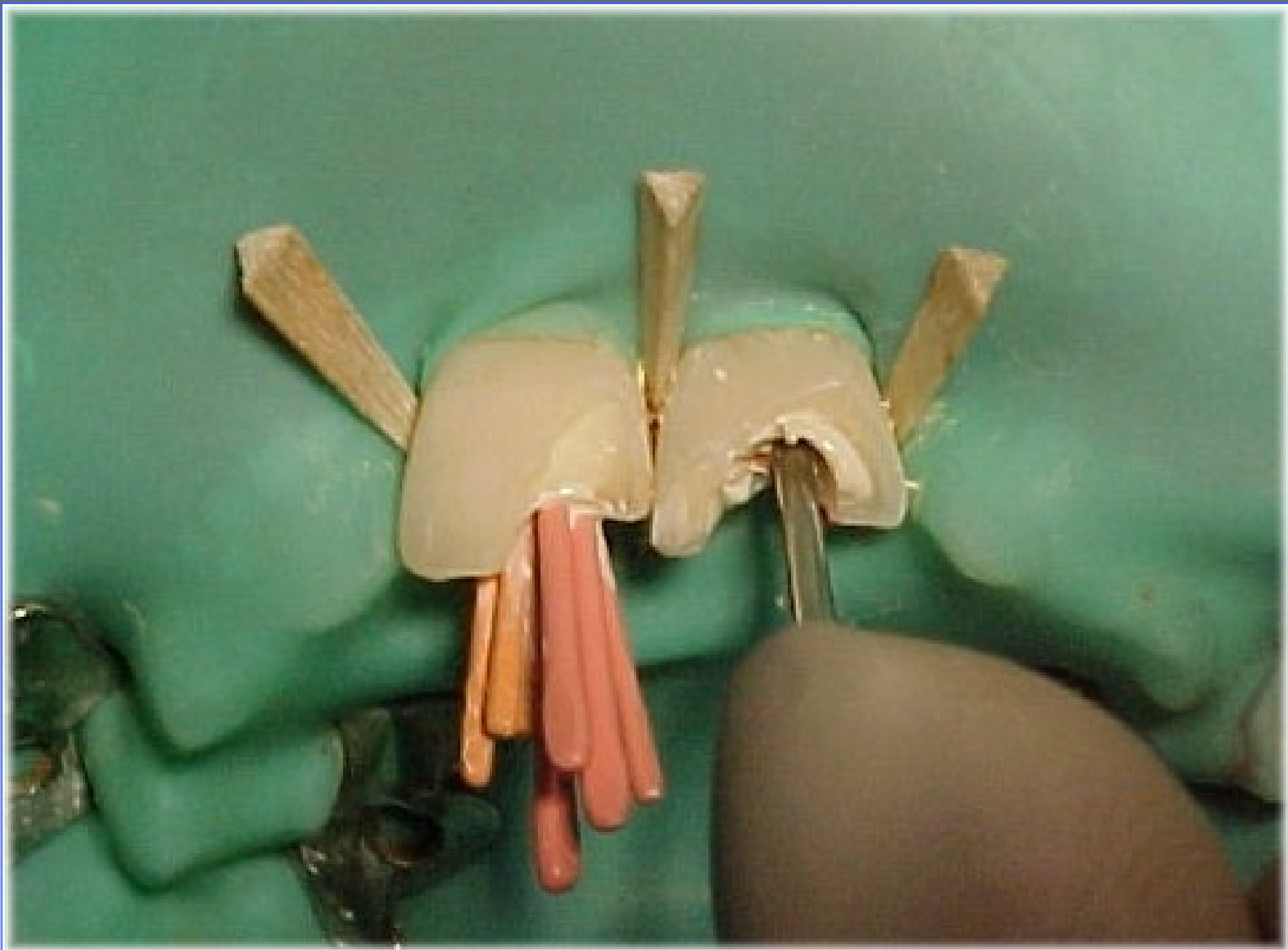


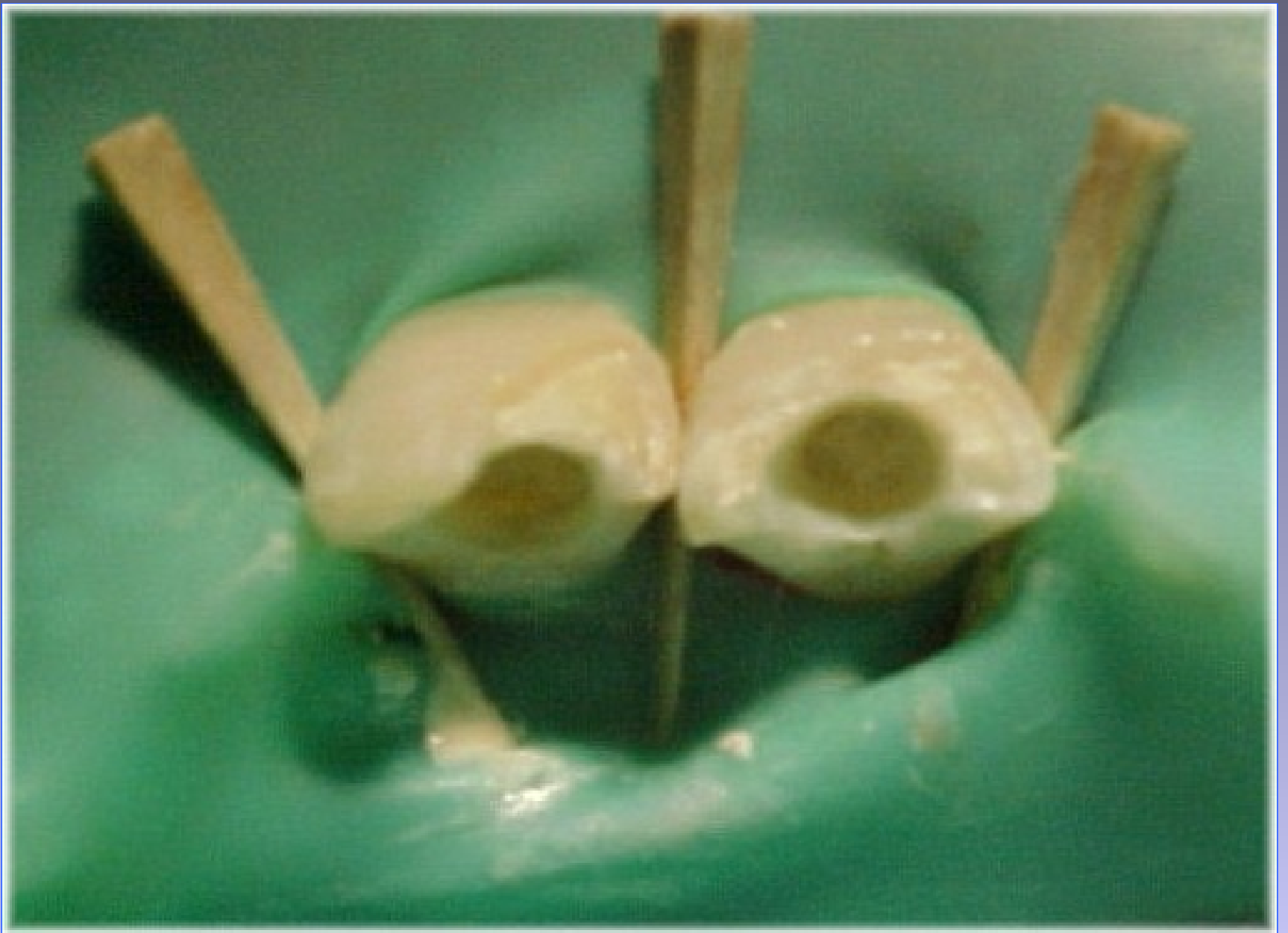


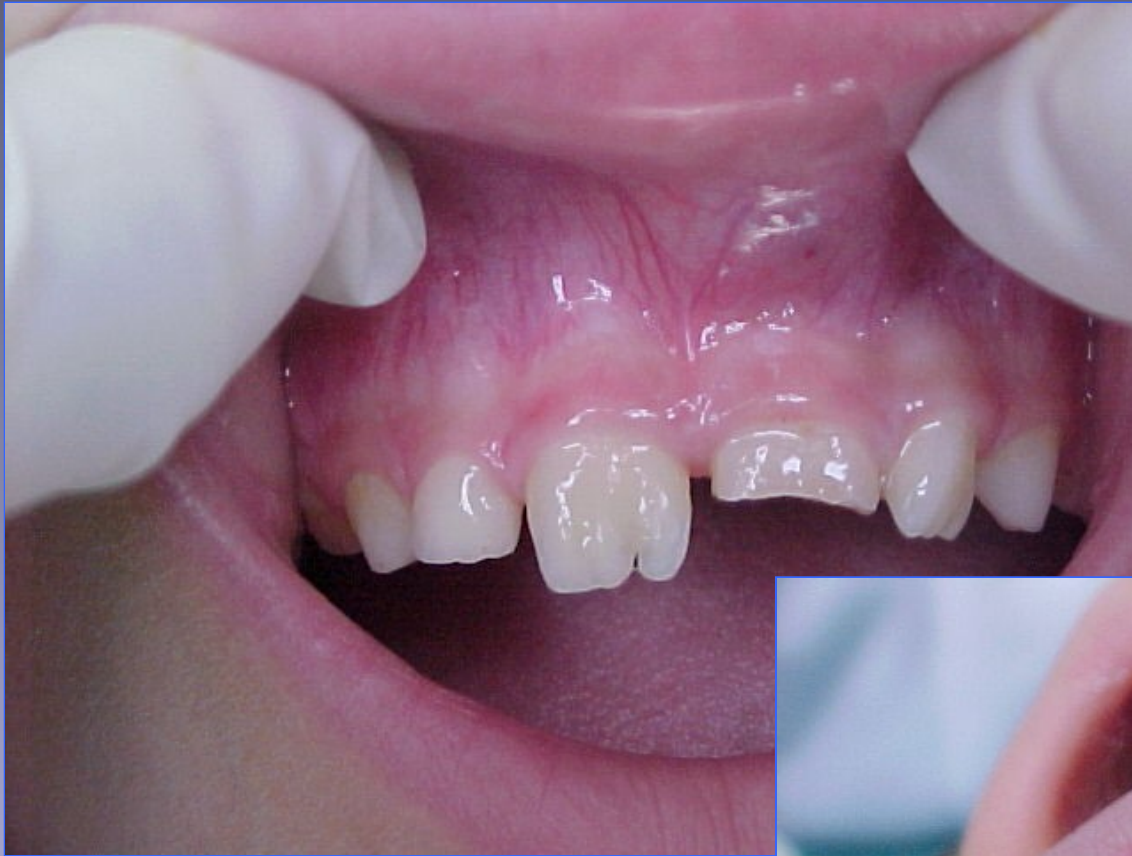




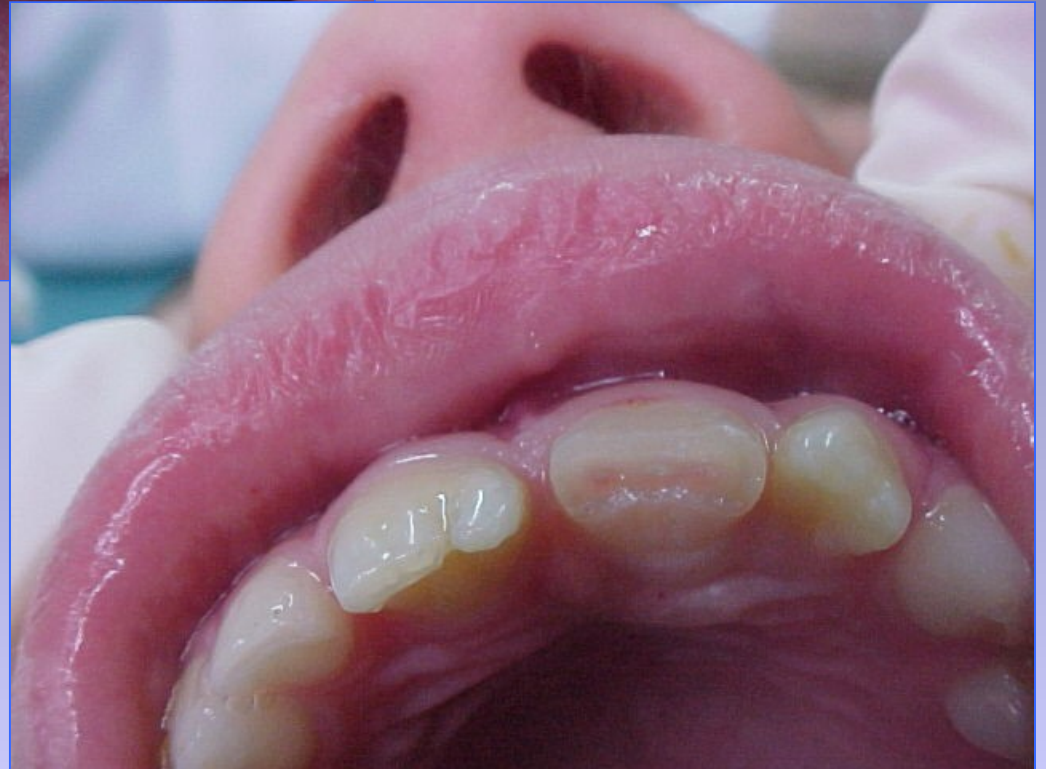
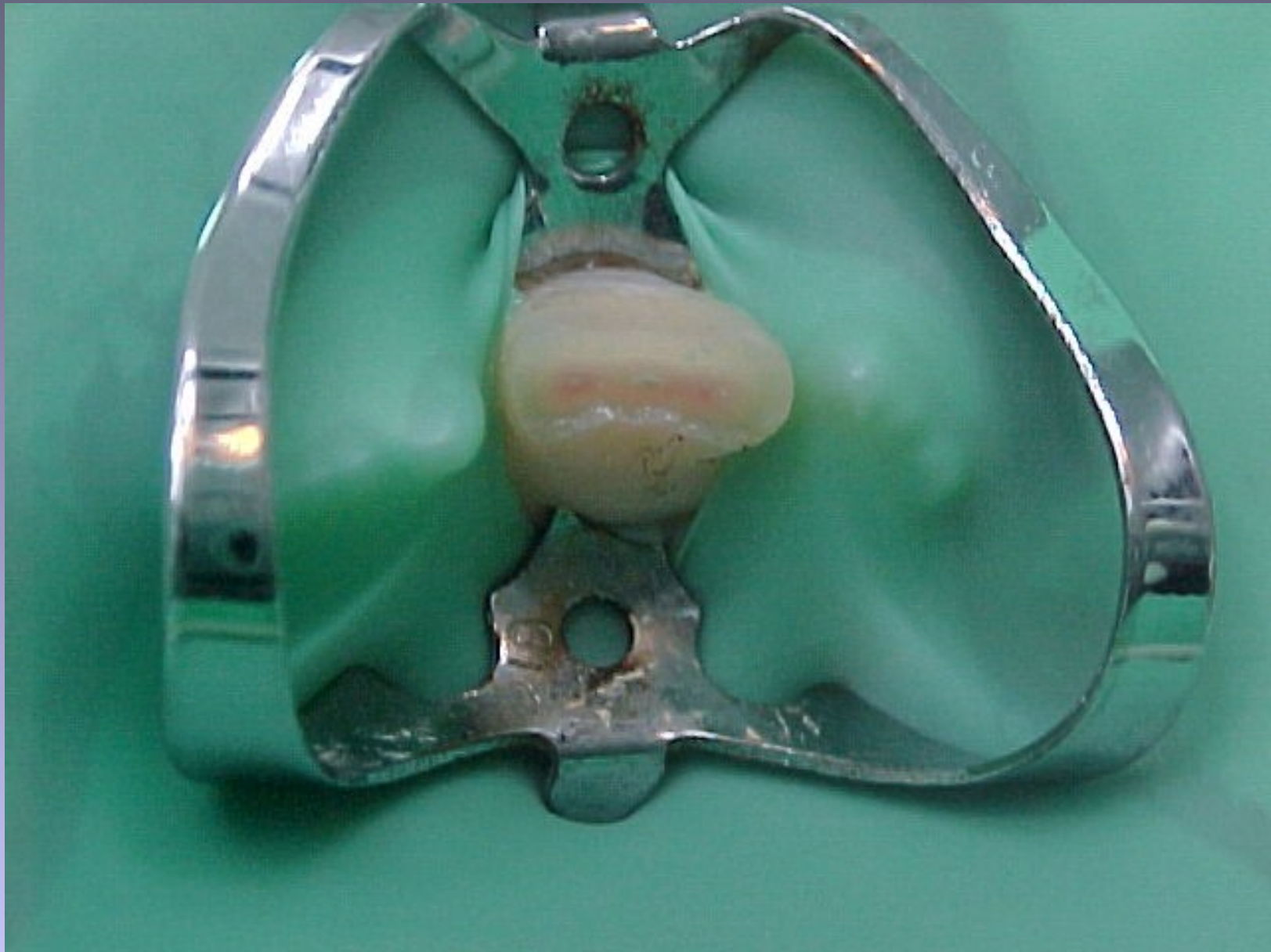


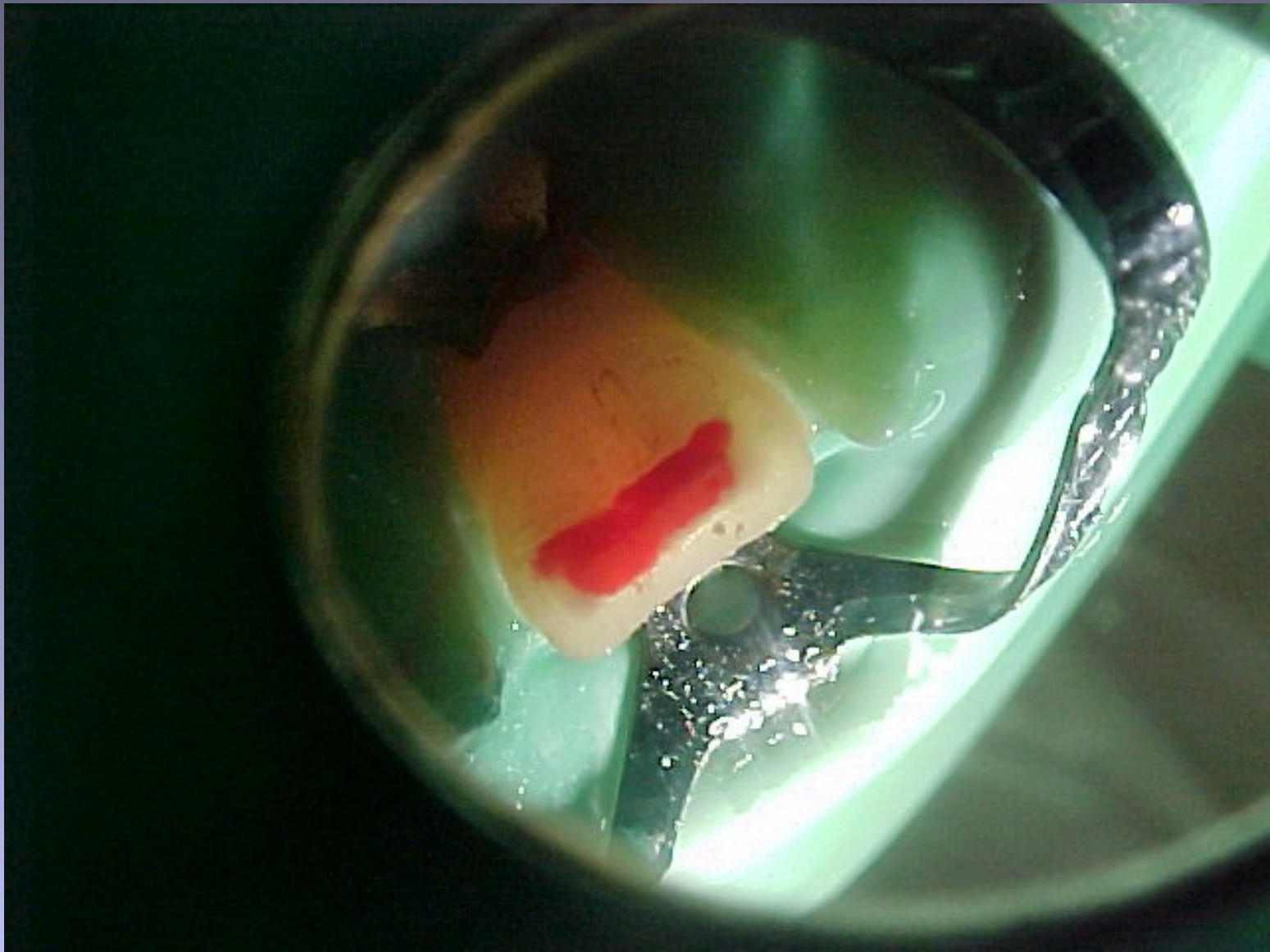




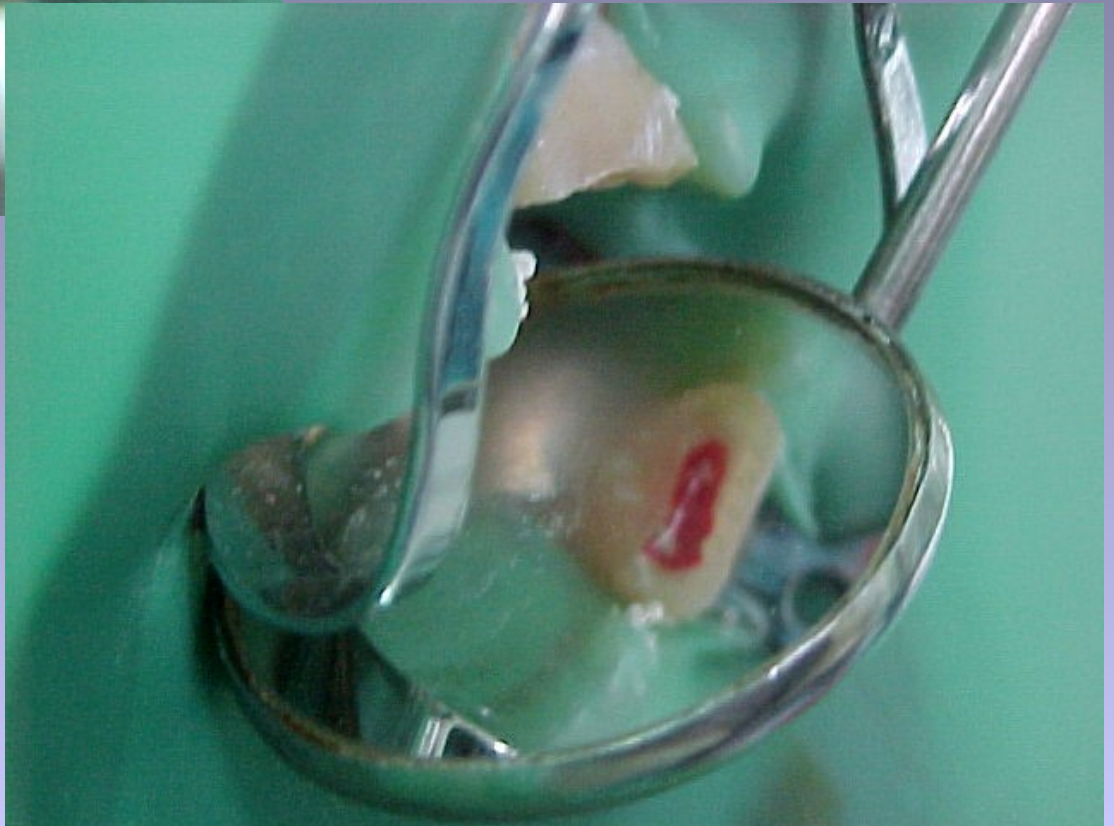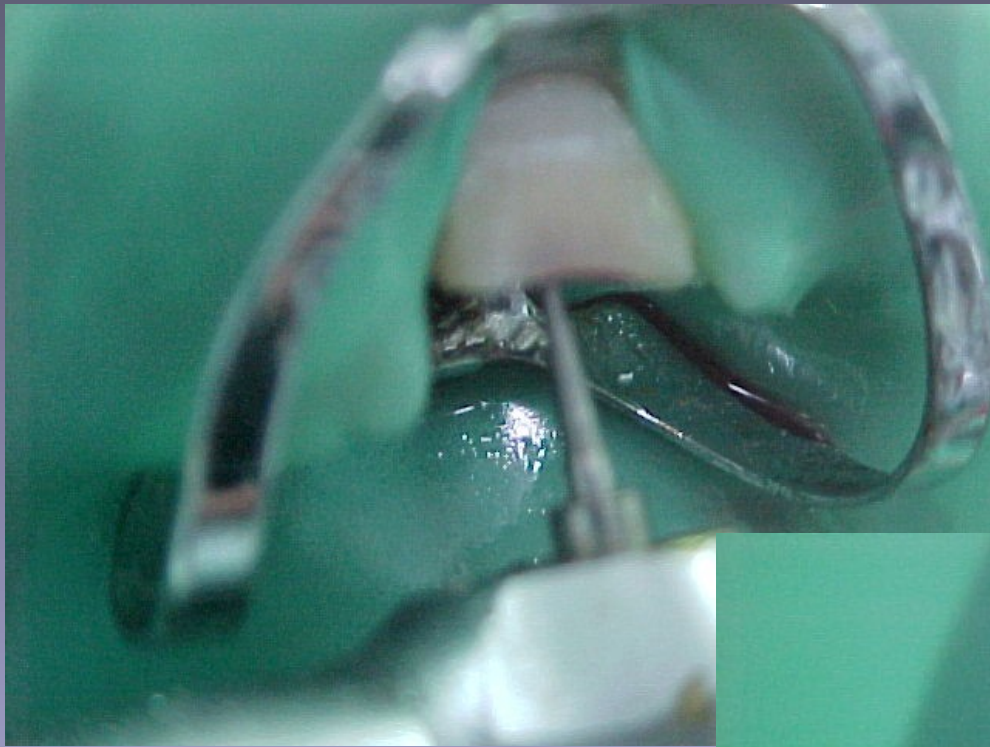**Fractura coronaria
con exposición pulpar**



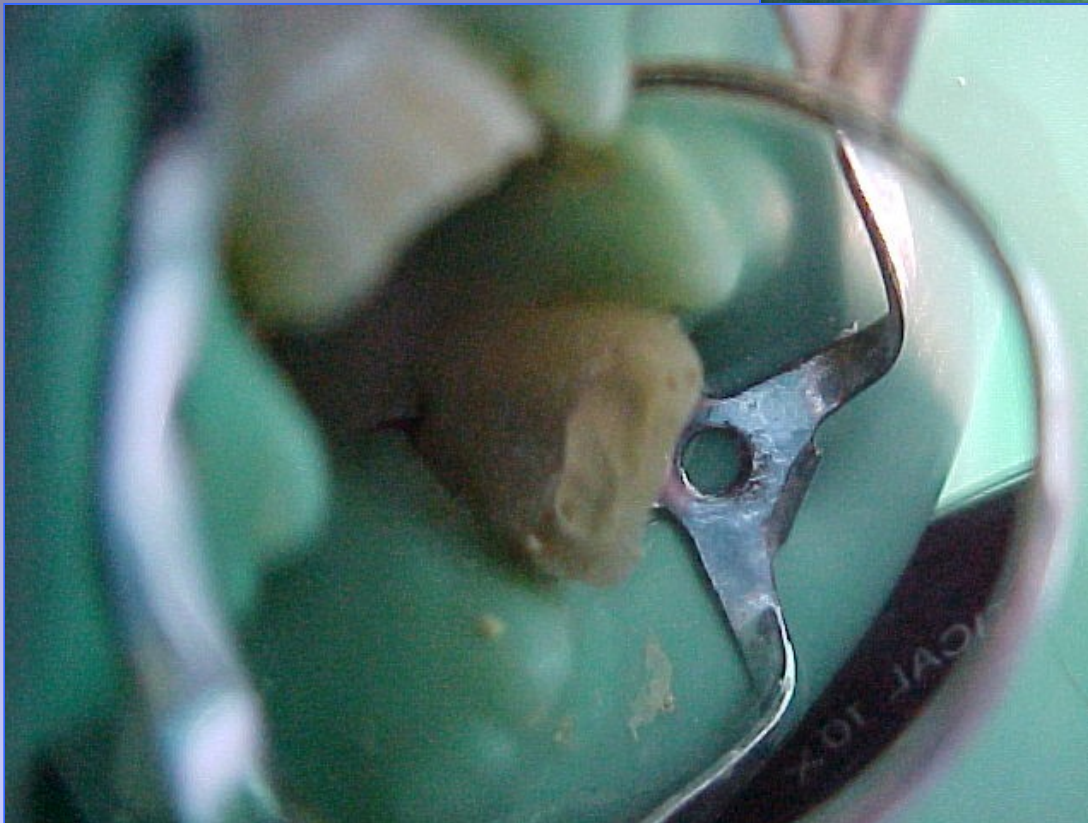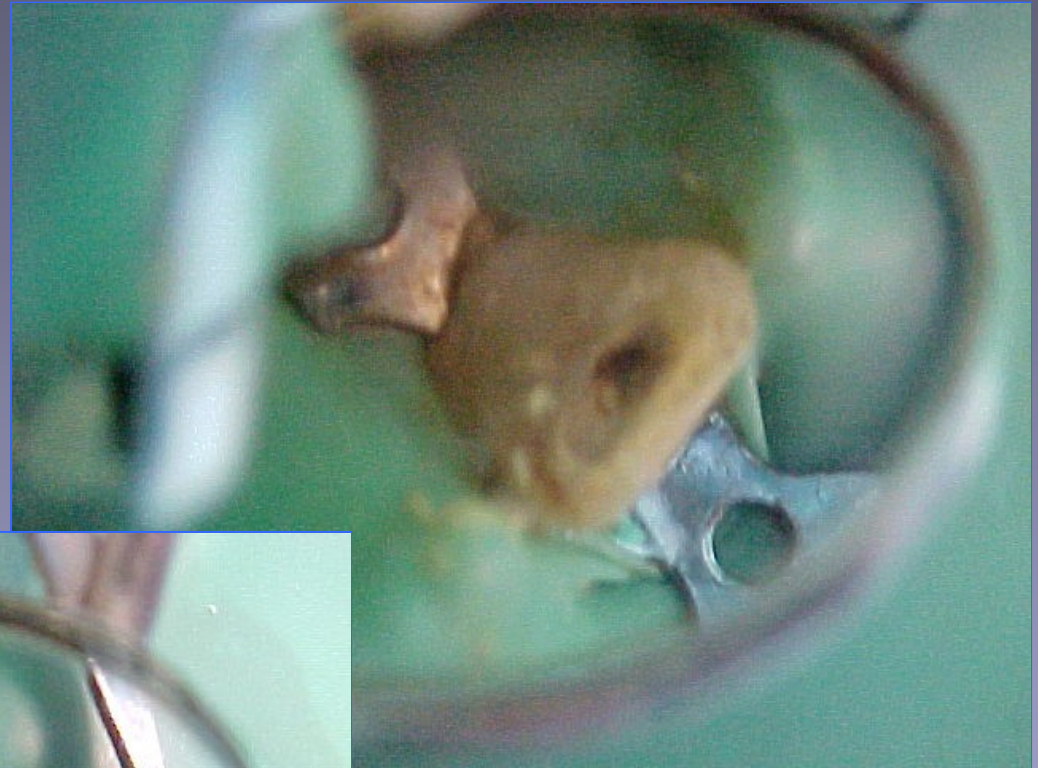




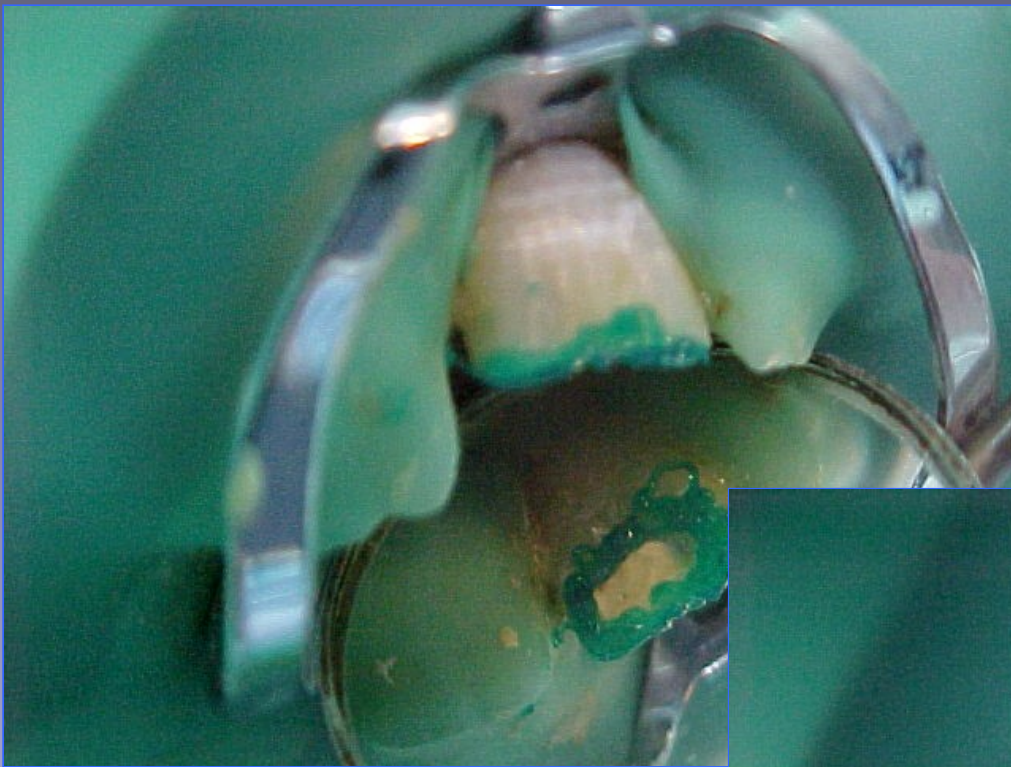


**Corte Pulpar superficial
a nivel de techo cameral.**

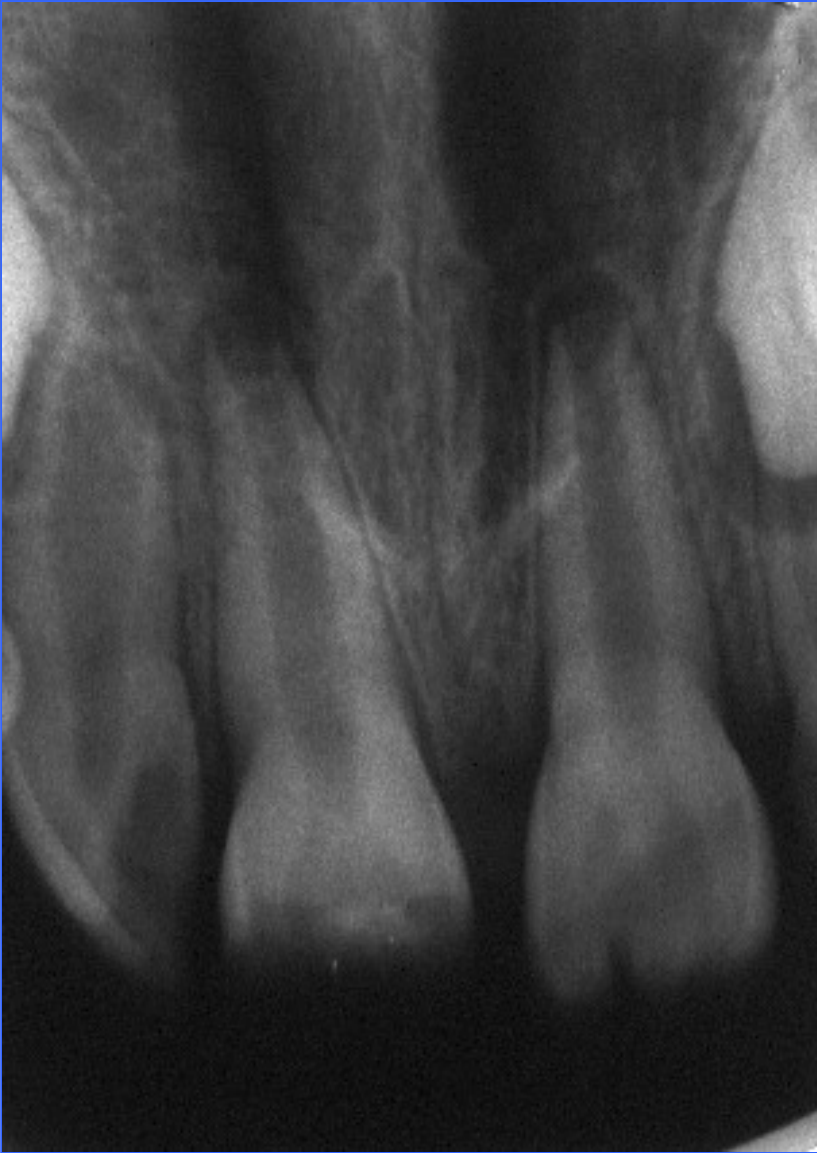
Recubrimiento pulpar
con hidróxido de Ca.



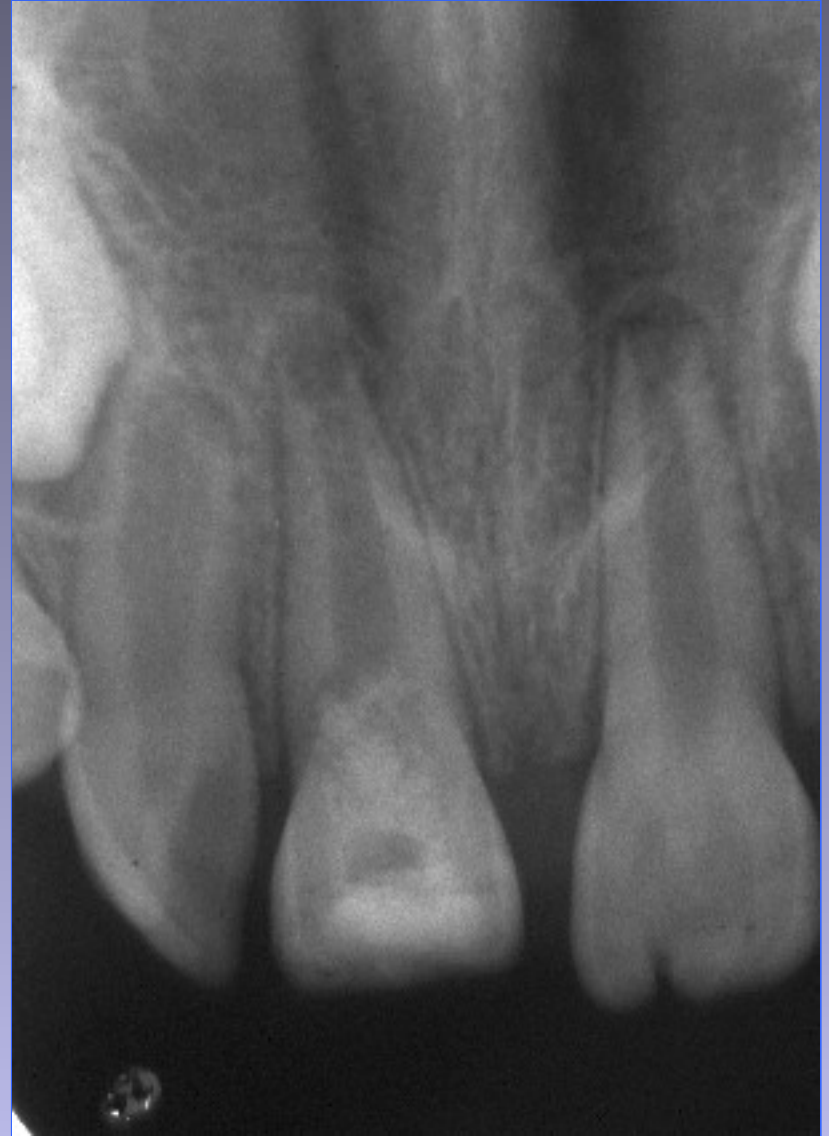Protección y aislamiento
de la herida.



**Reconstrucción
Estética-funcional-**



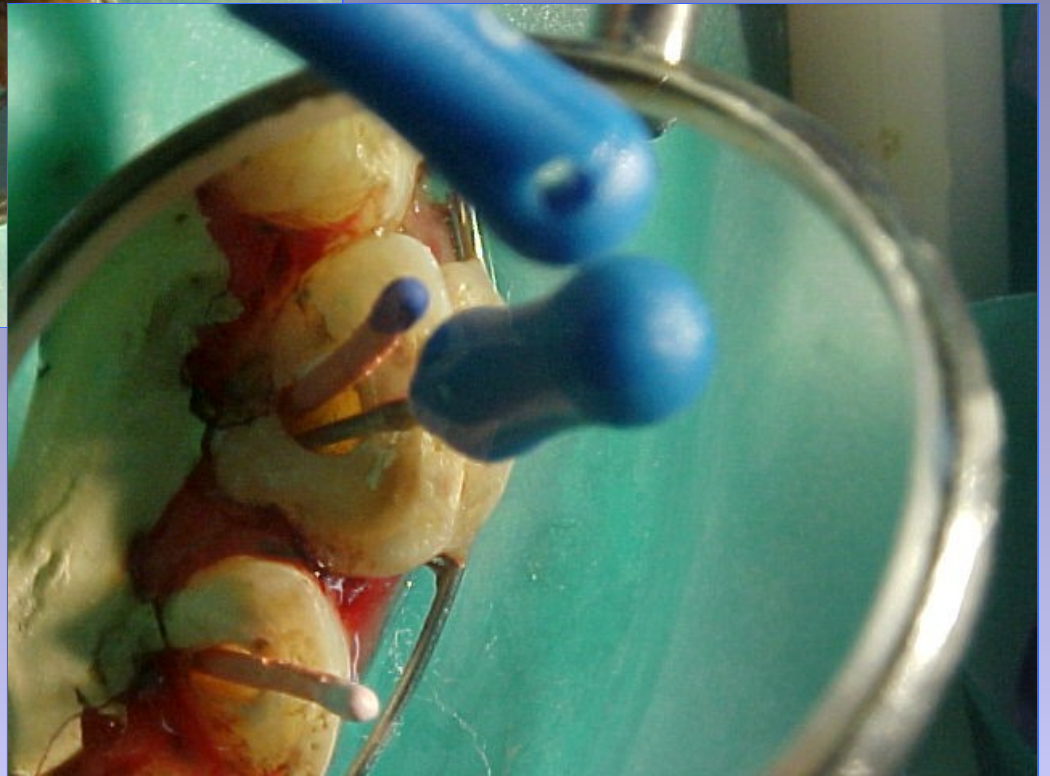
Rx pre operatoria

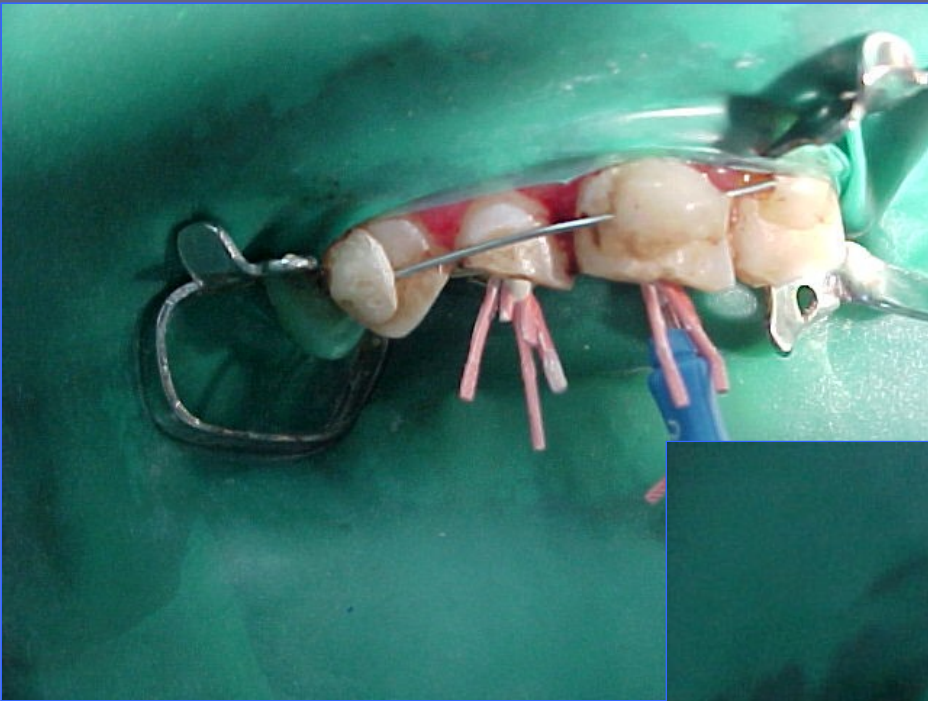


Rx post operatoria

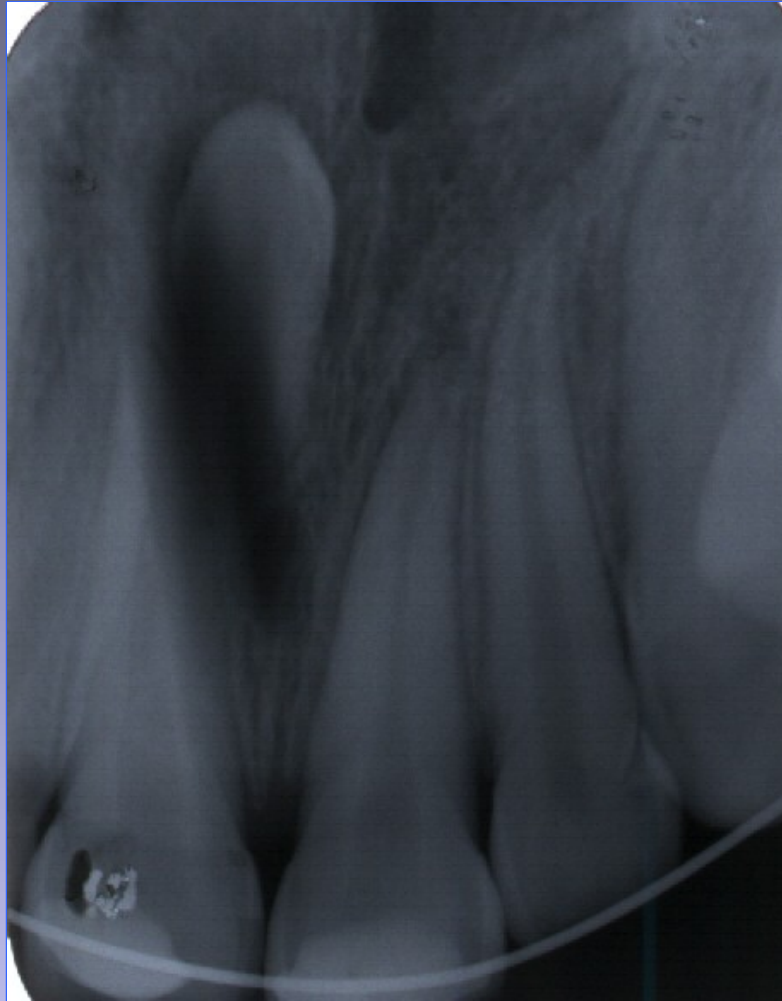

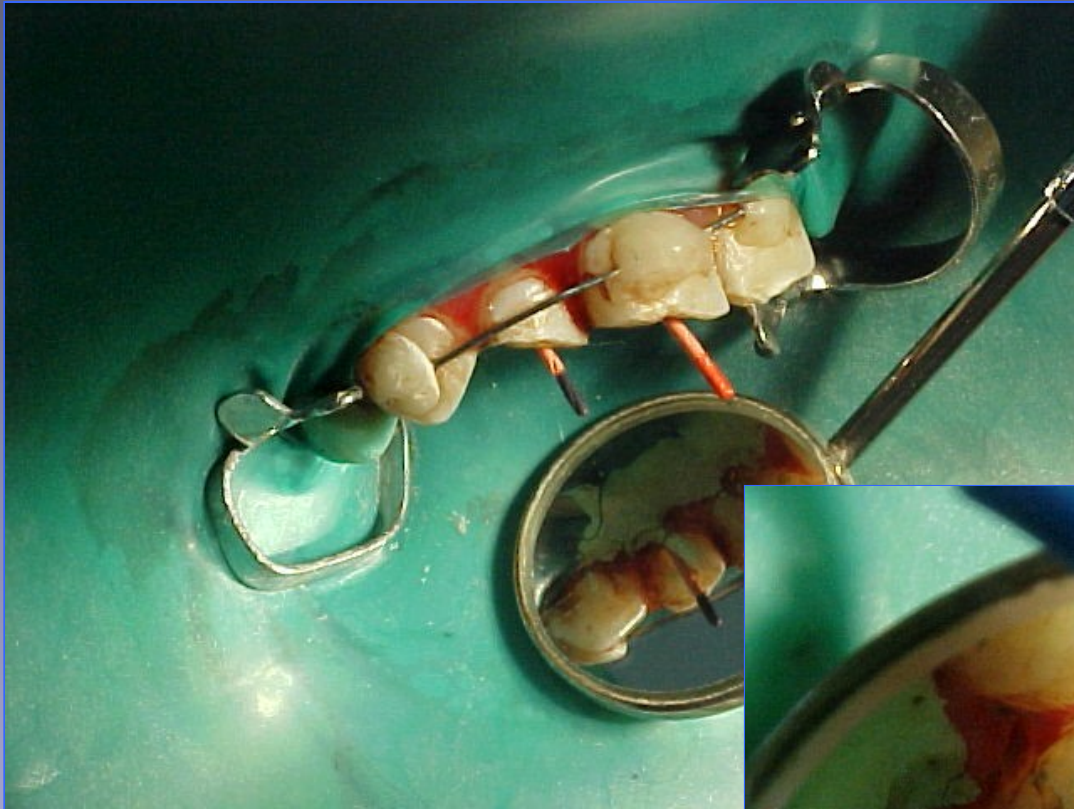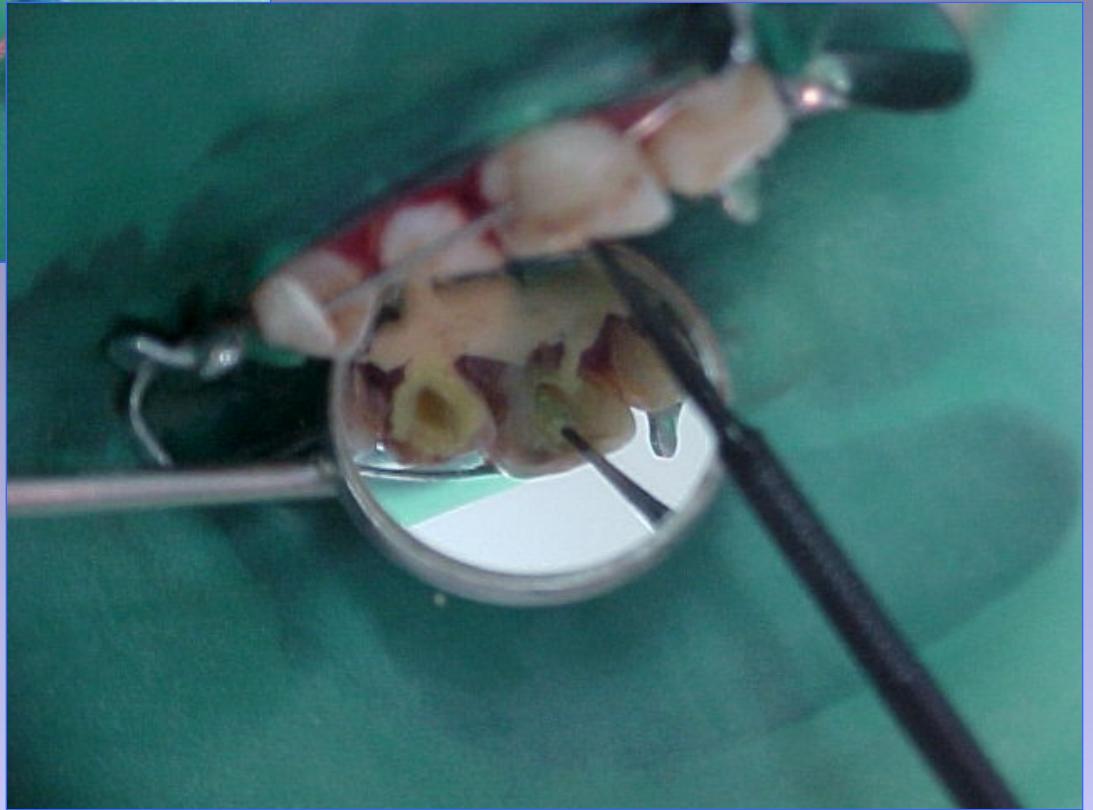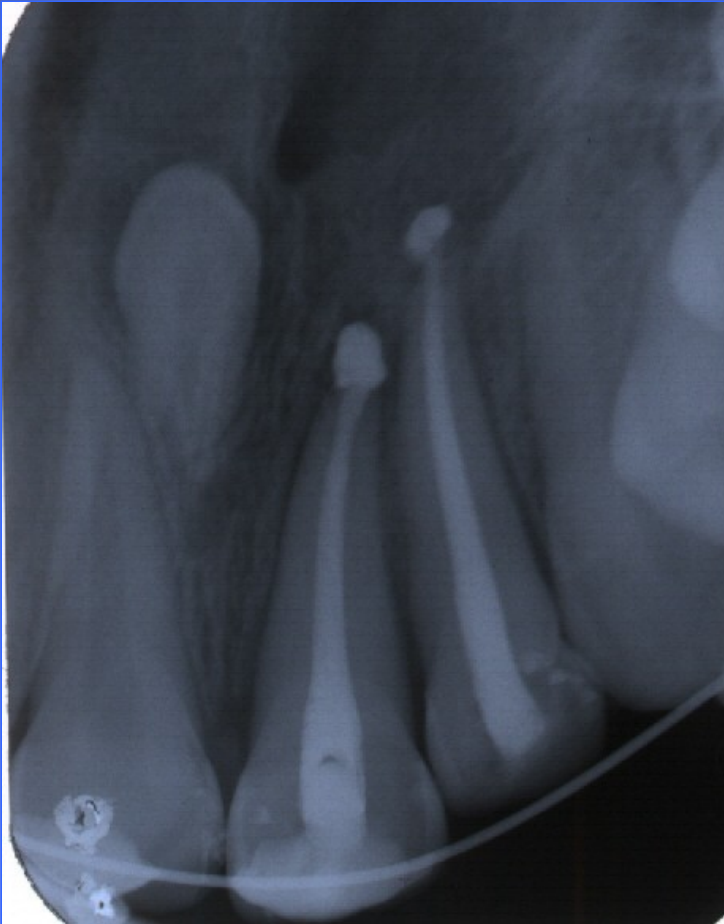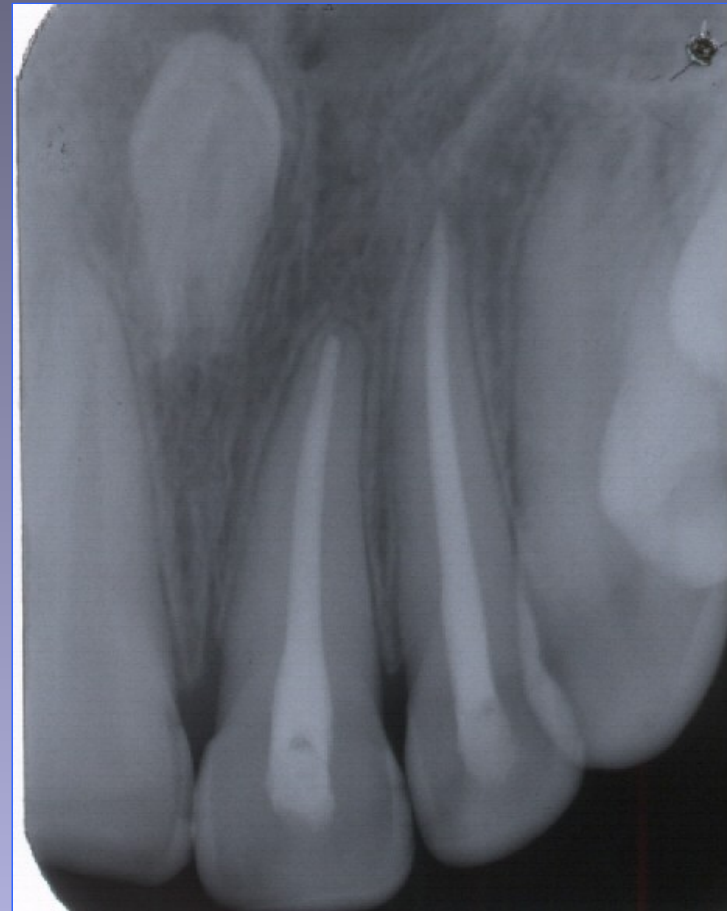
Imagen pre operatoria.







**Post operatorio
inmediato.**



Control a 1 año

Fracturas Radiculares

Fractura Tercio Apical

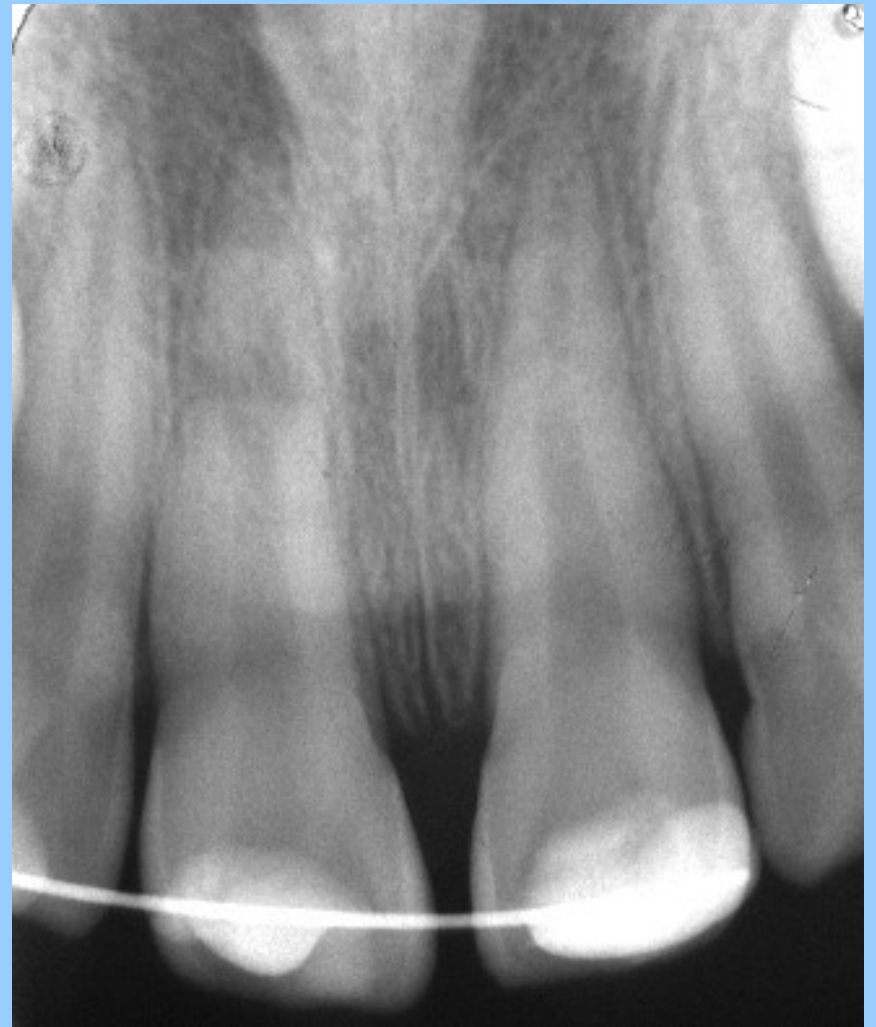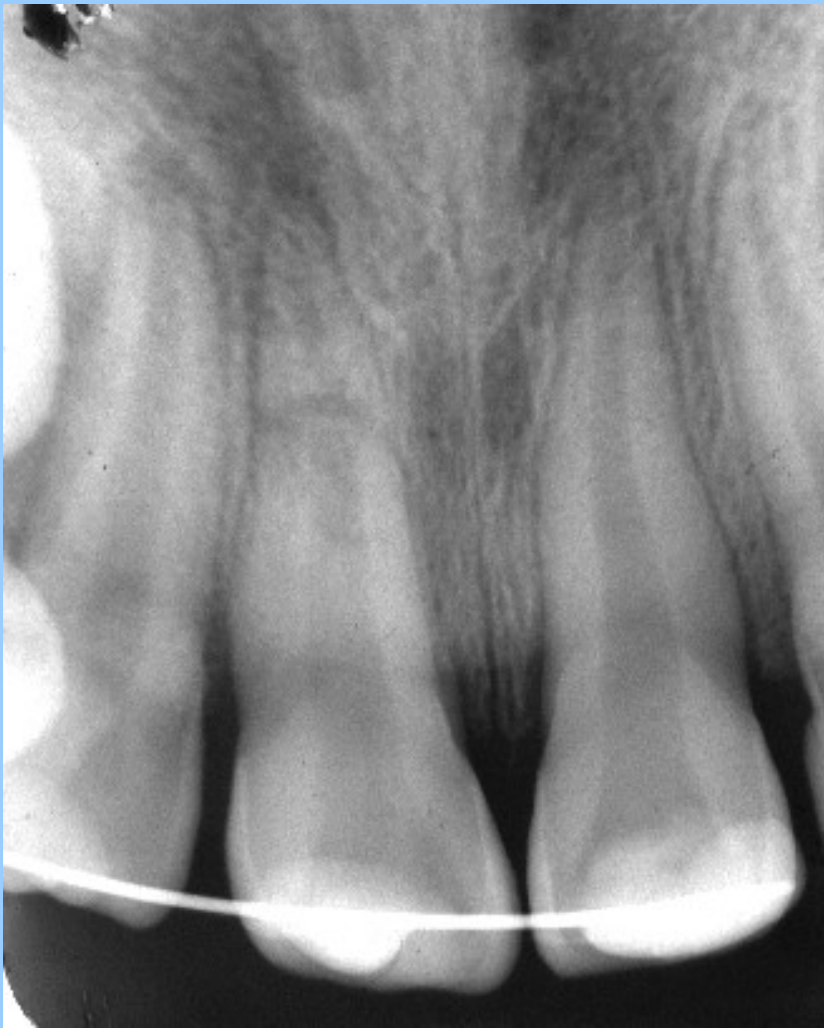Paciente varón de 11 años , se presenta a la consulta, manifestando haber recibido un cabezazo, con luxación hacia palatino de los dos ICS.

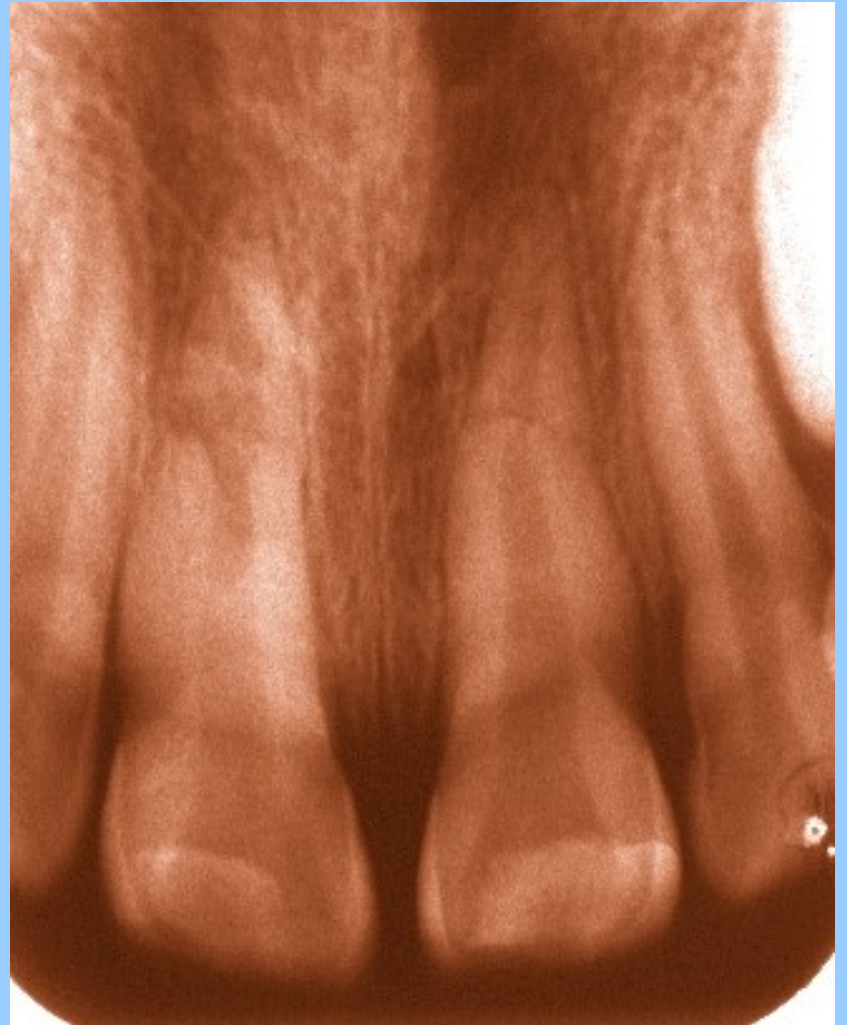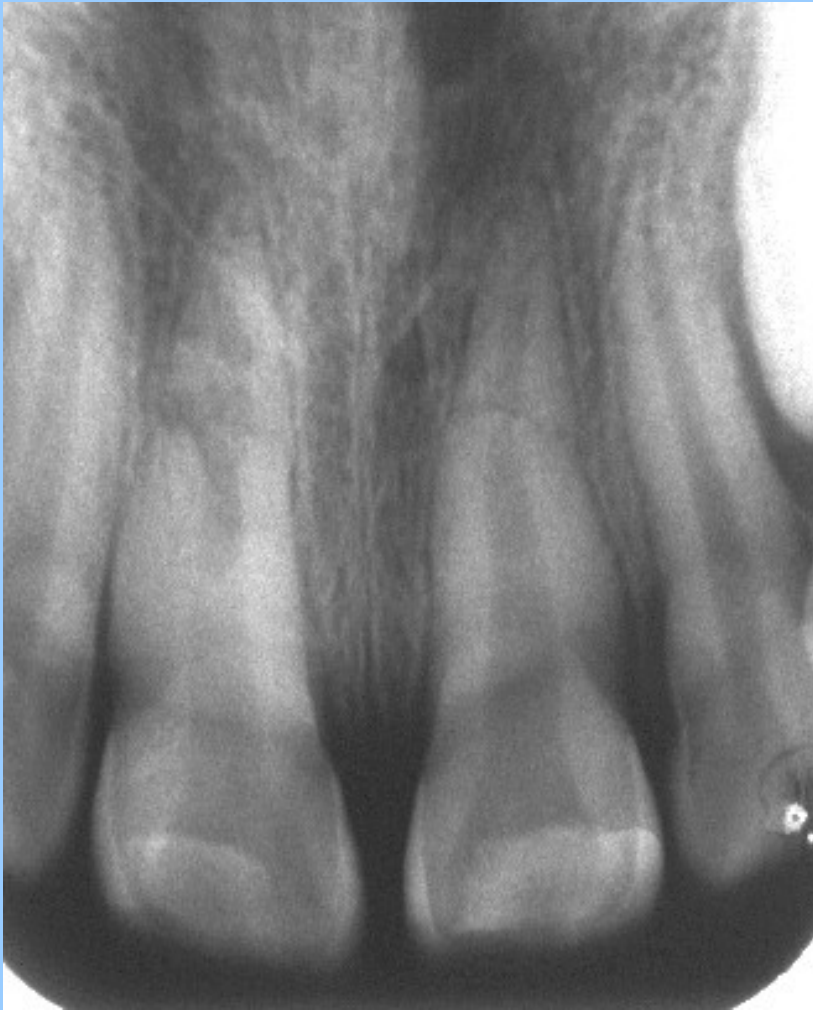El mismo se los reposiciona y concurre al Servicio de Diagnóstico , donde le realizan una férula.

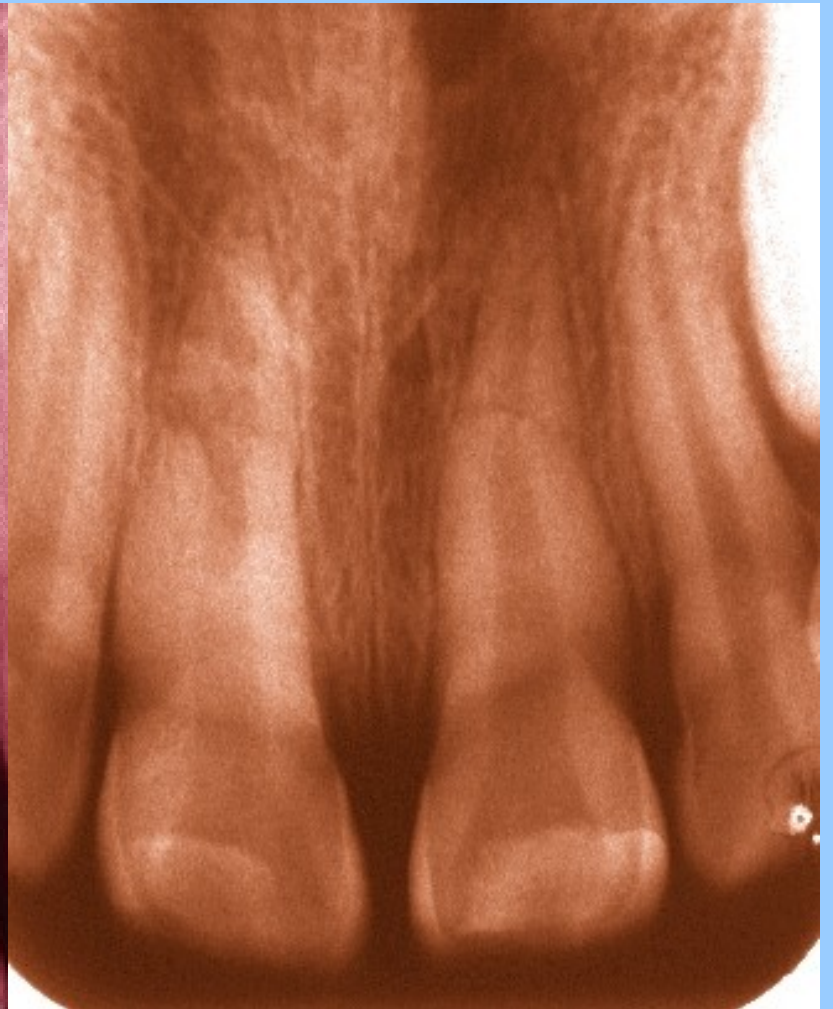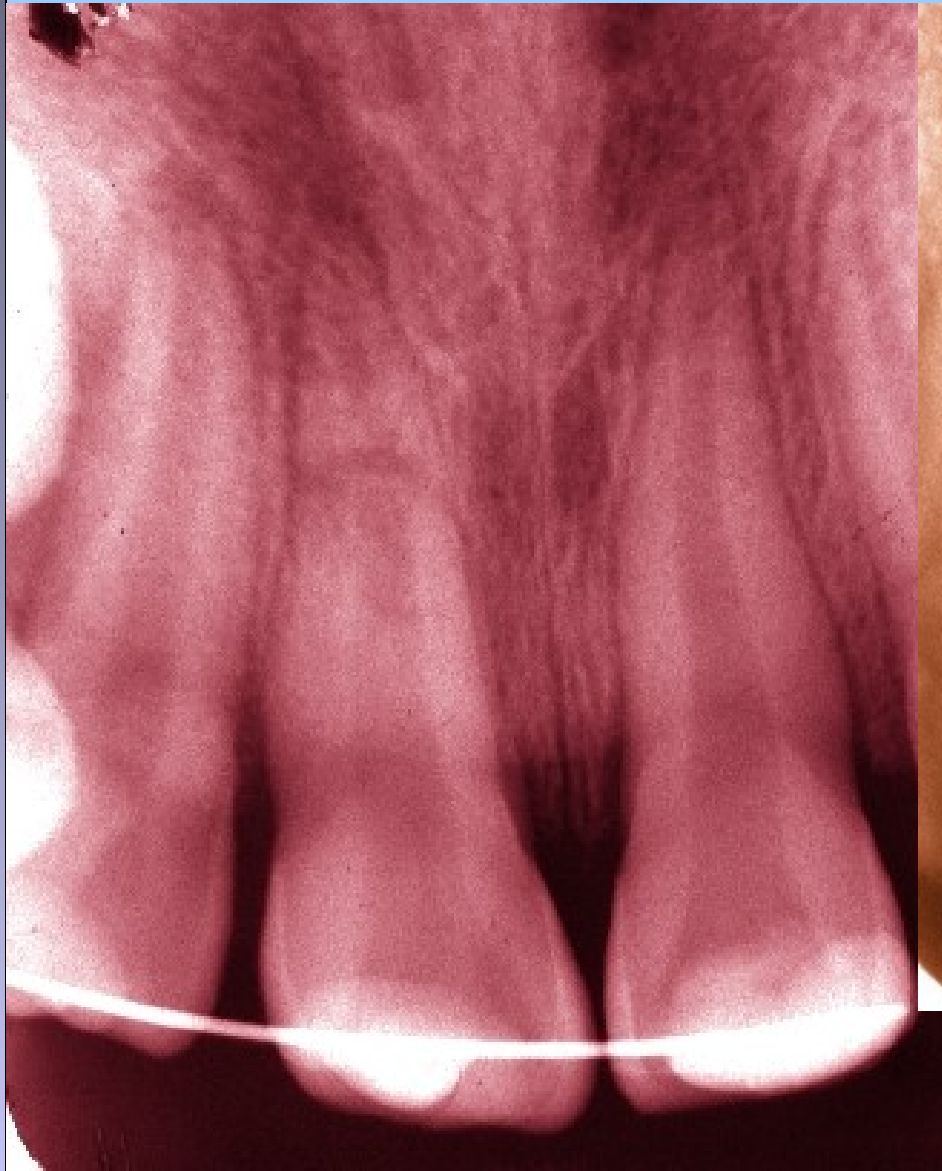
Se realiza el monitoreo pulpar y se la cita al mes.

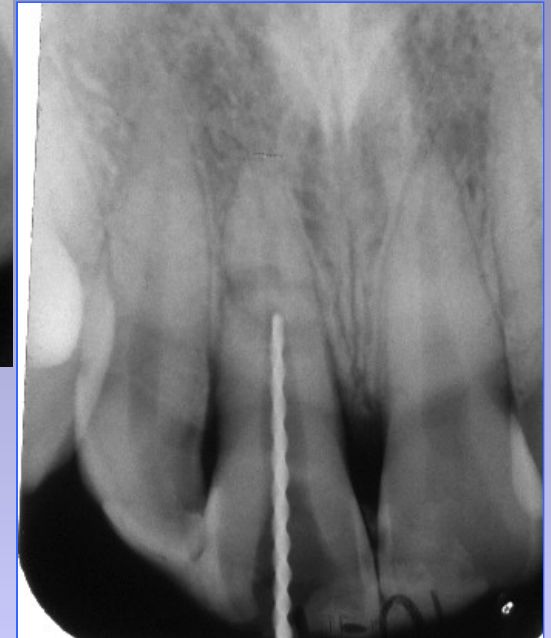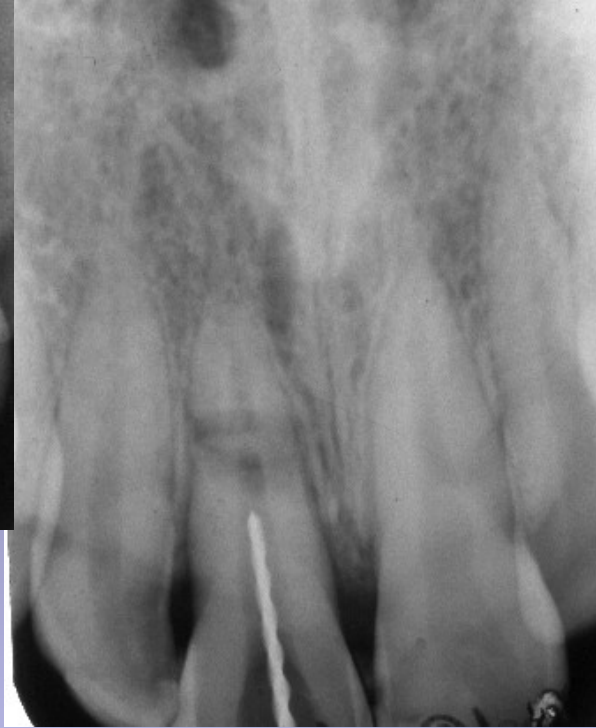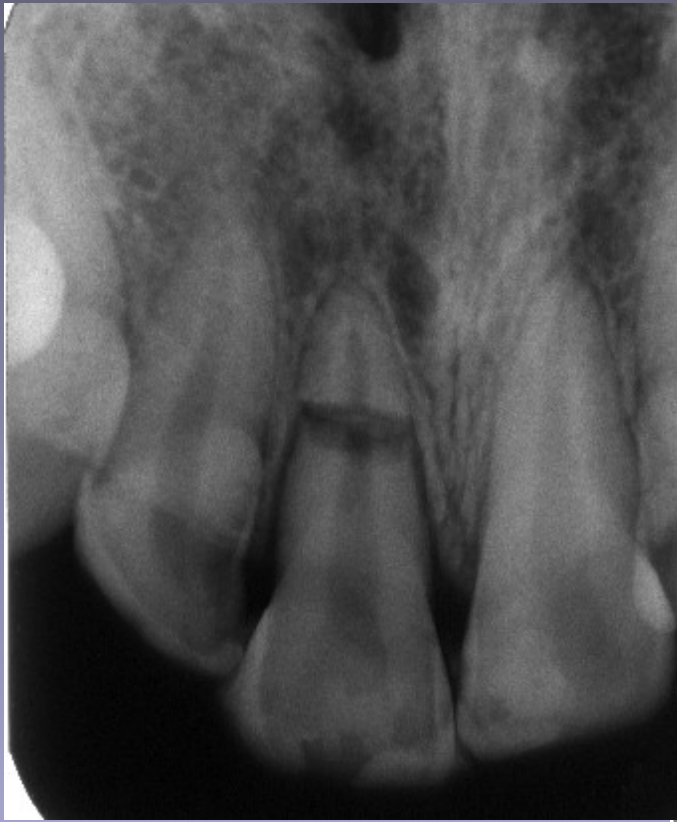El paciente retorna seis meses después, todavía con la férula colocada.

Se hacen controles clínicos con buen estado de salud ,se toman radiografías y se retira la férula.



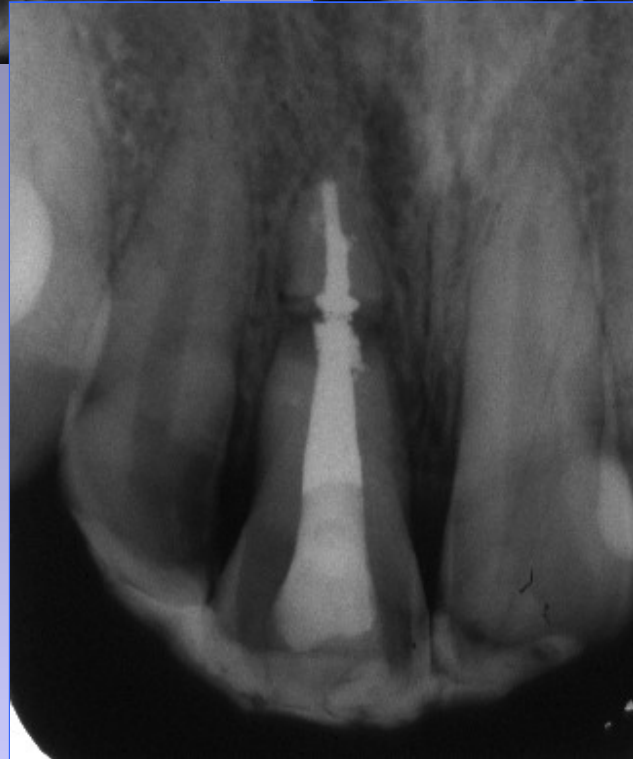
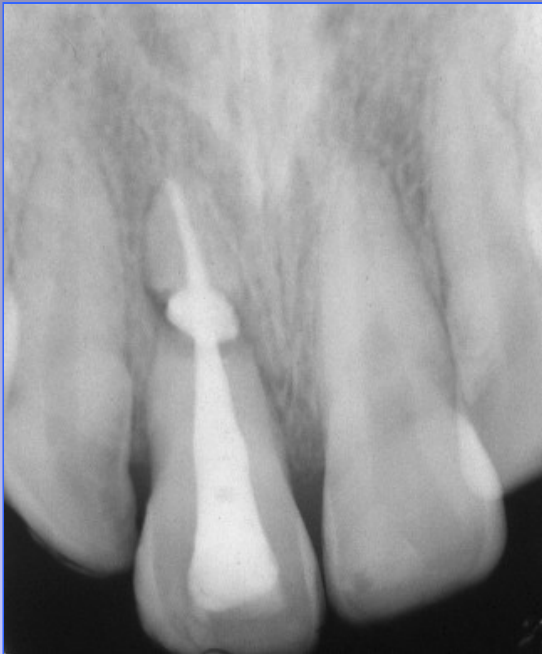
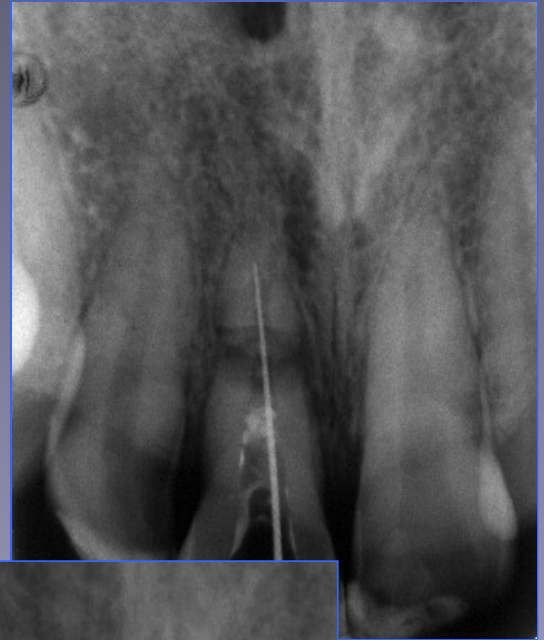
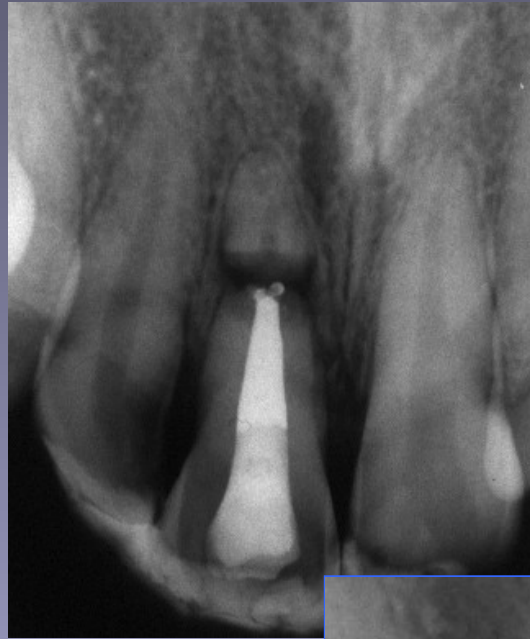
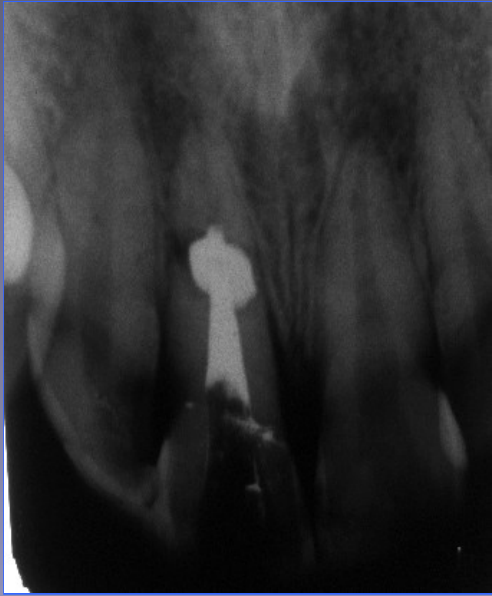
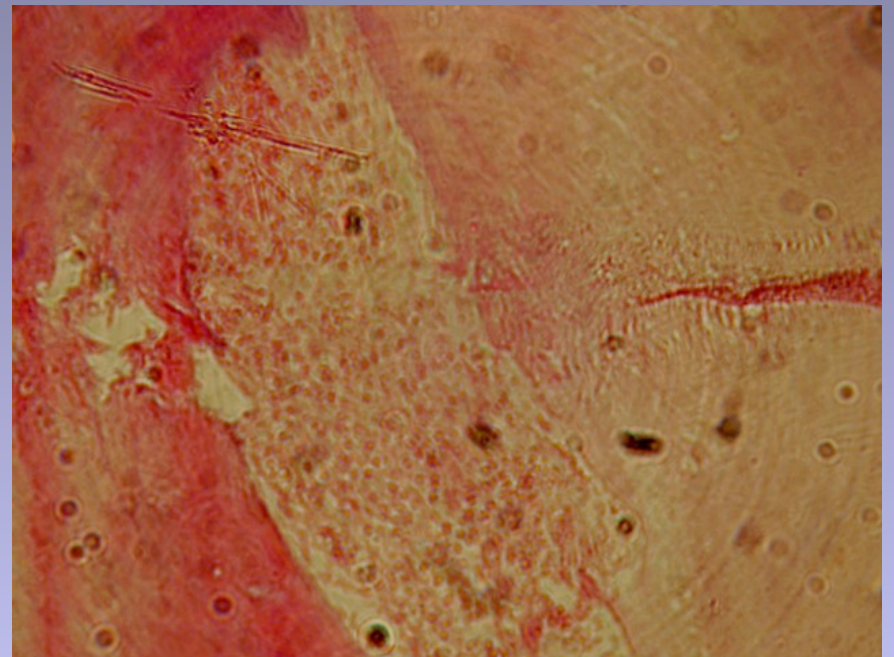
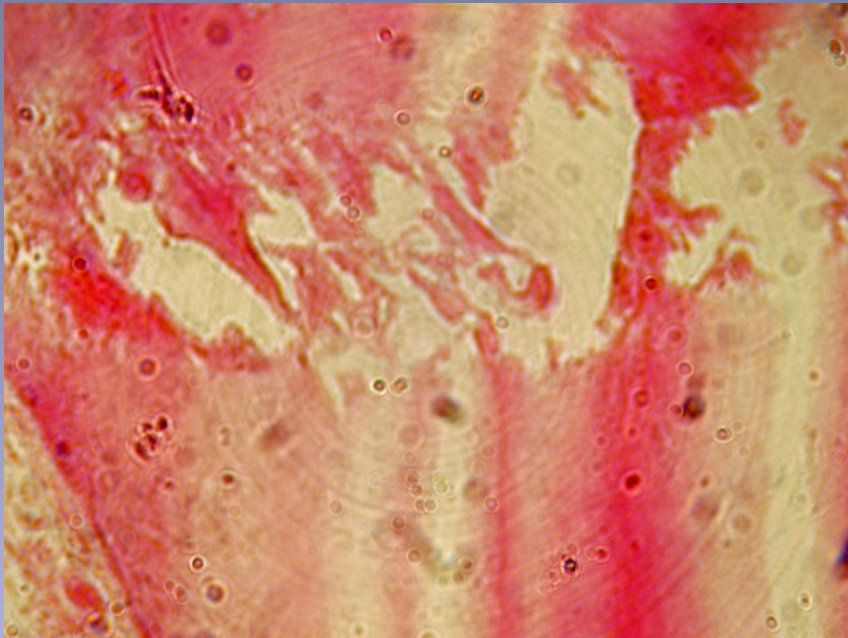


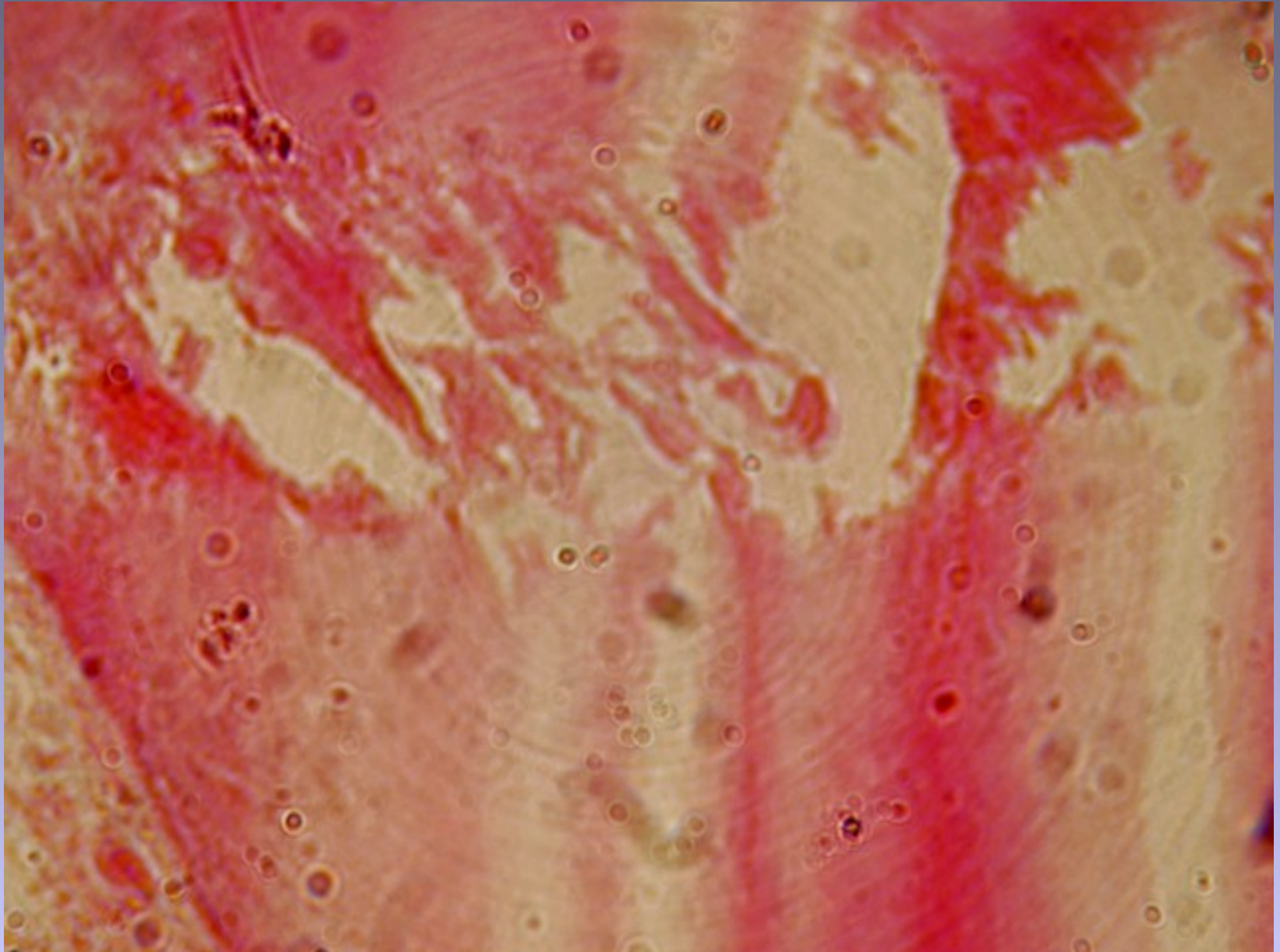Férulas semi rígidas.

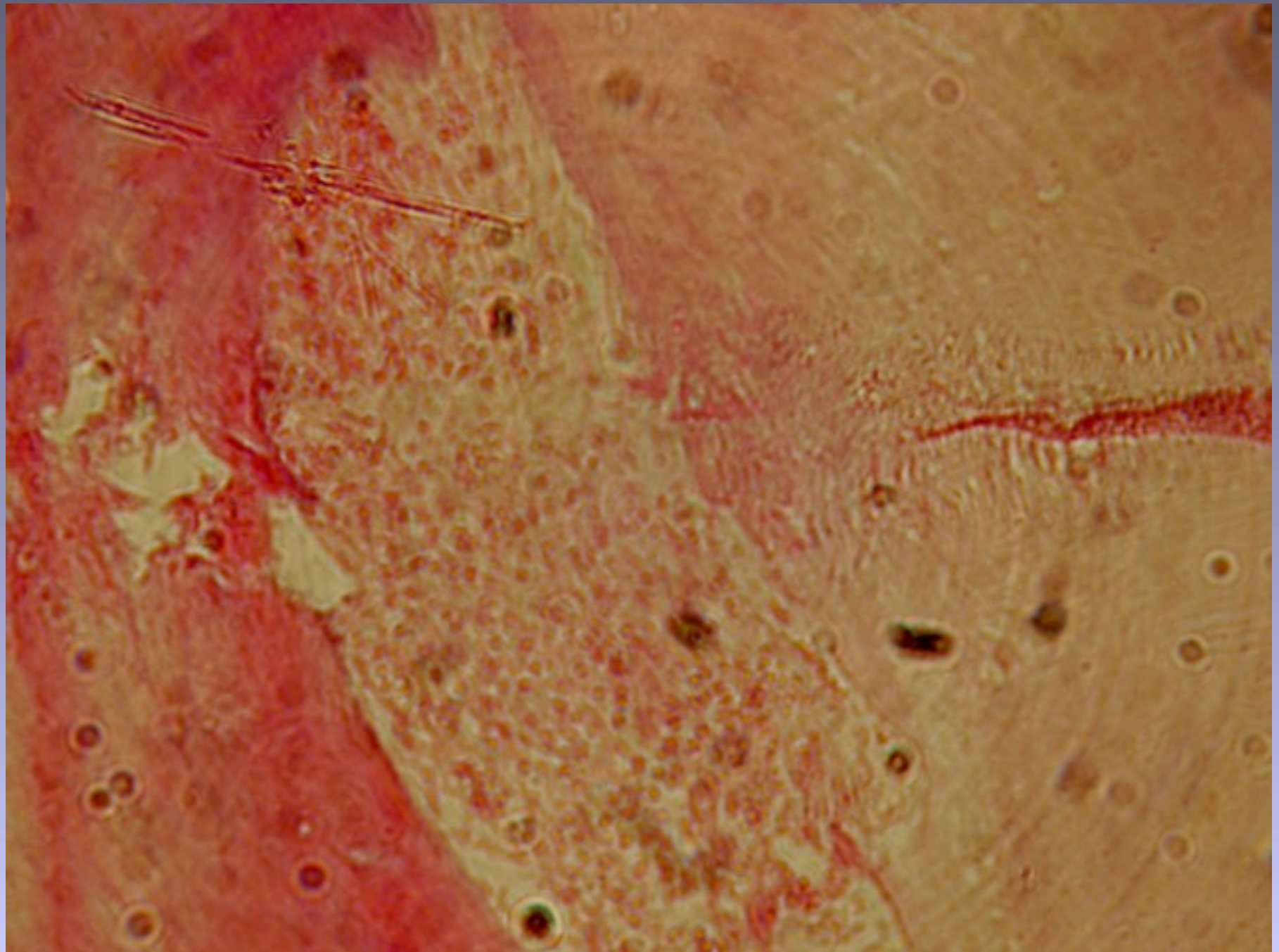
Luraschi Vannelli.

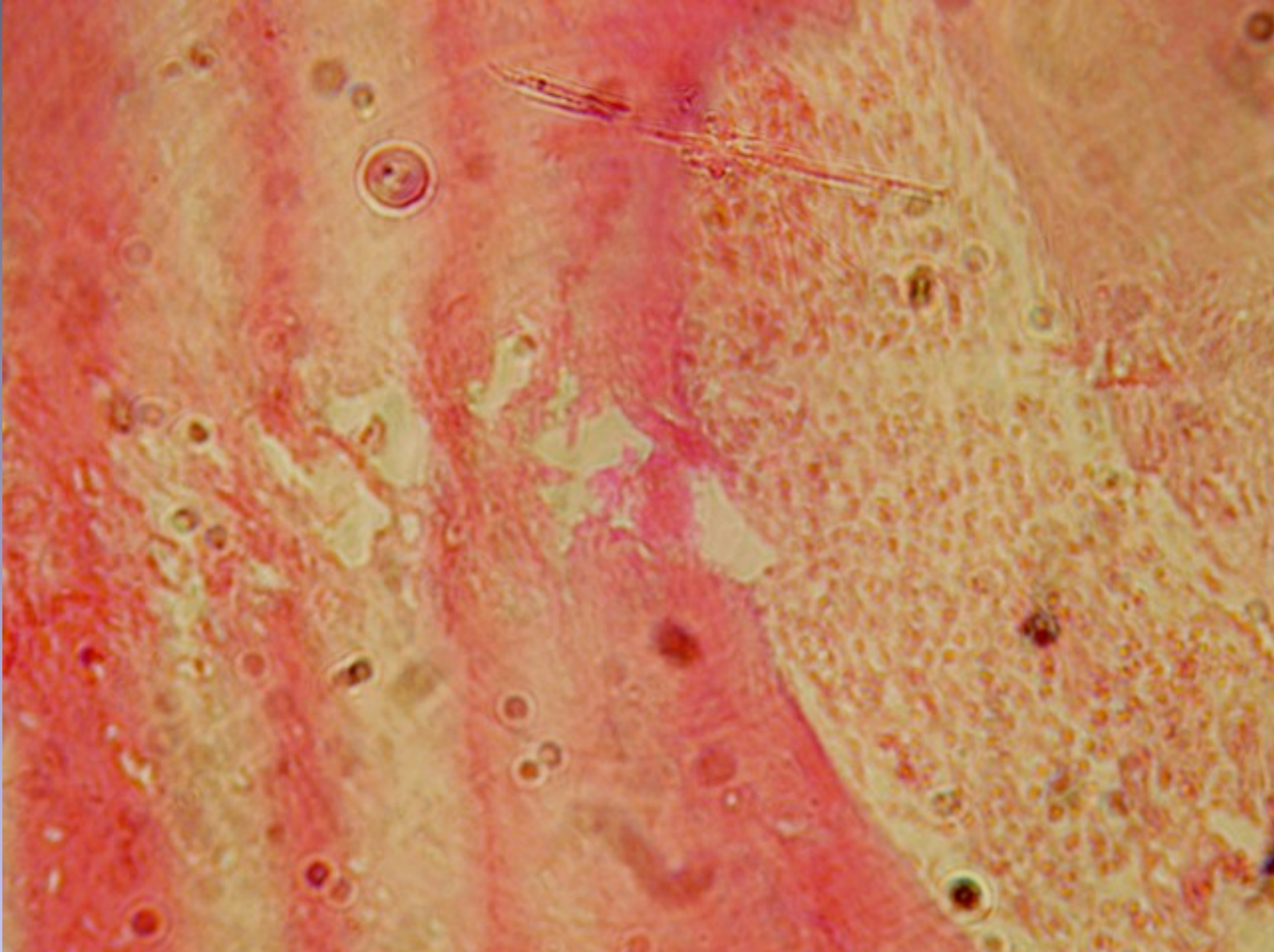


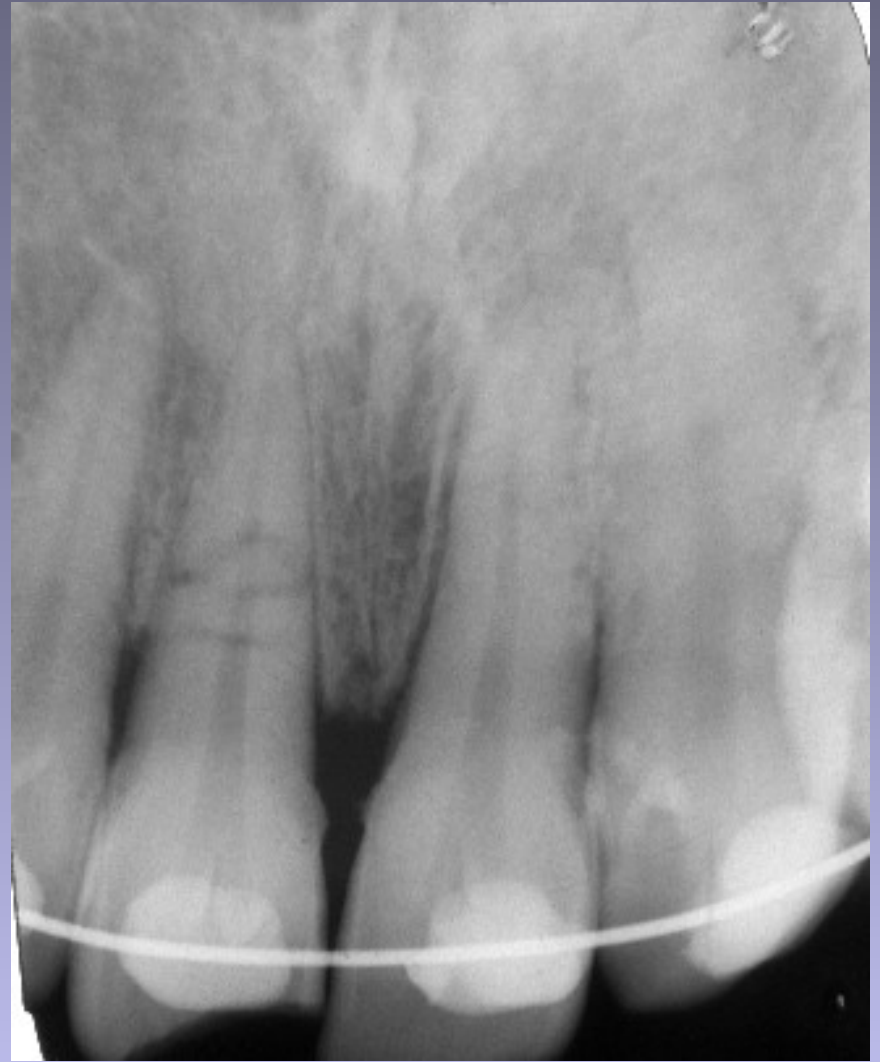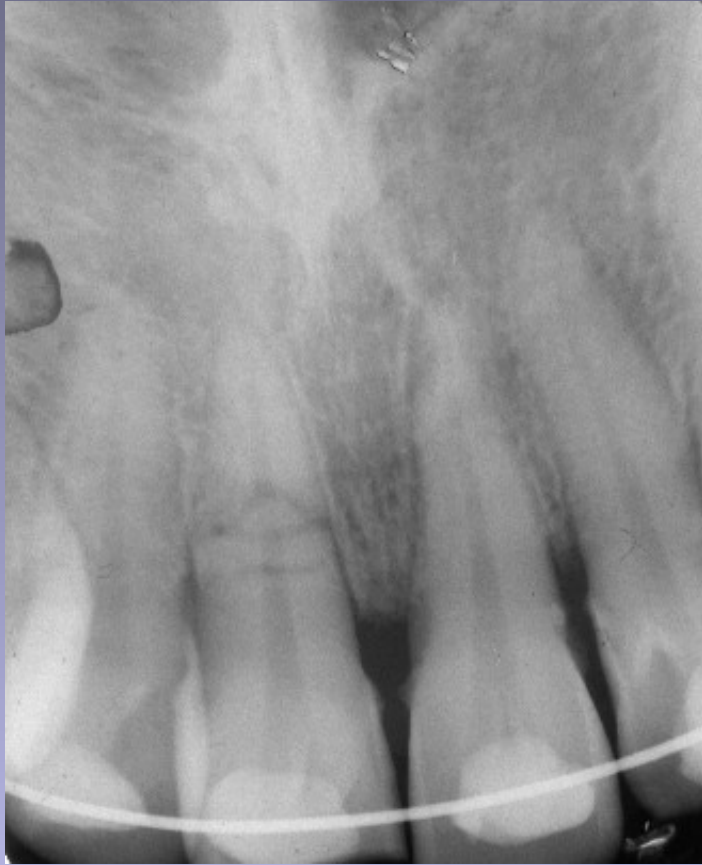Estudio Histológico

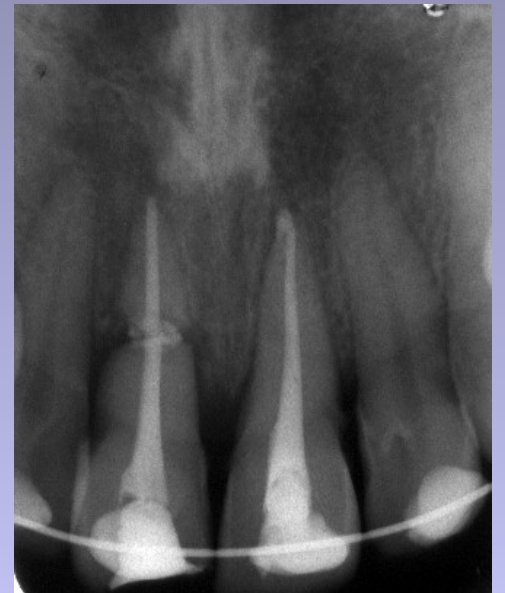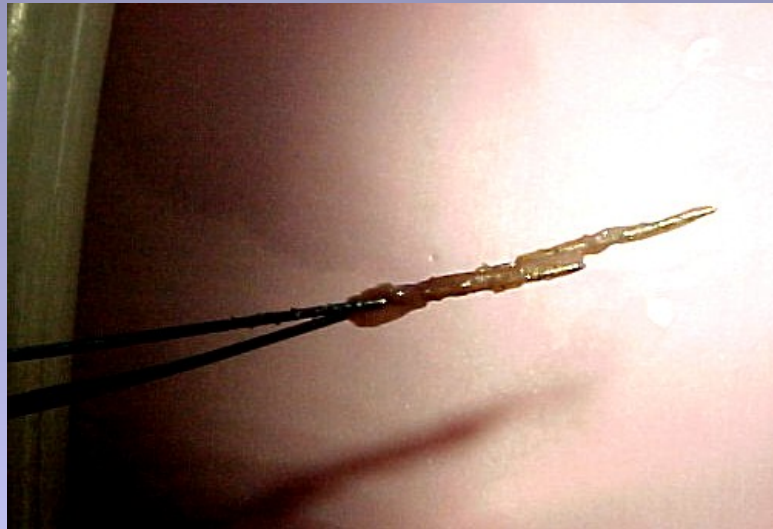
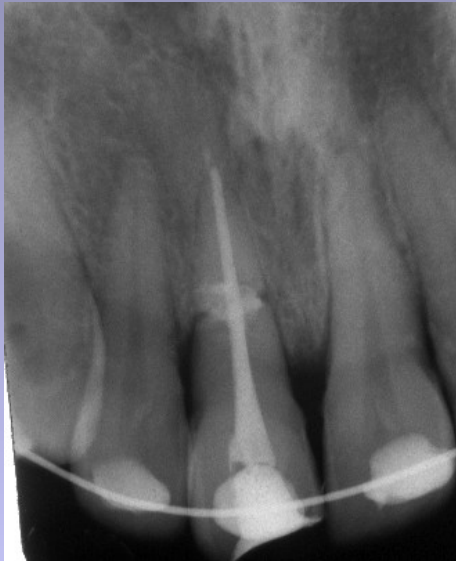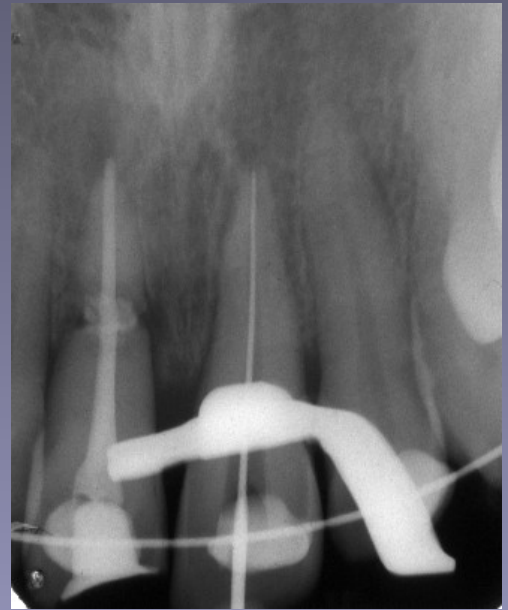
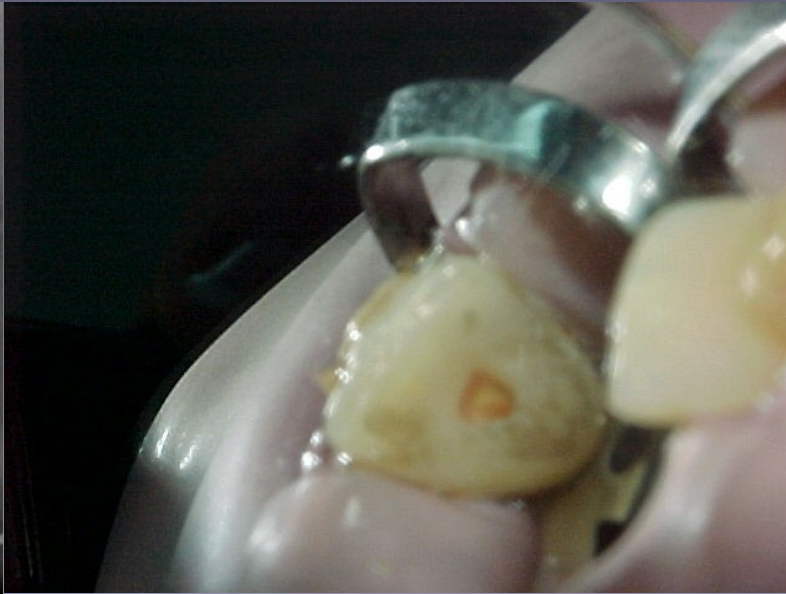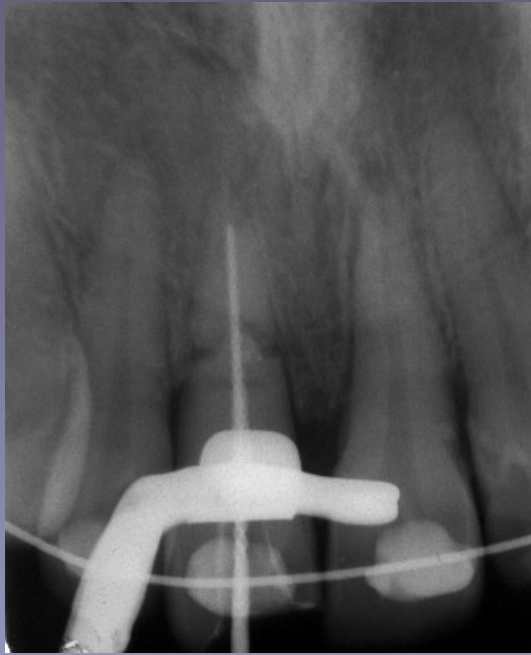











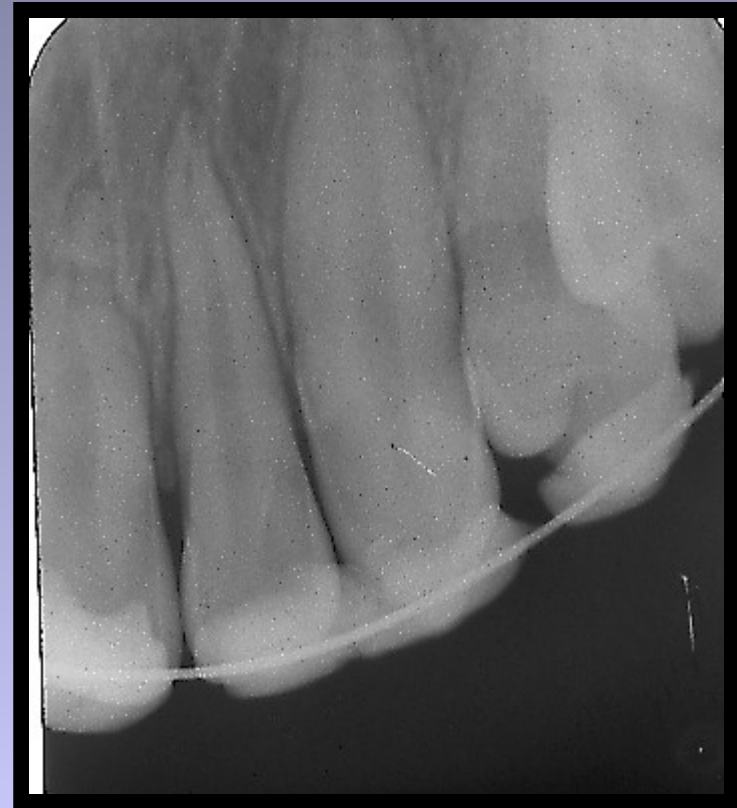
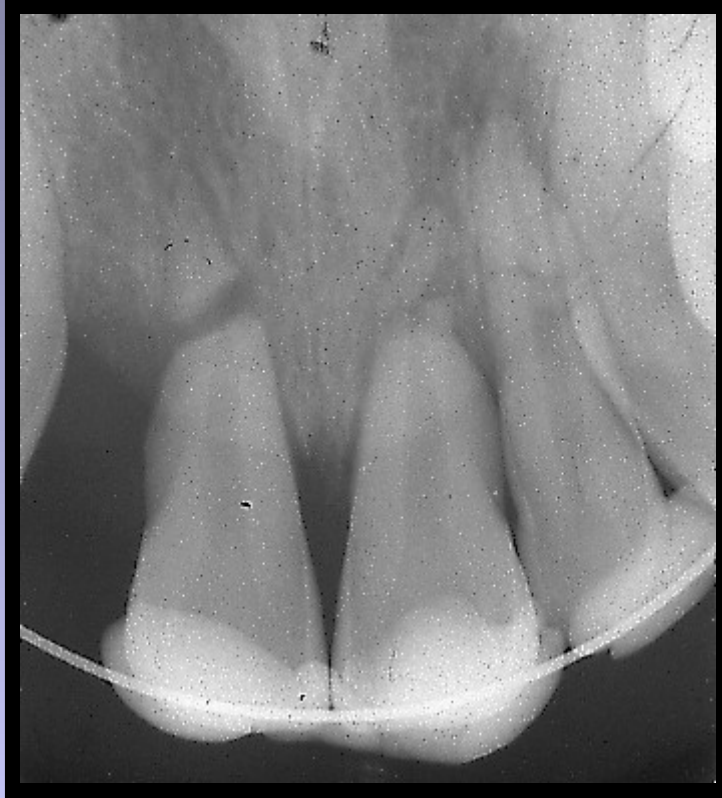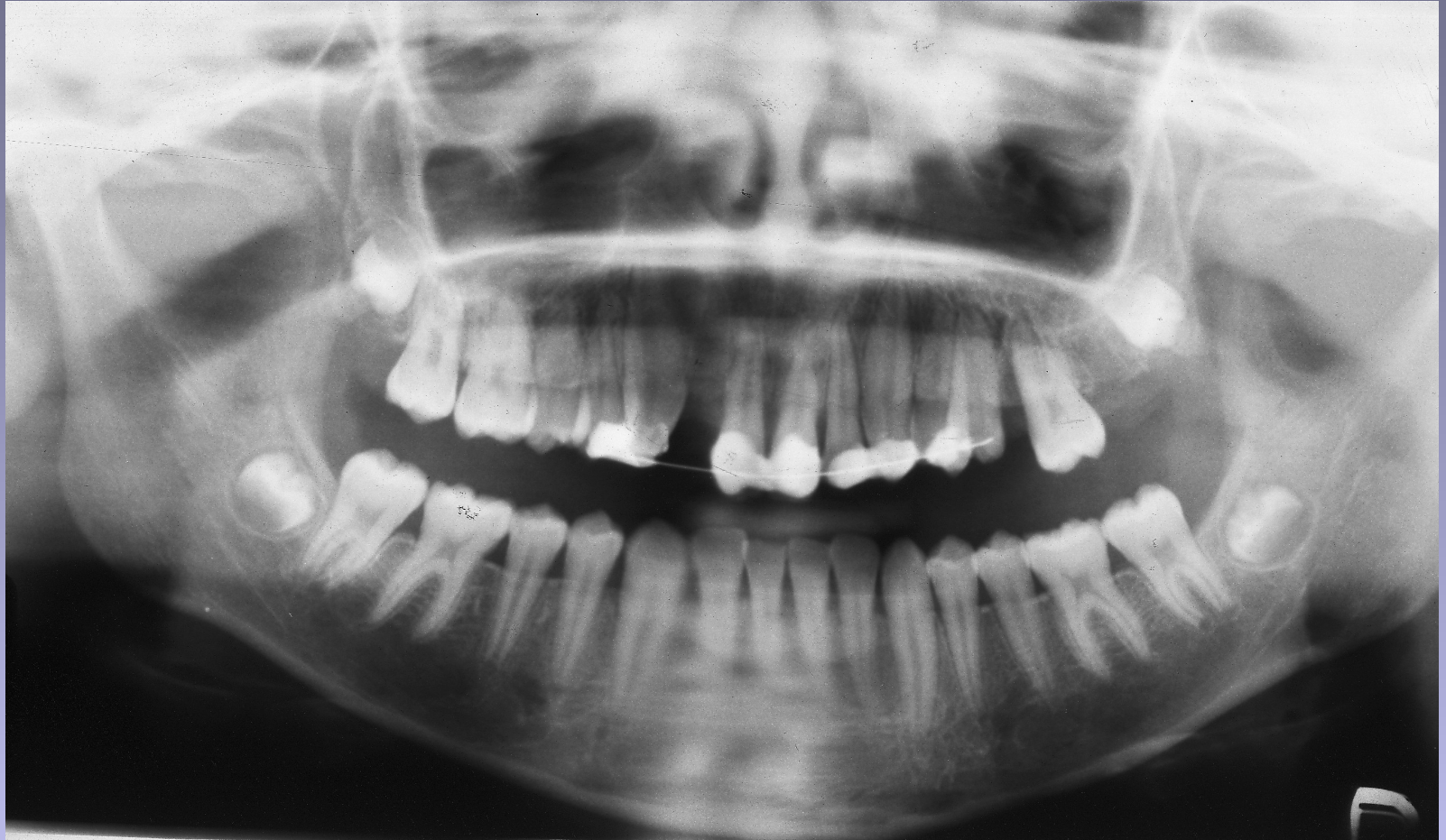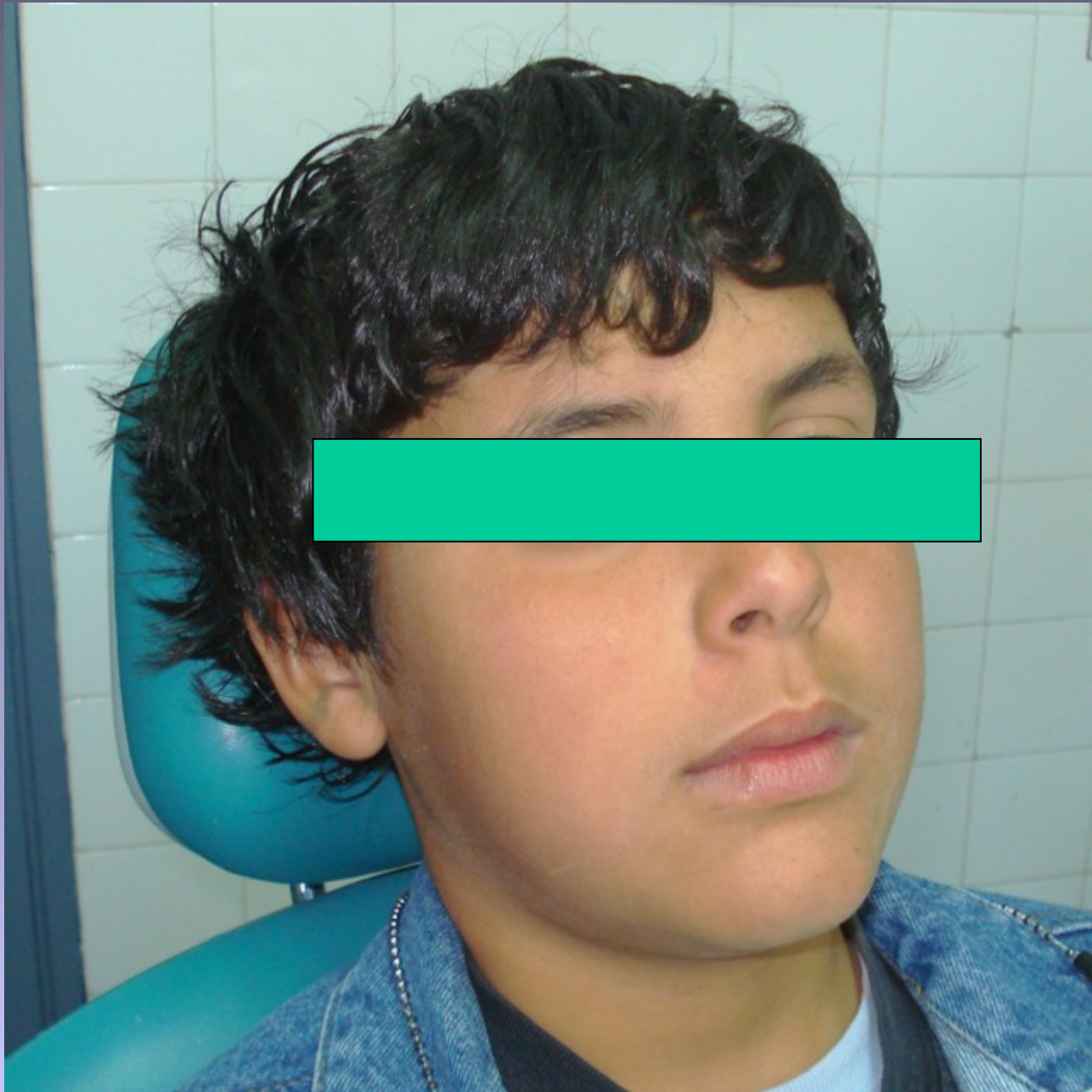Obturados con APEXIT

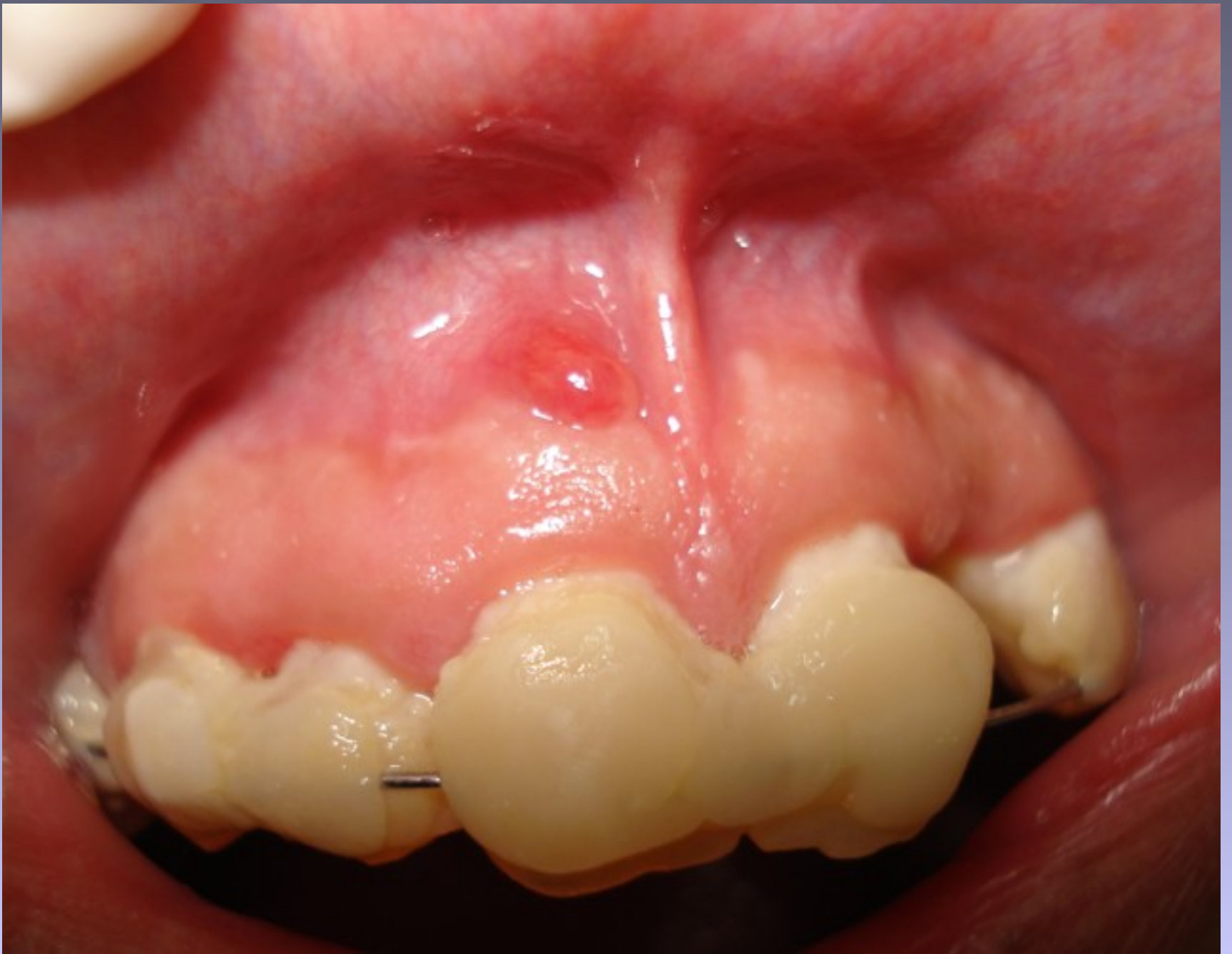Traumatismos Múltiples.

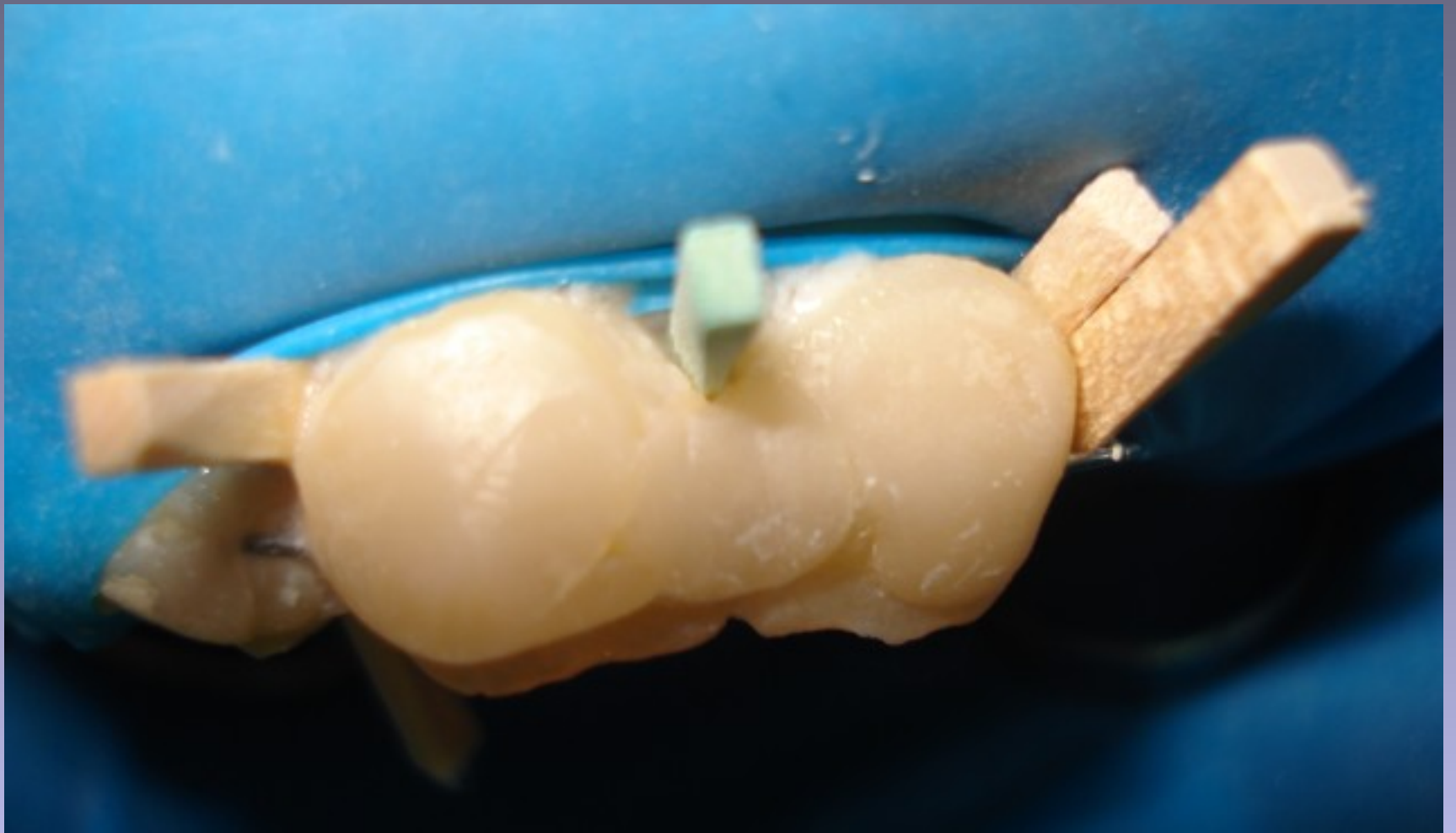
- Avulsión sin reimplante.-Fracturas 1/3 Apical

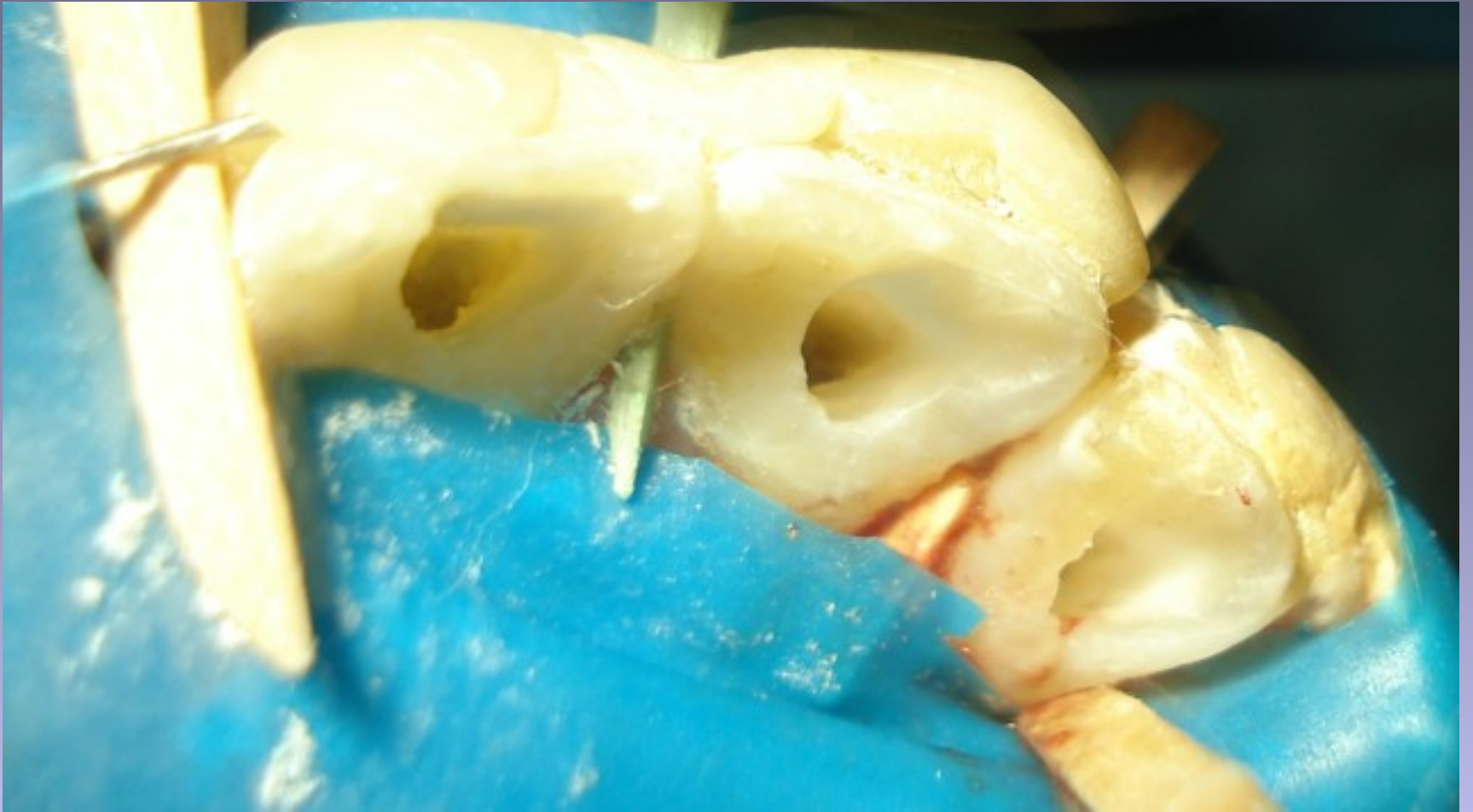


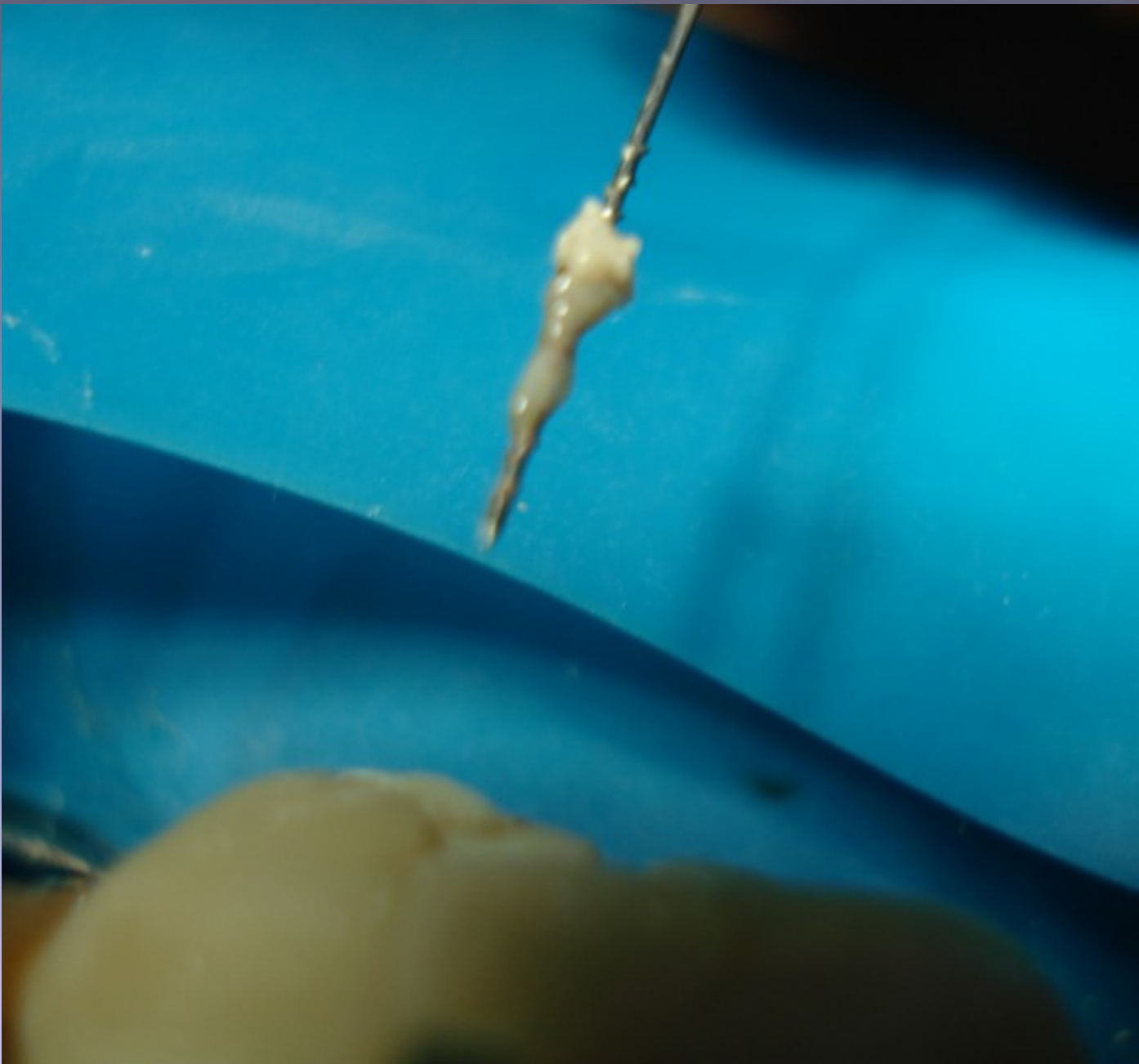




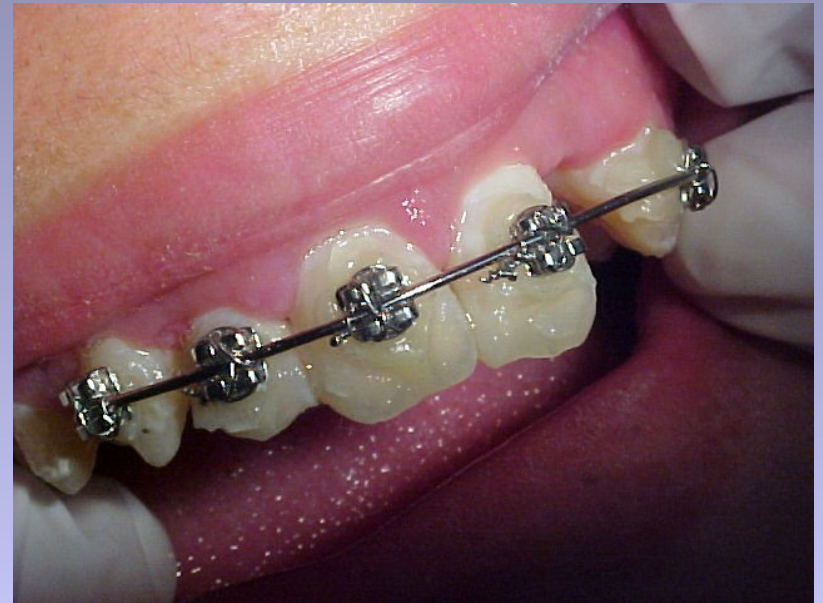
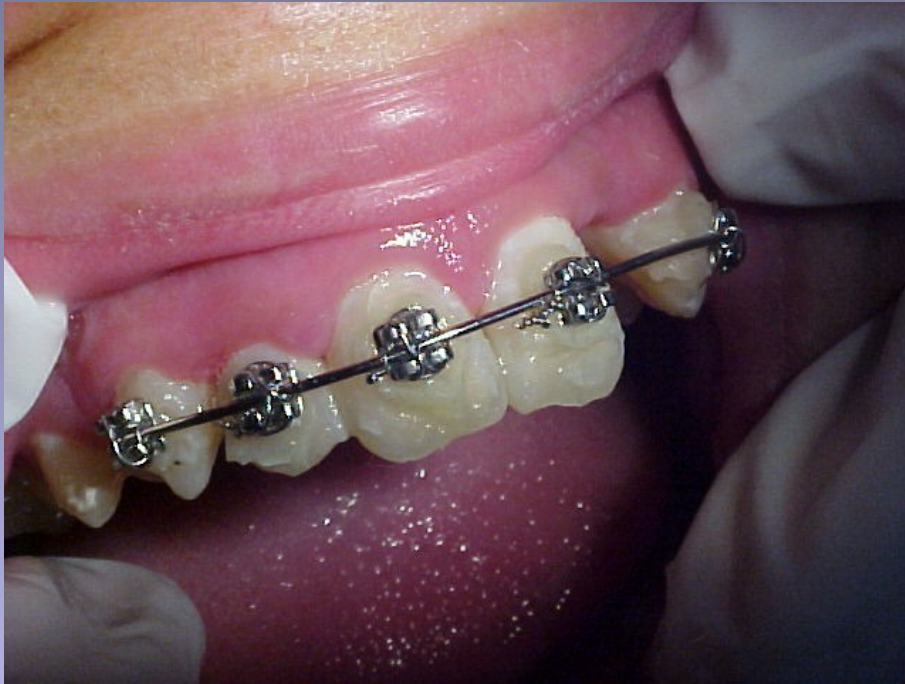




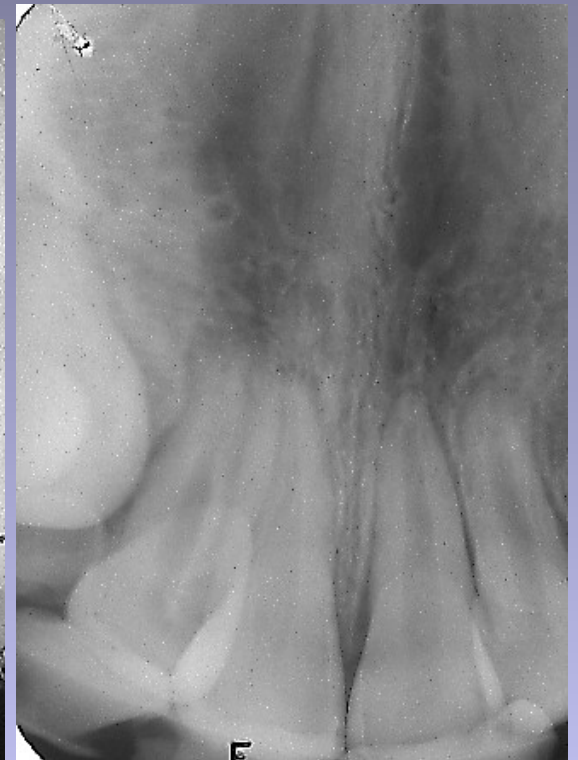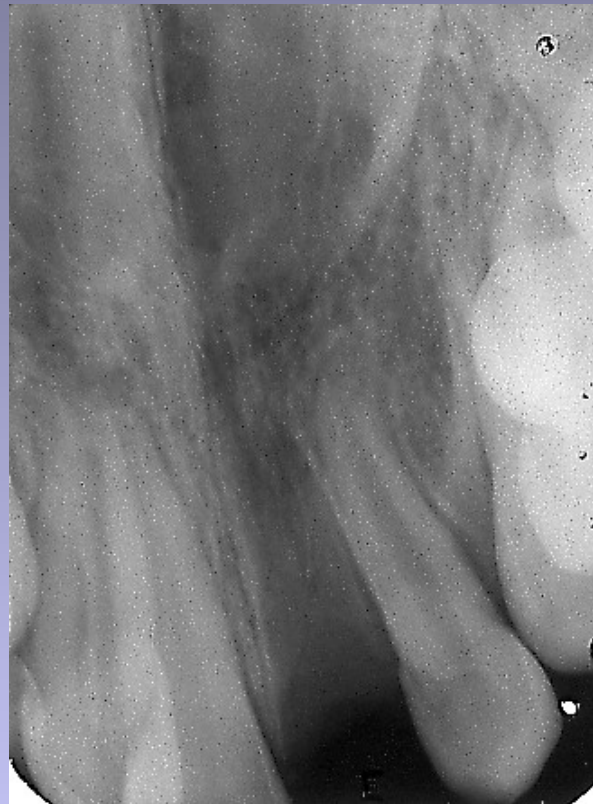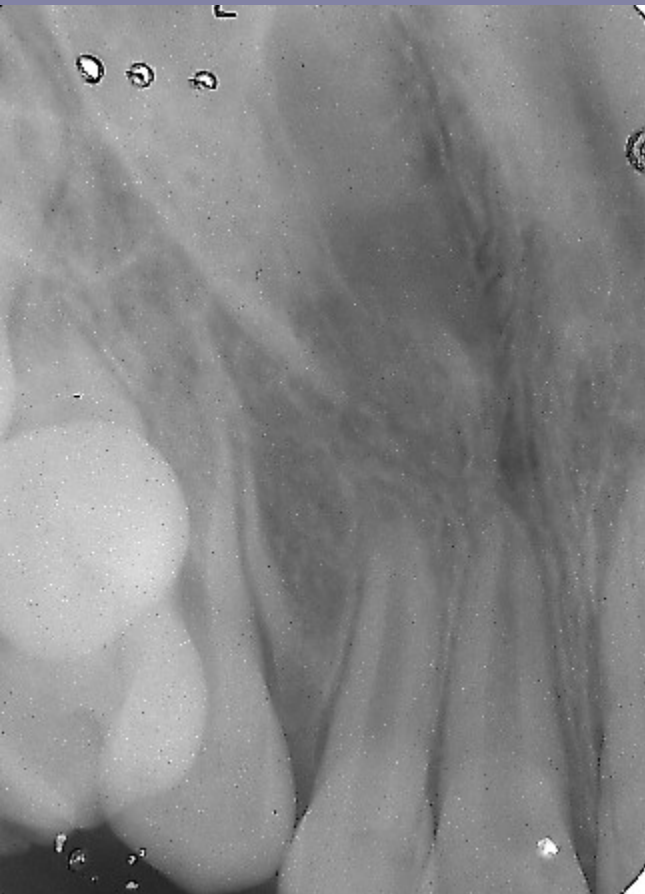


2º Férula Semi rígida

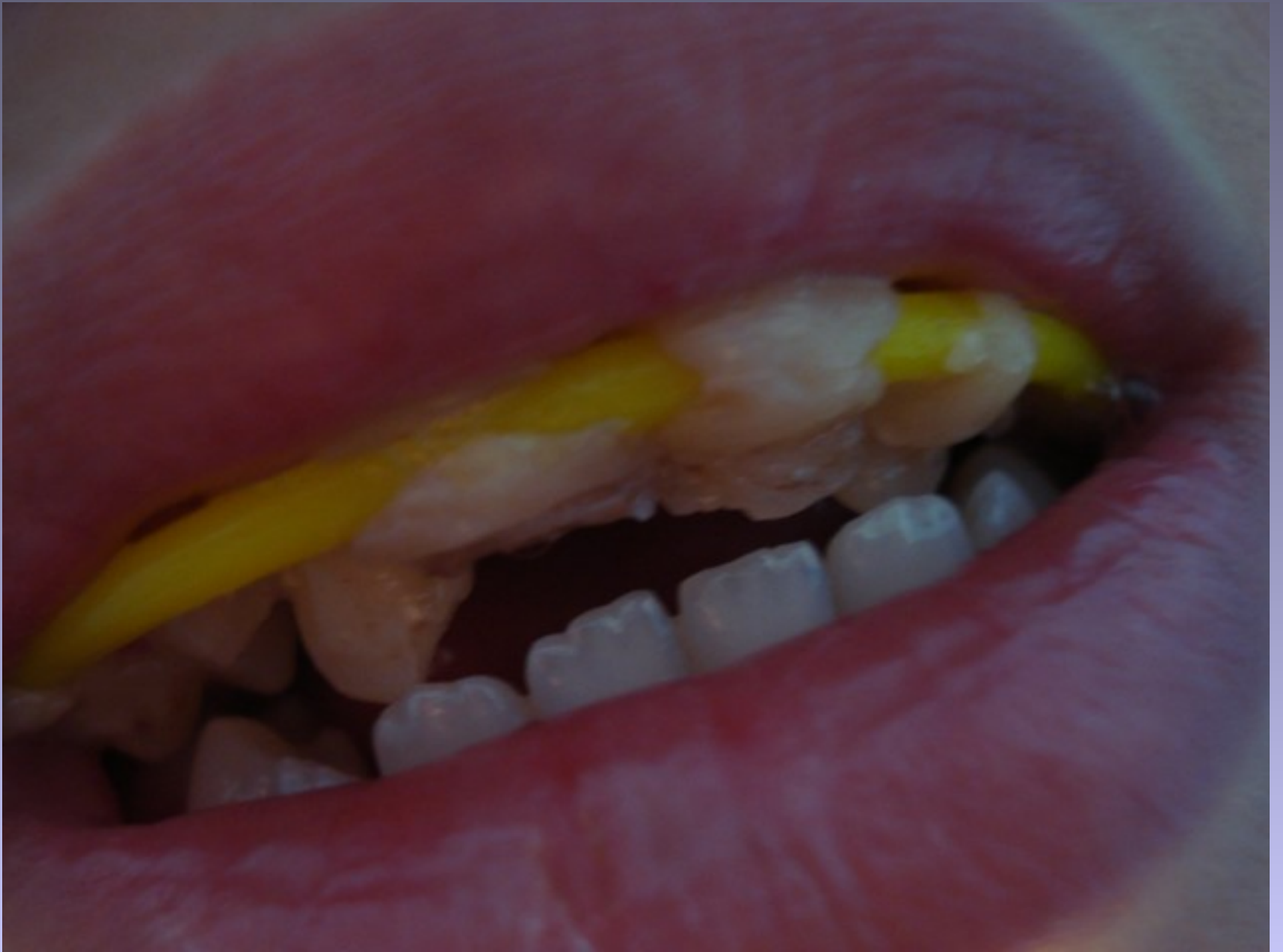

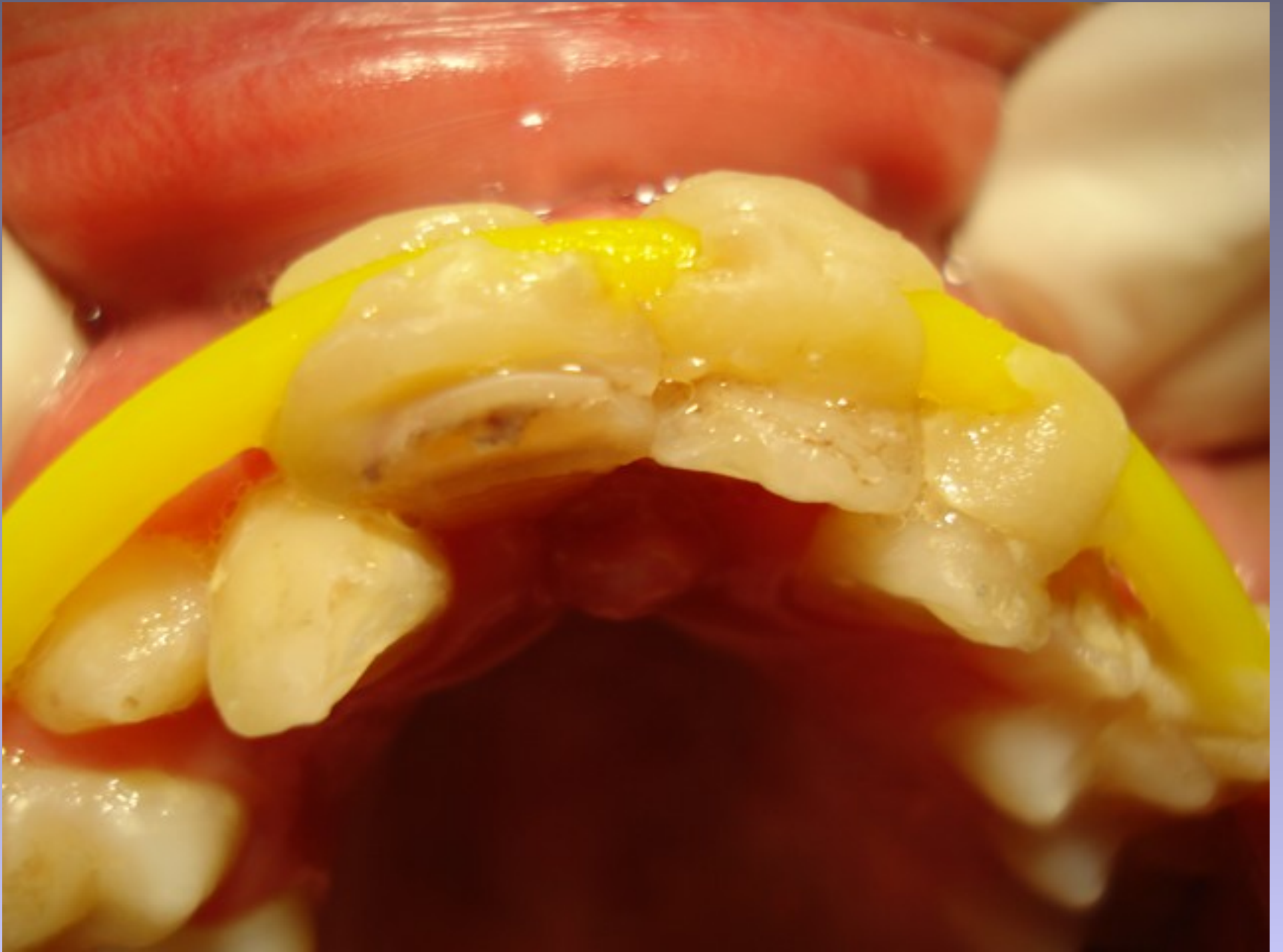Traumatismos Múltiples

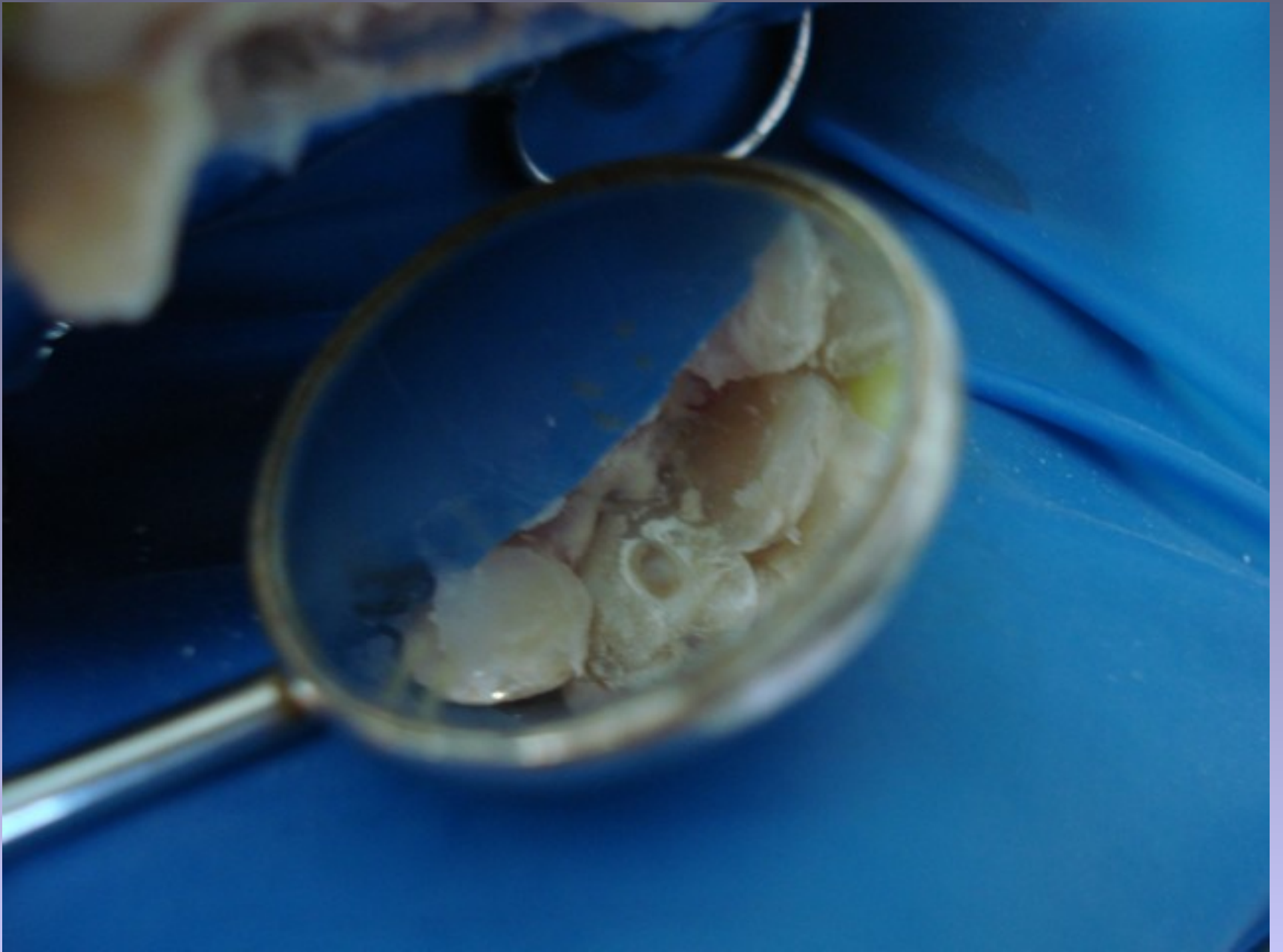- Avulsión –Fracturas Coronarias



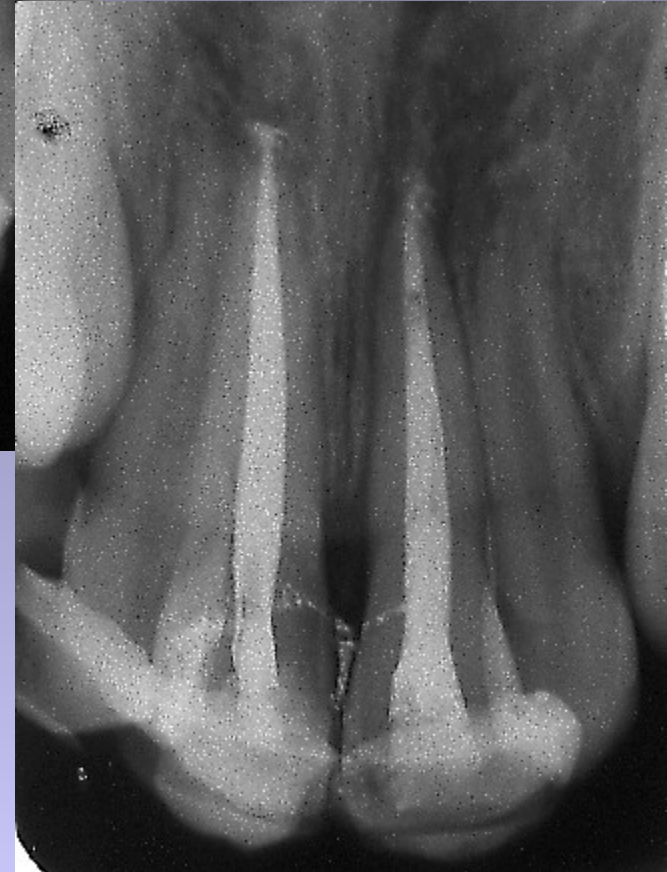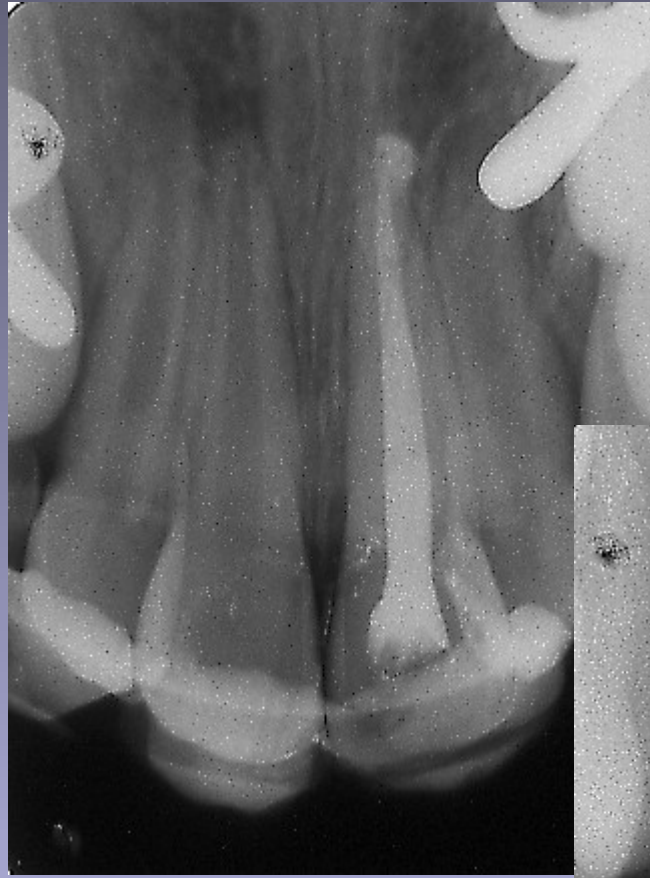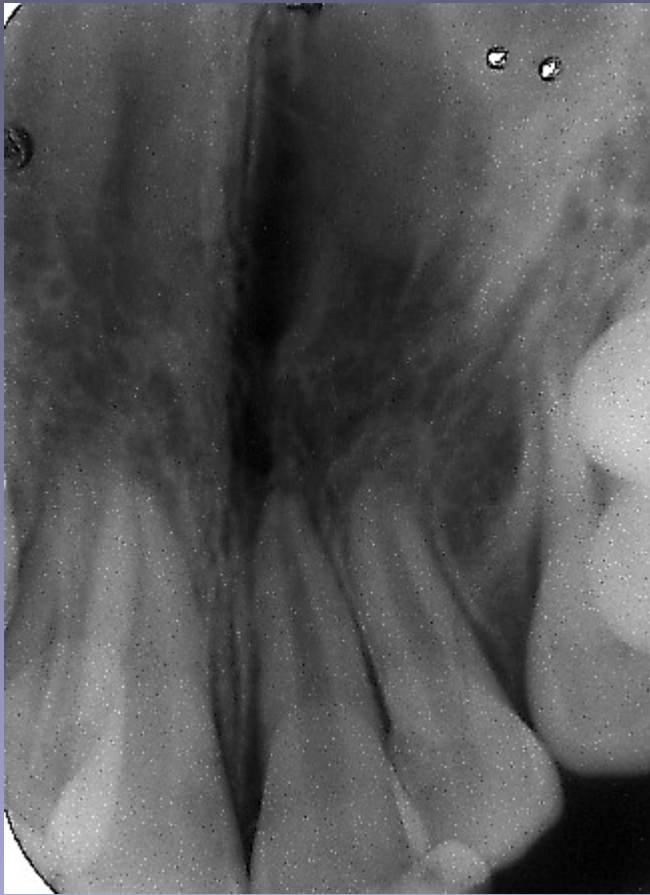Reimplante y Férula





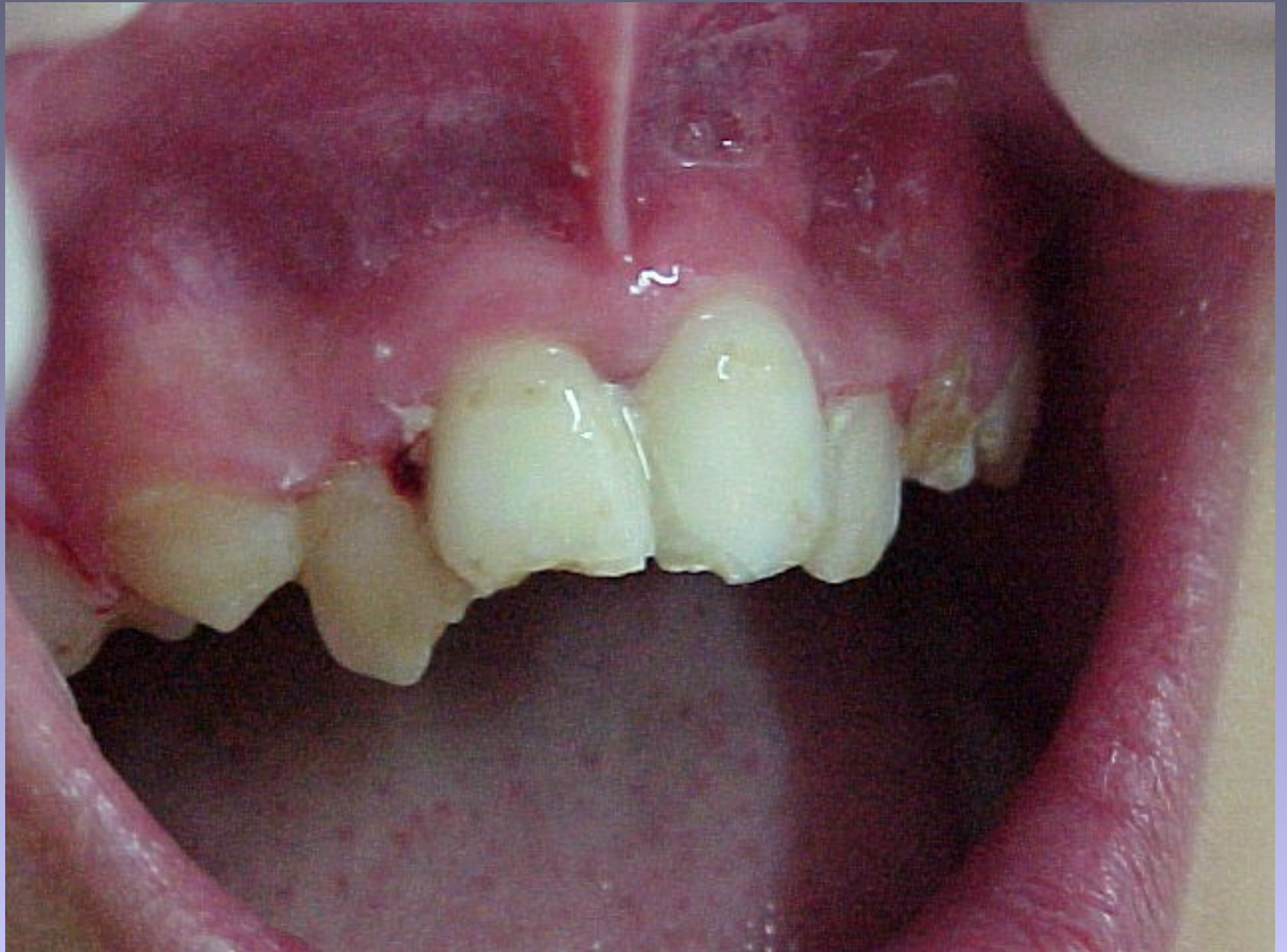


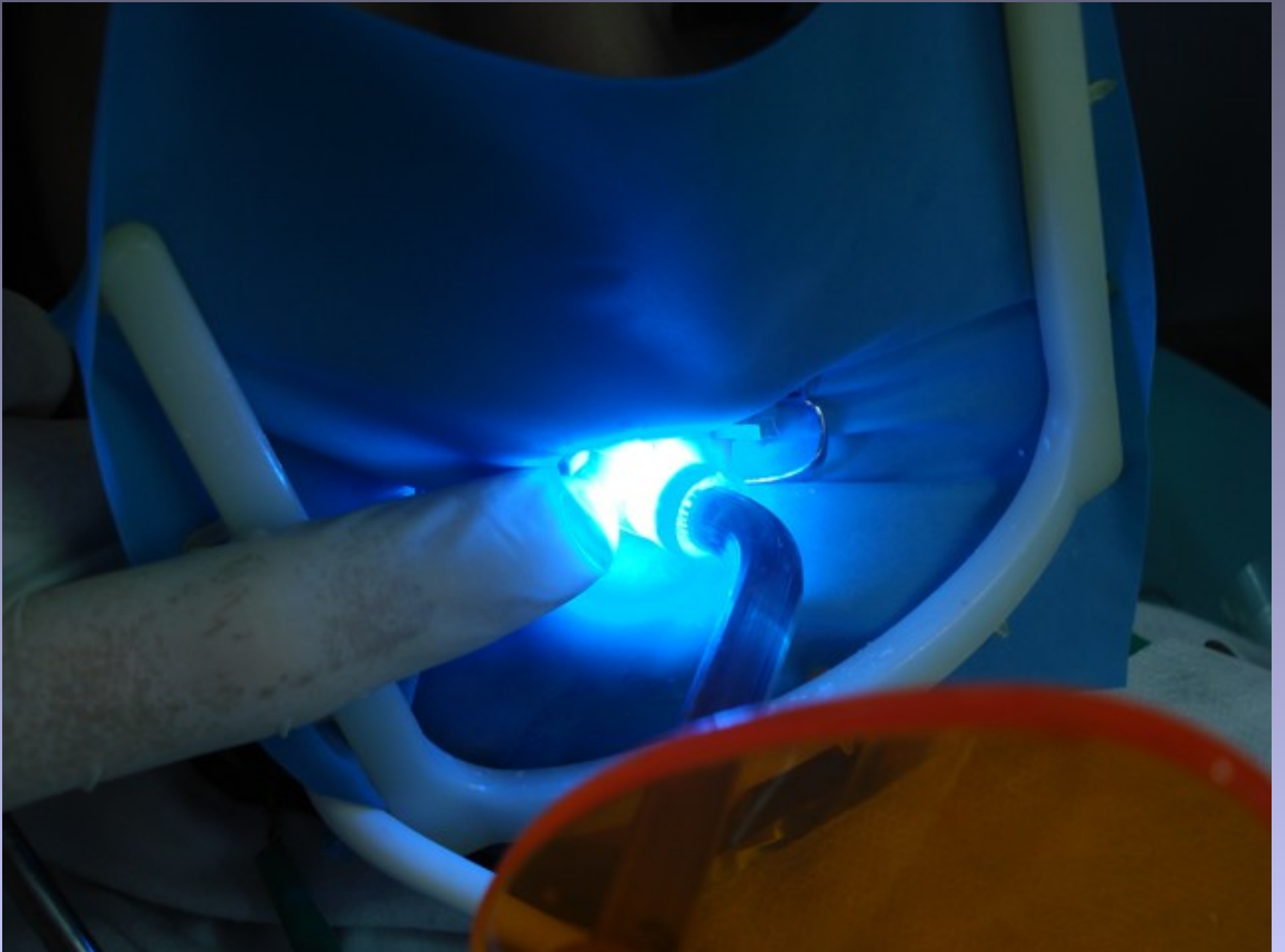


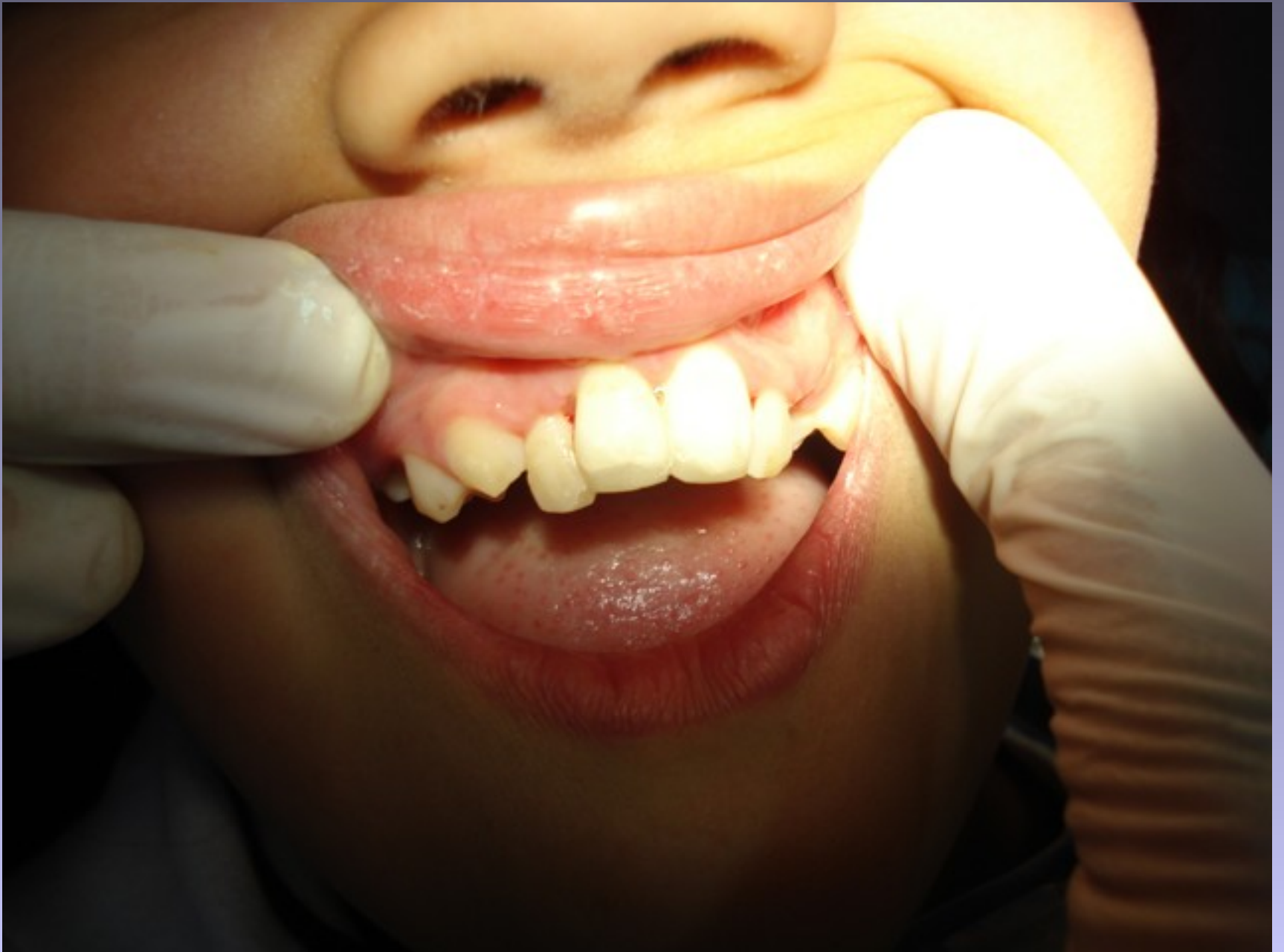Control a 15 días del reimplante.

Tratamientos intermedios.



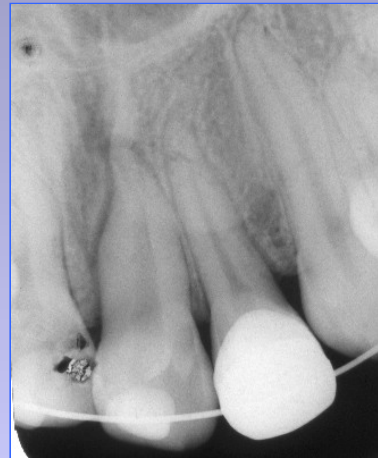
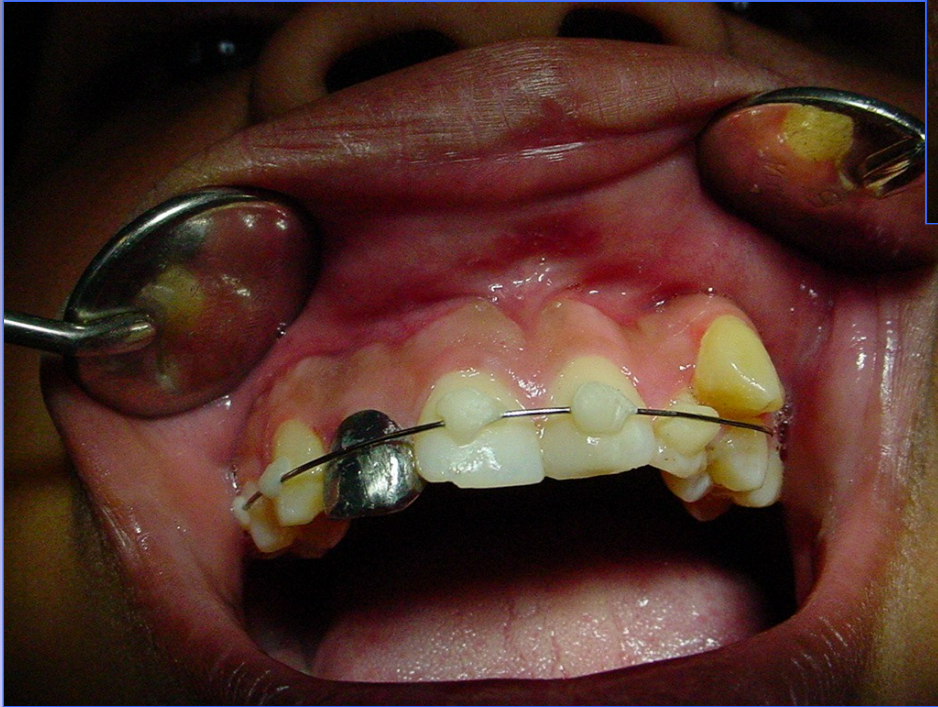
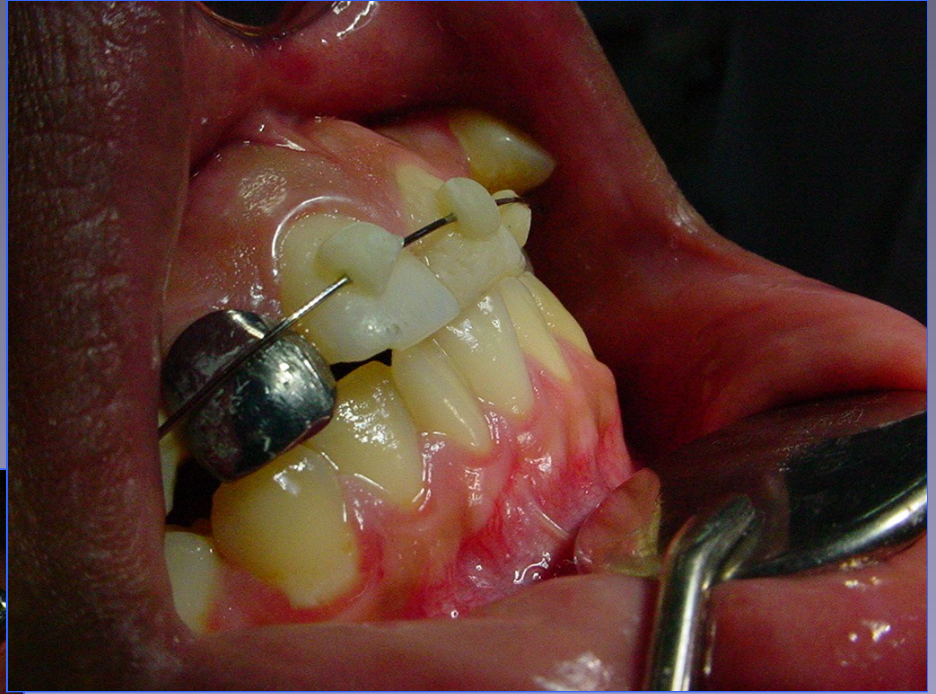
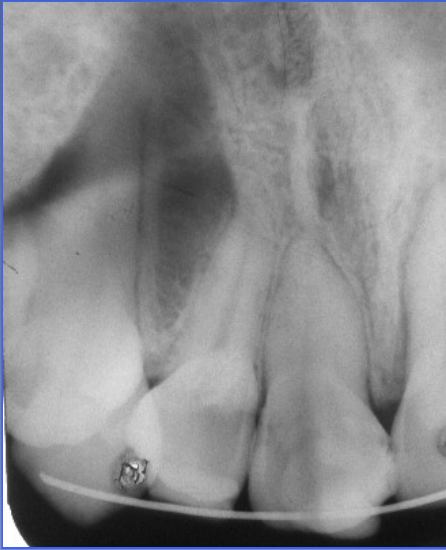


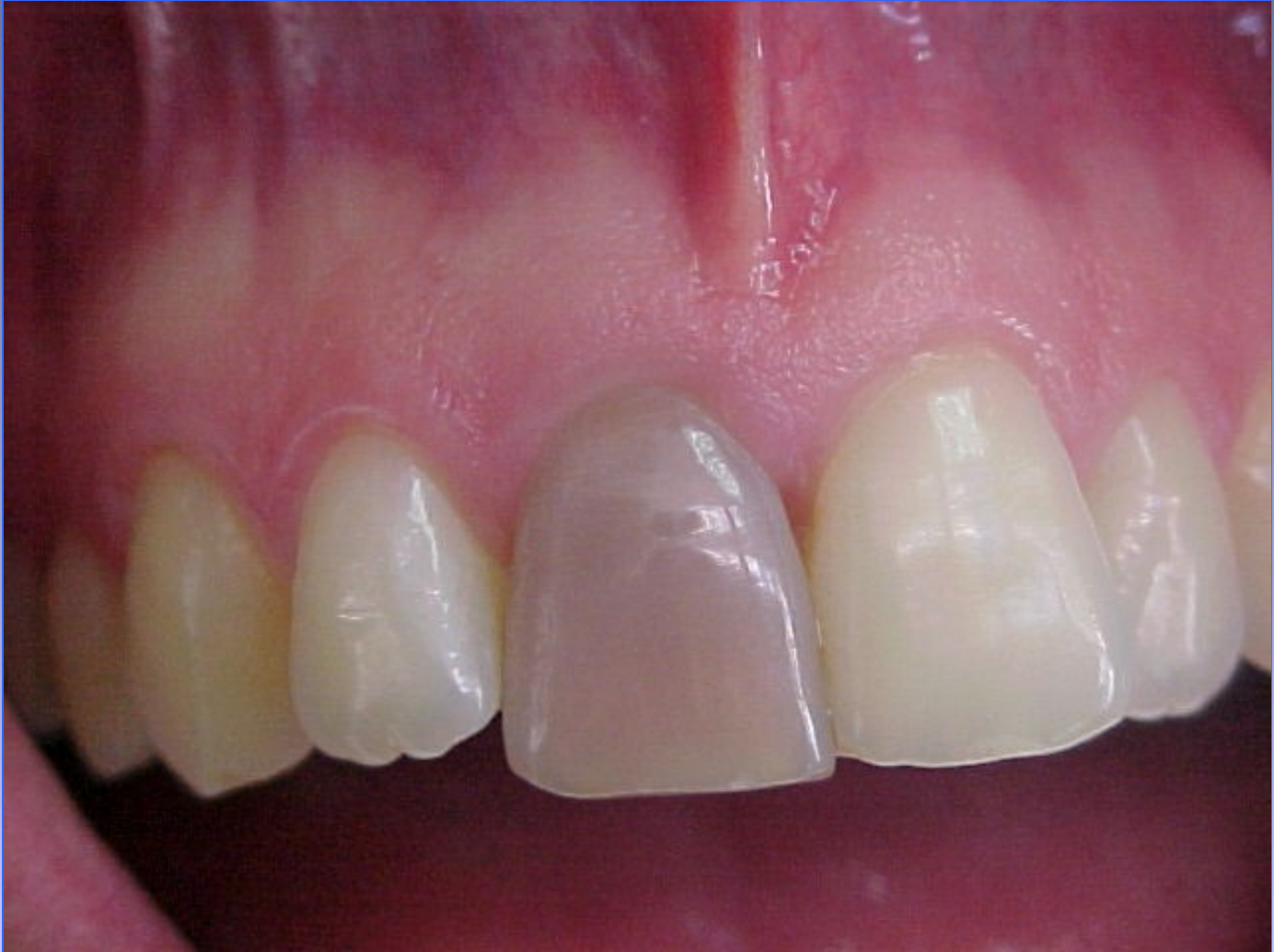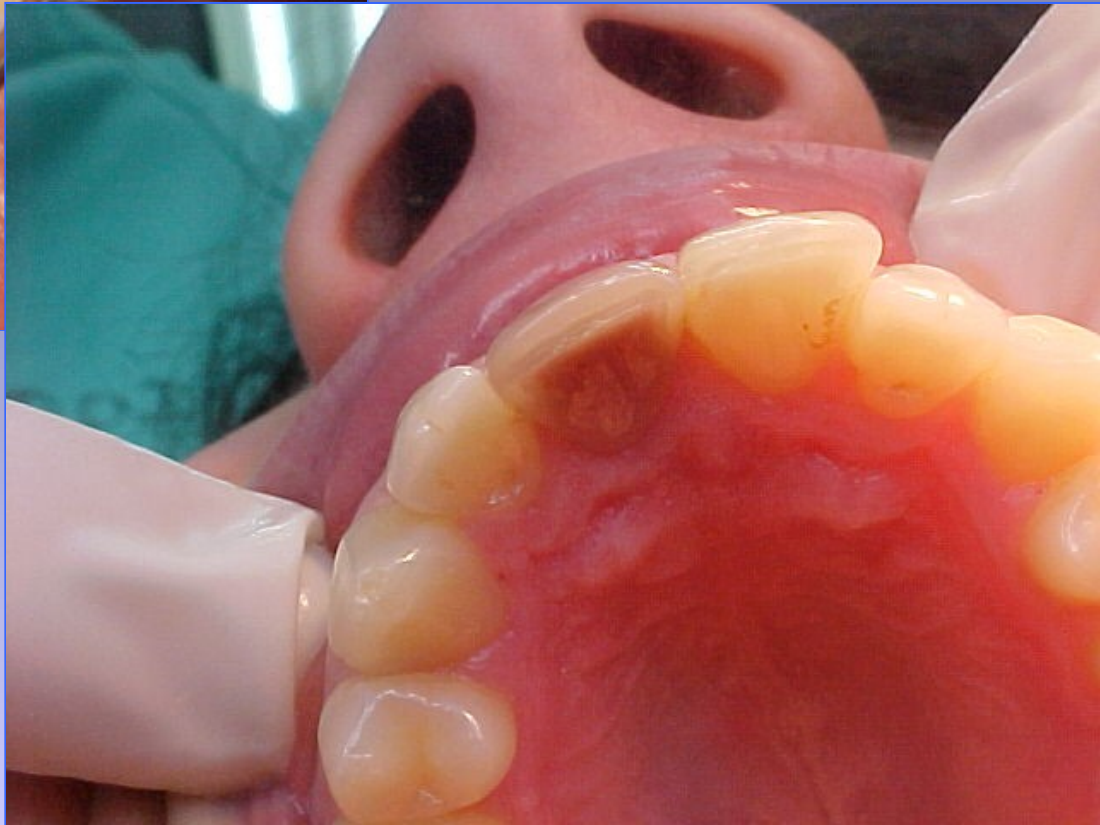
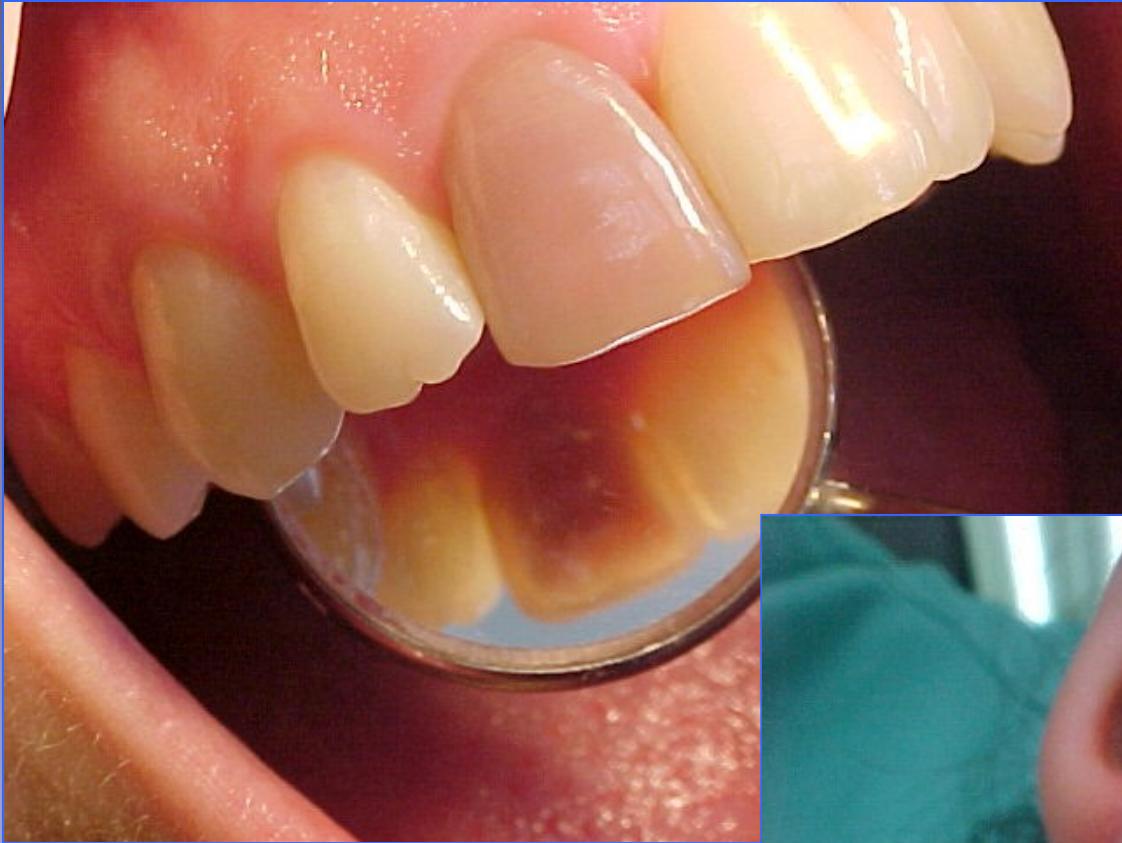Traumatismos con desplazamientos

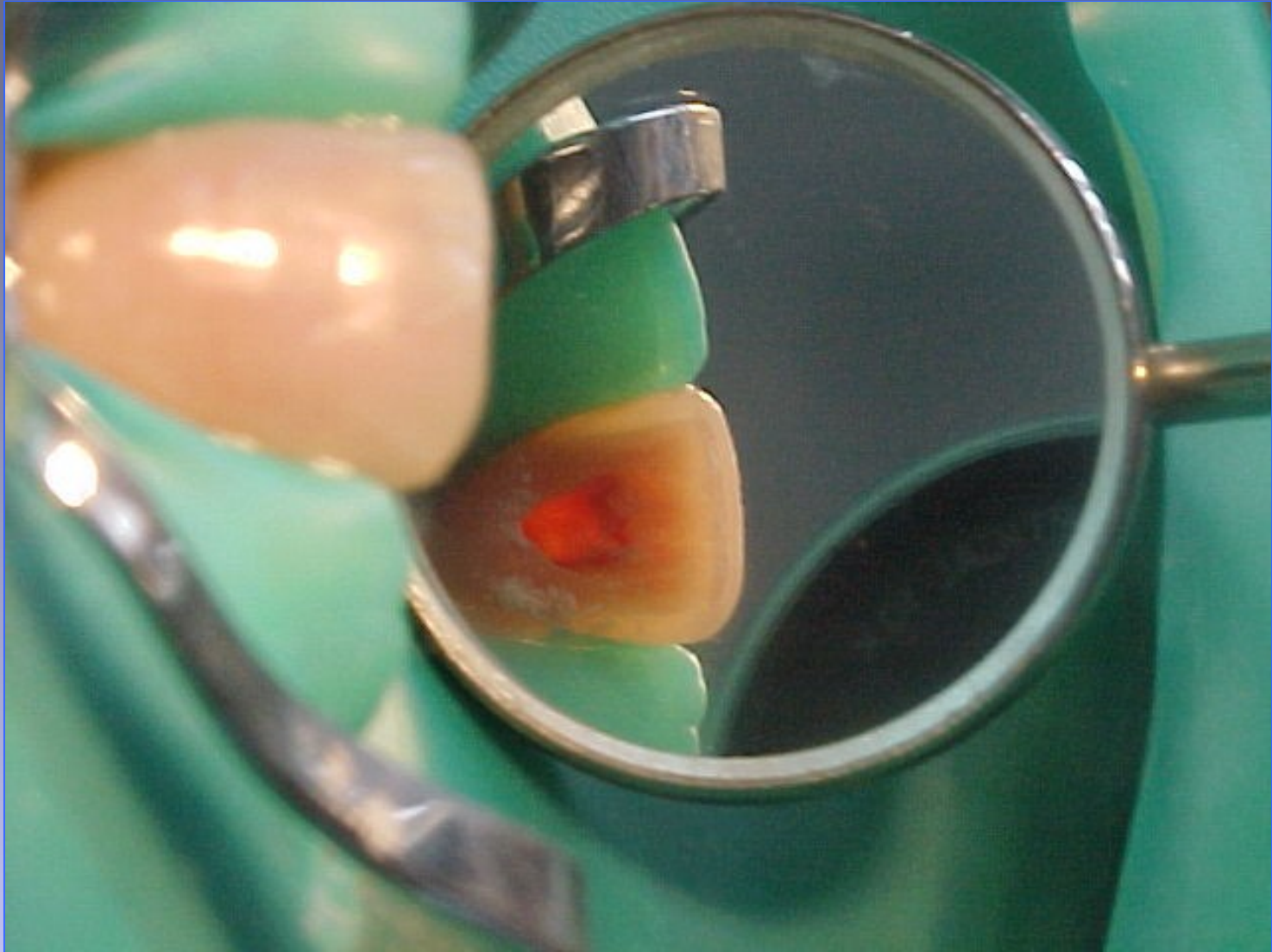...y sin pérdida de sustancia.

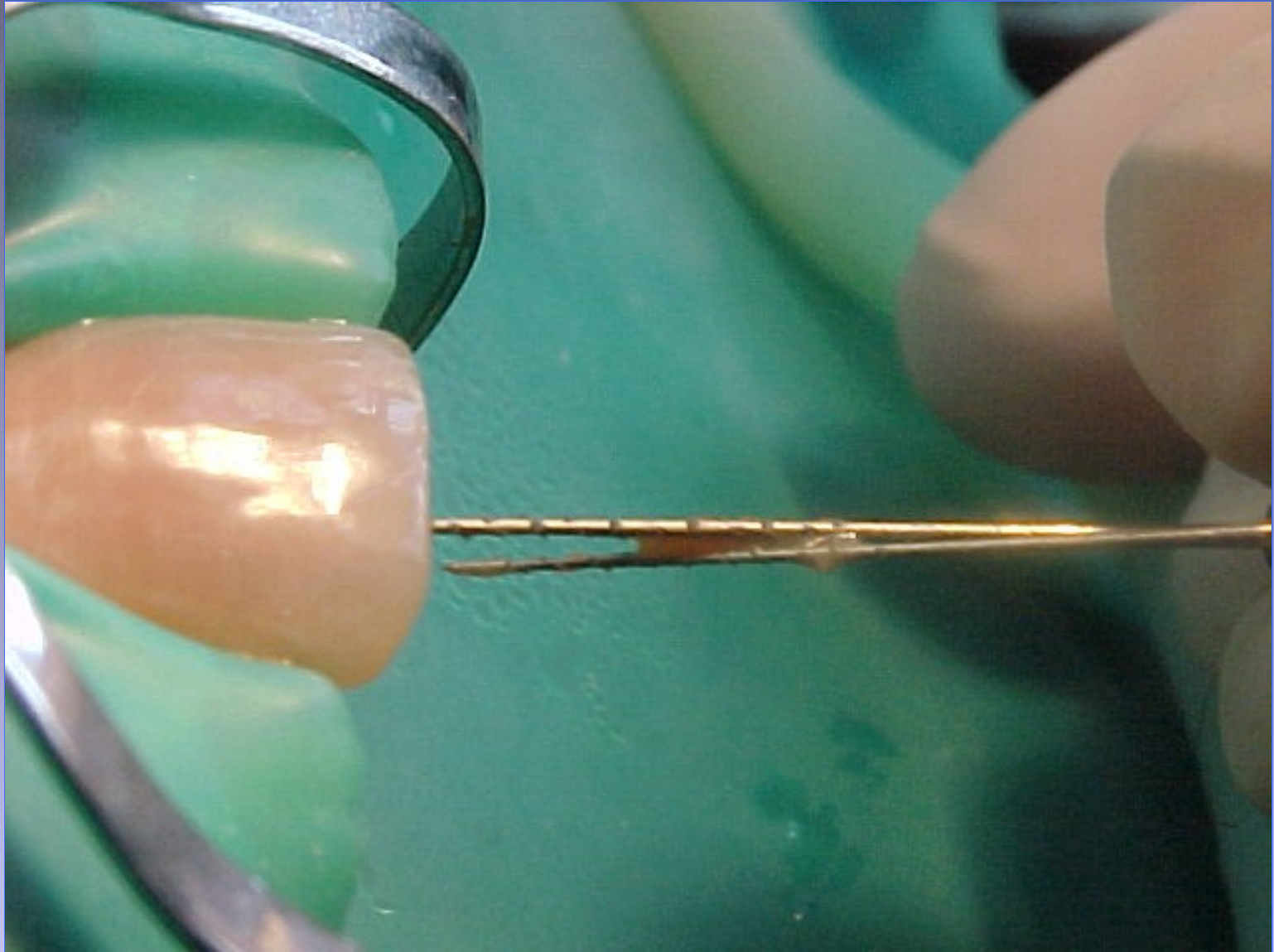


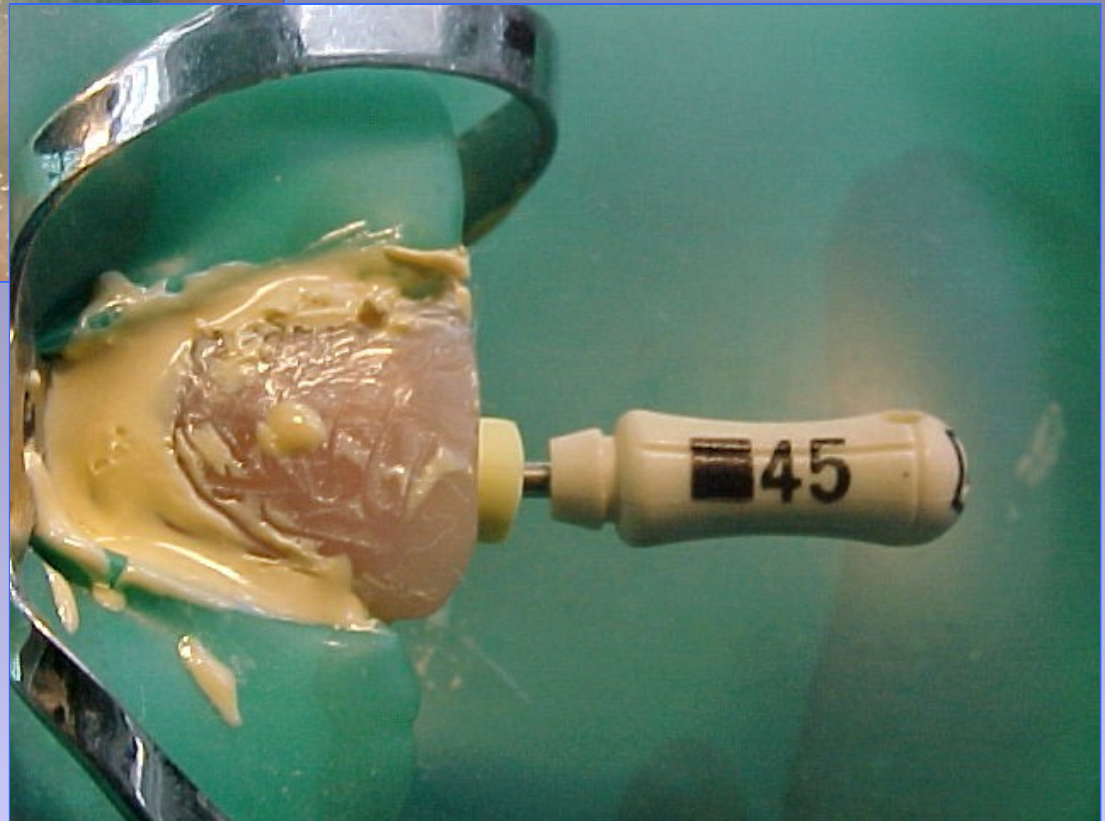
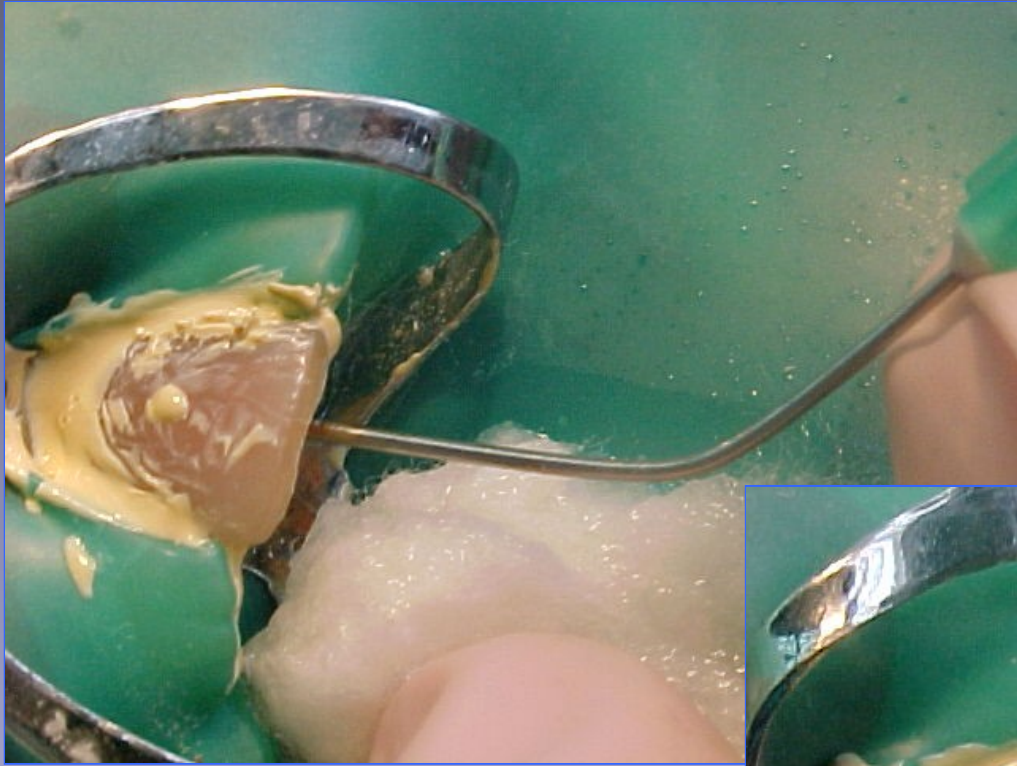
Concusión.....respuesta pulpar.

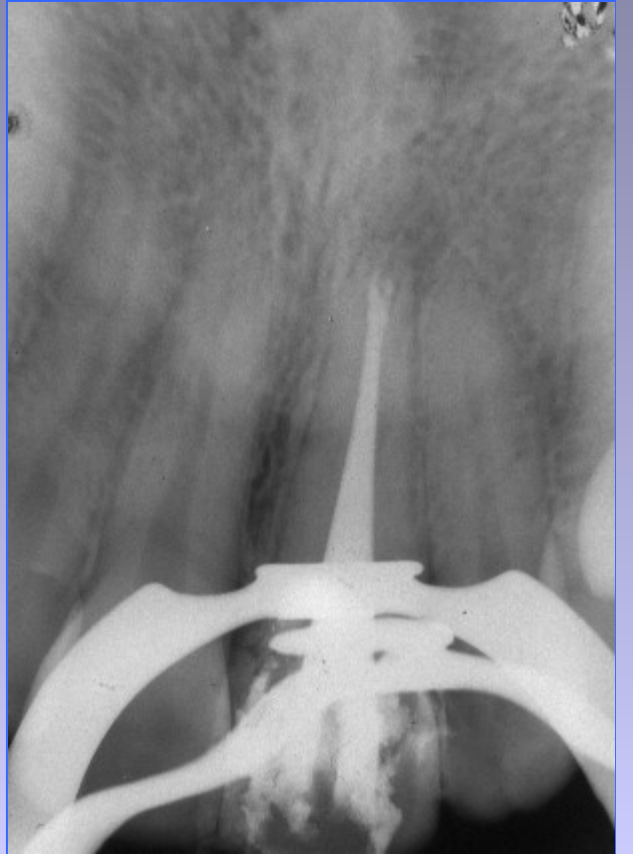
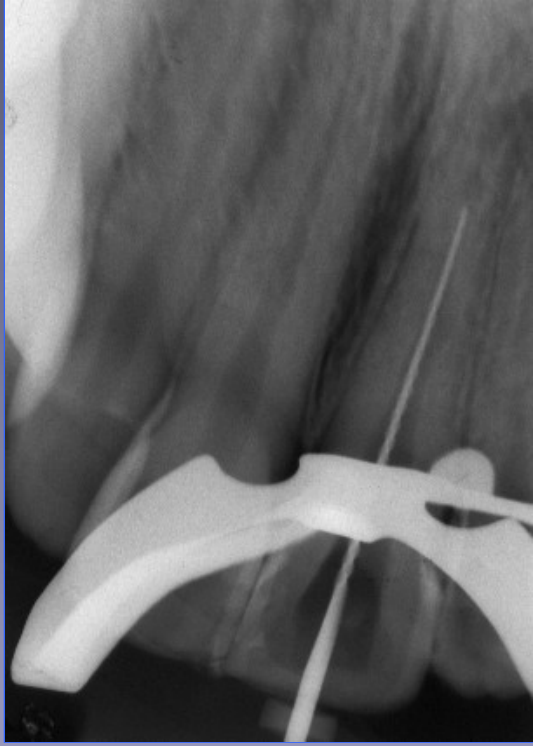
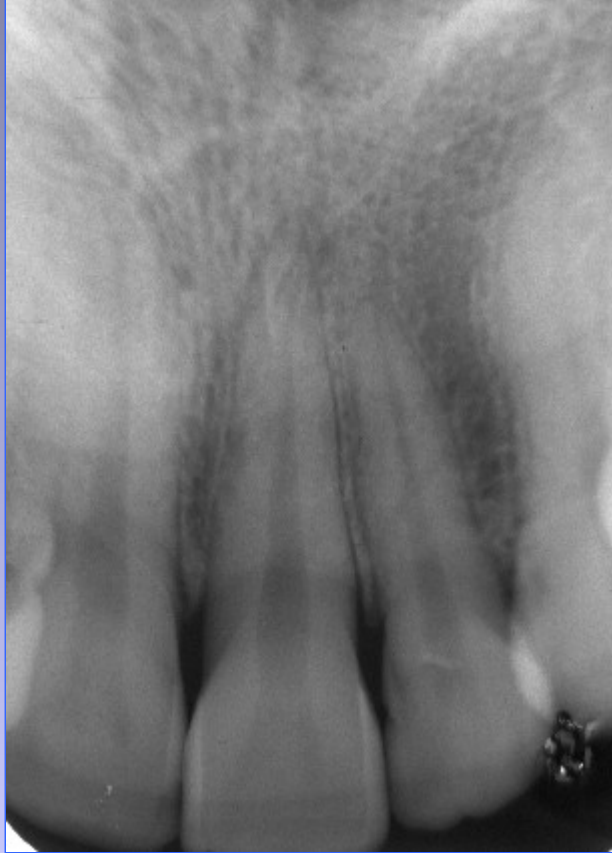




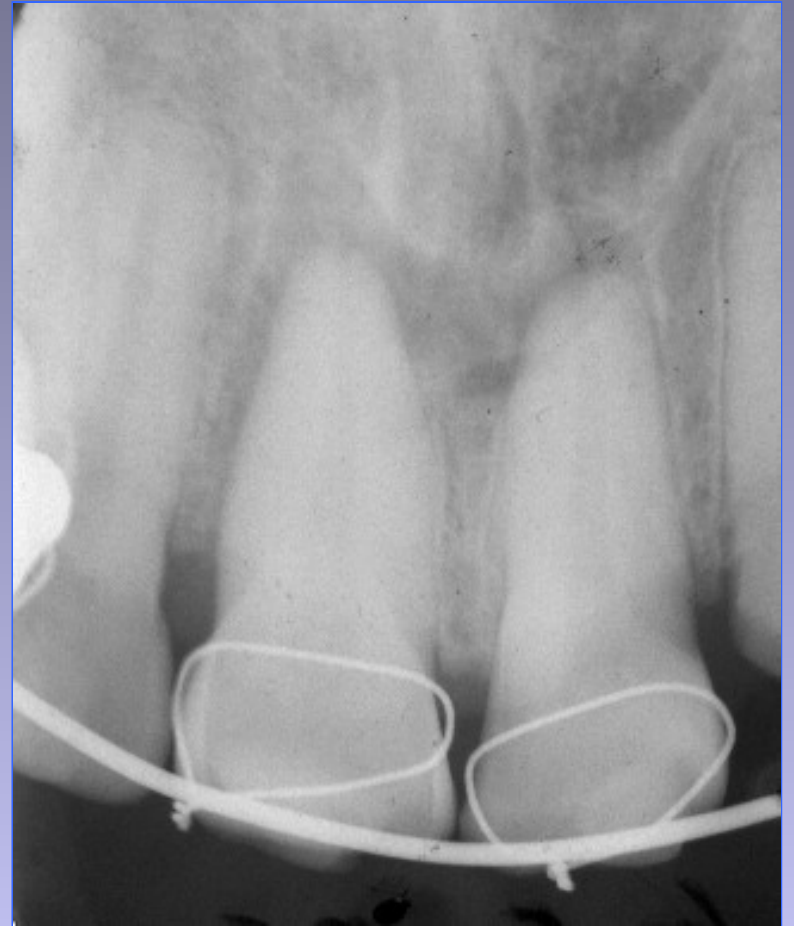
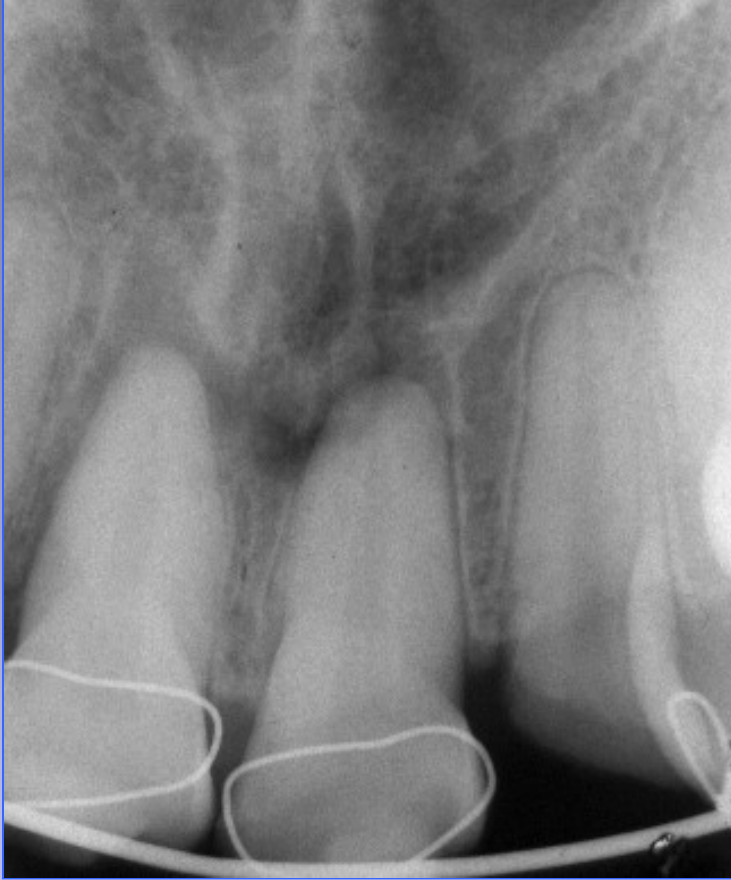




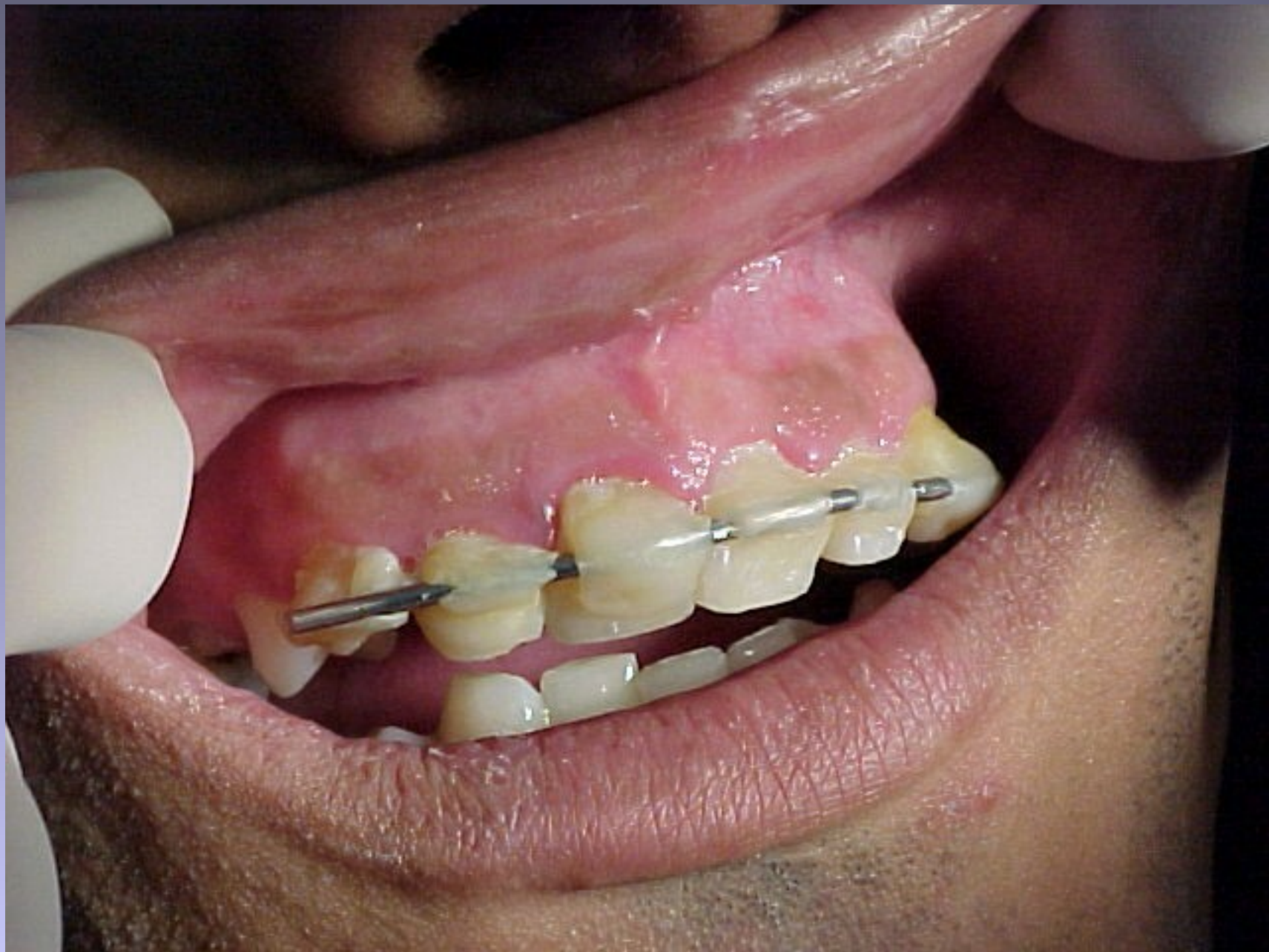

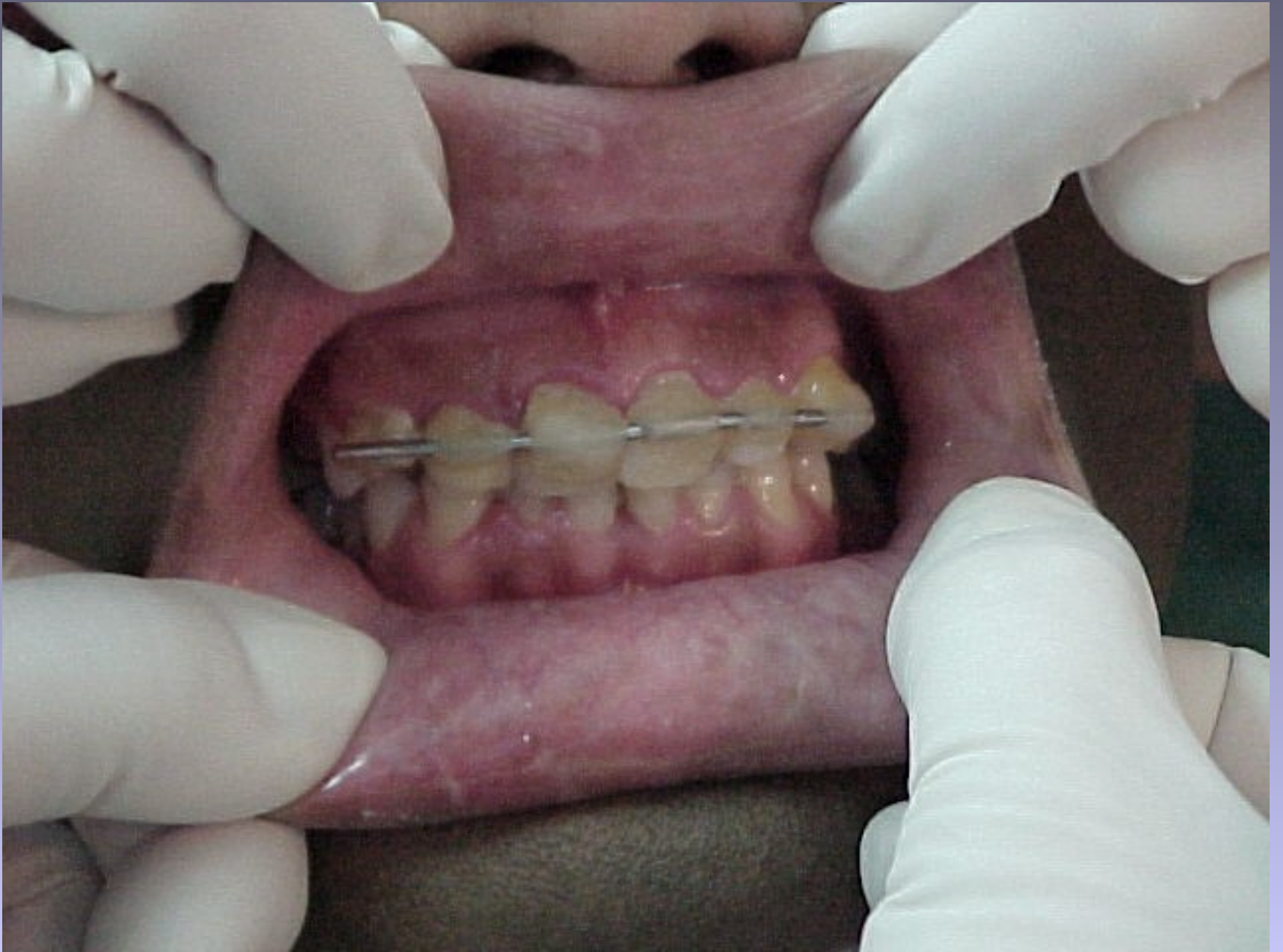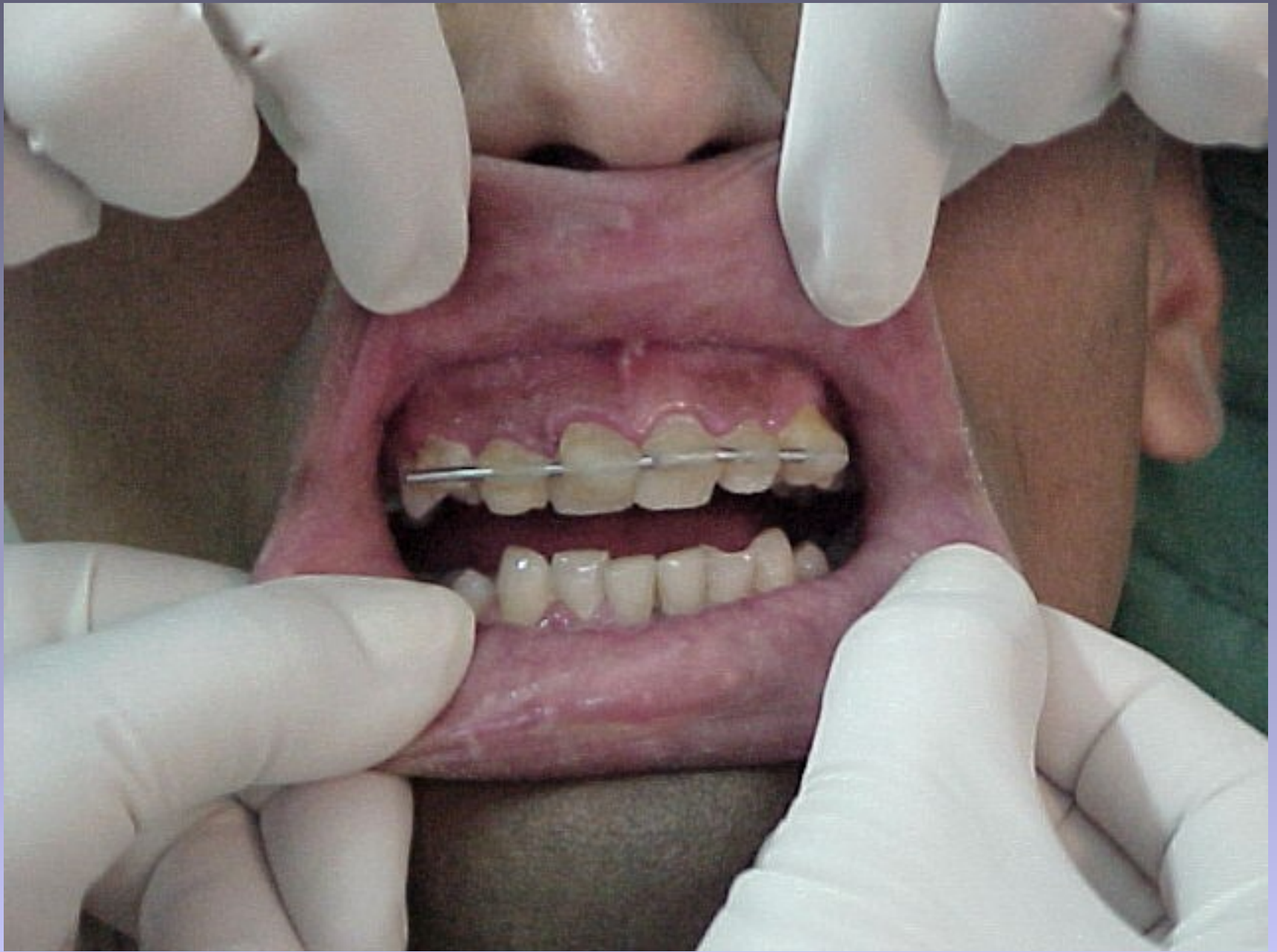Luxaciones protrusivas. Fractura de tabla externa. Férulas semi rígidas

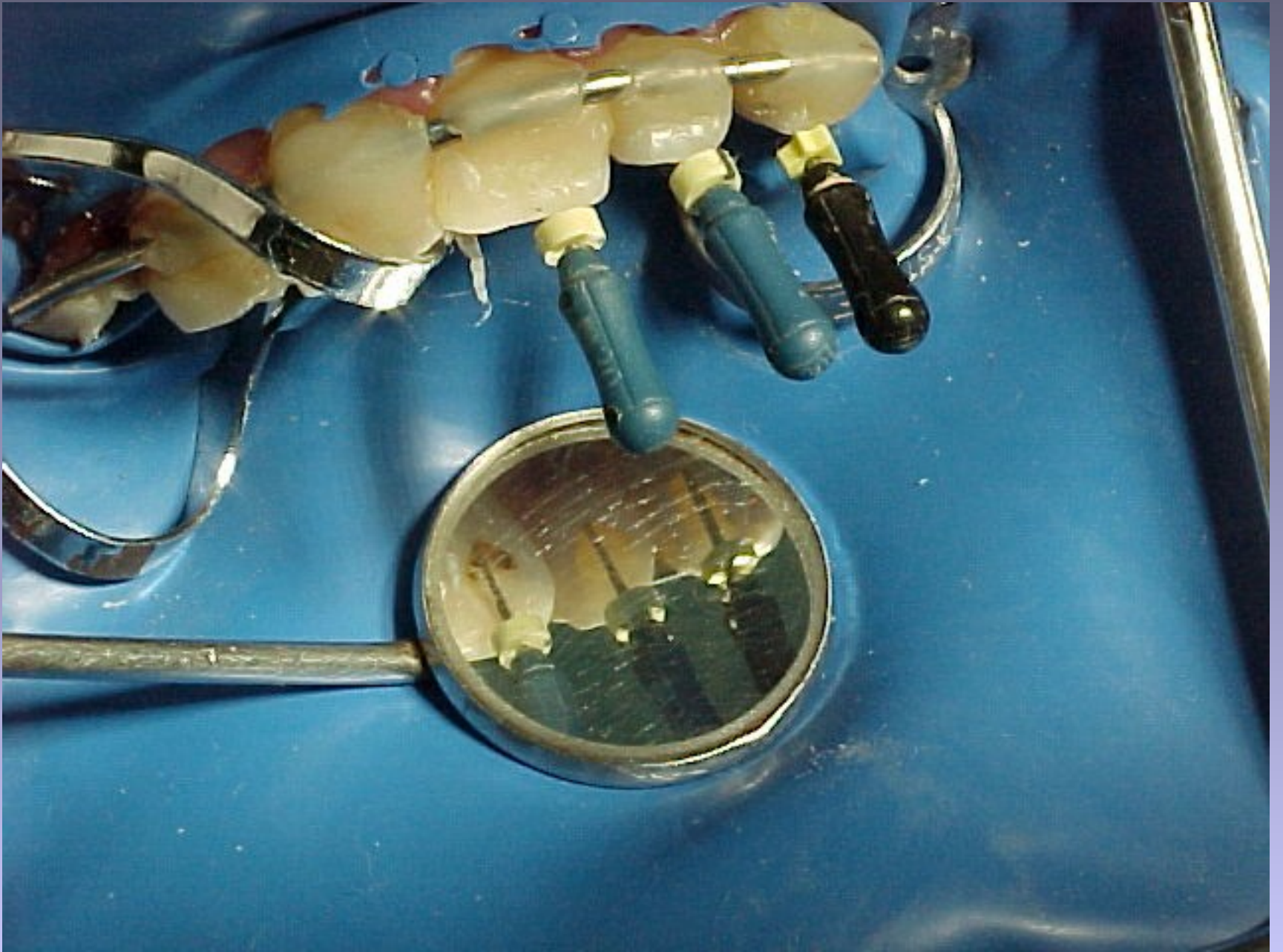


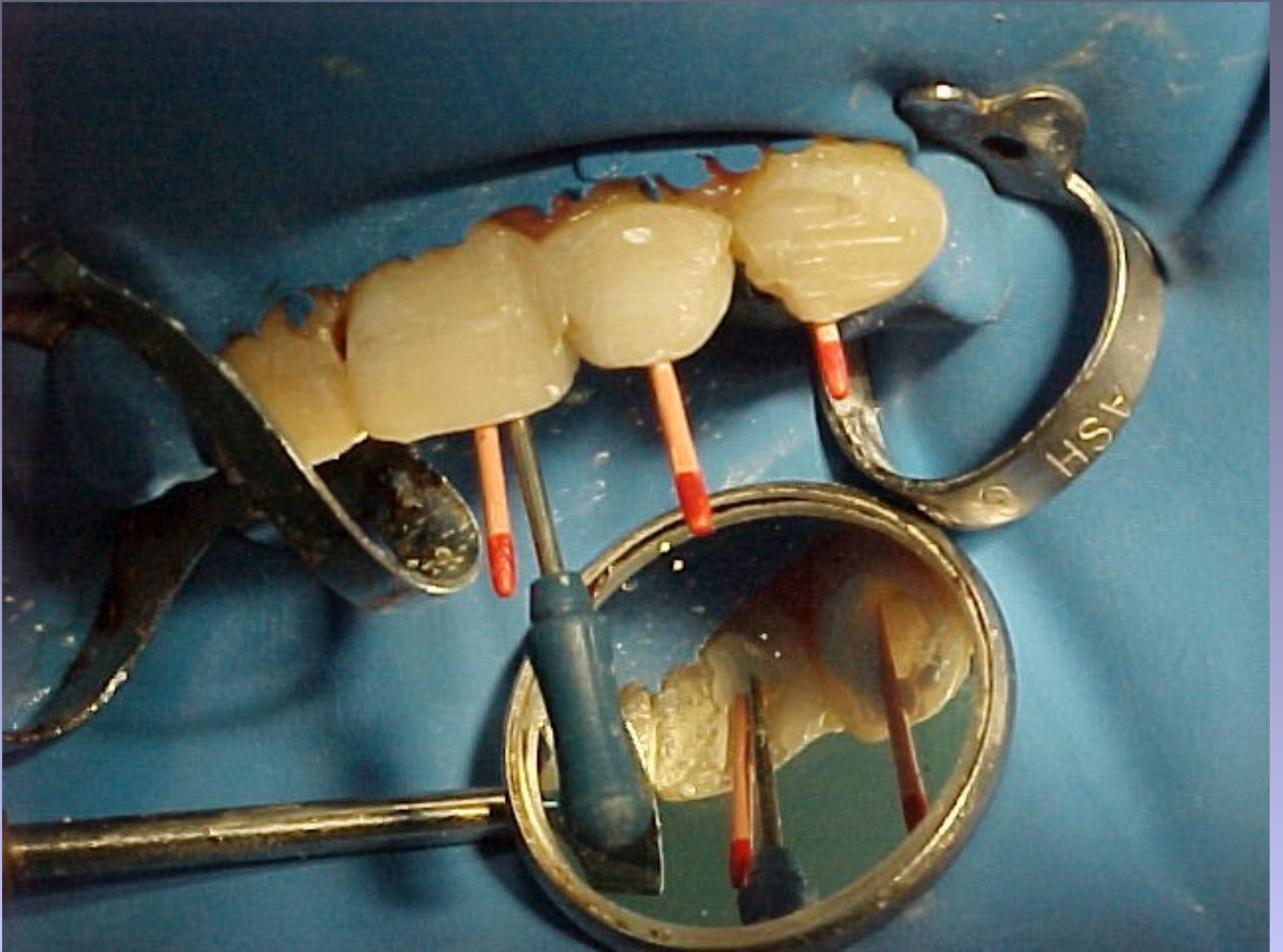Córdoba H.

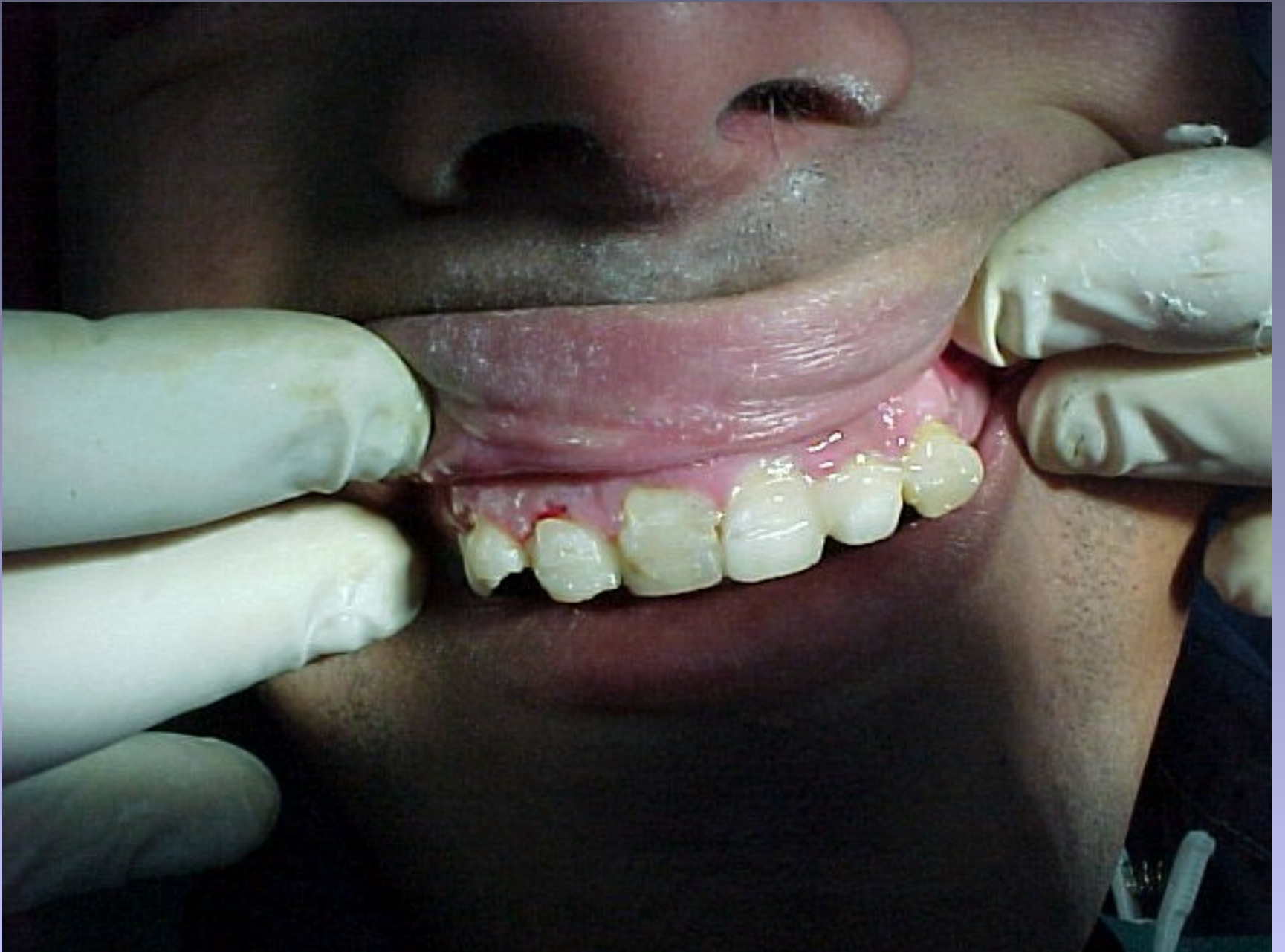

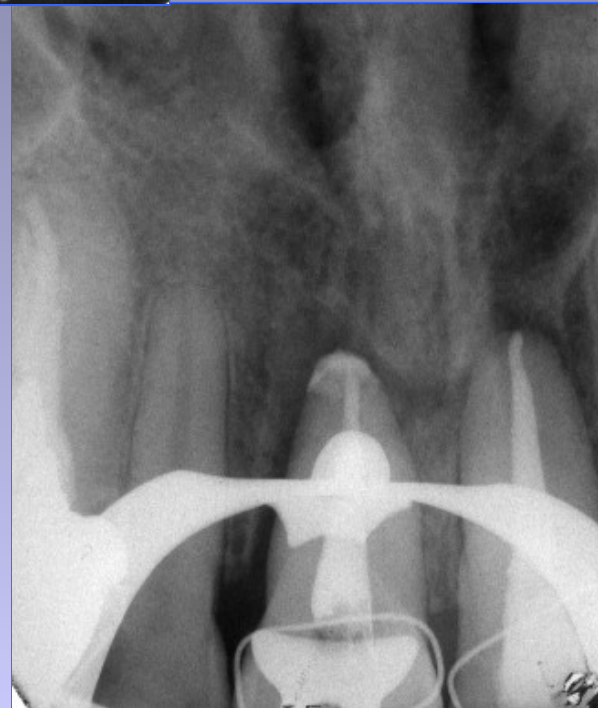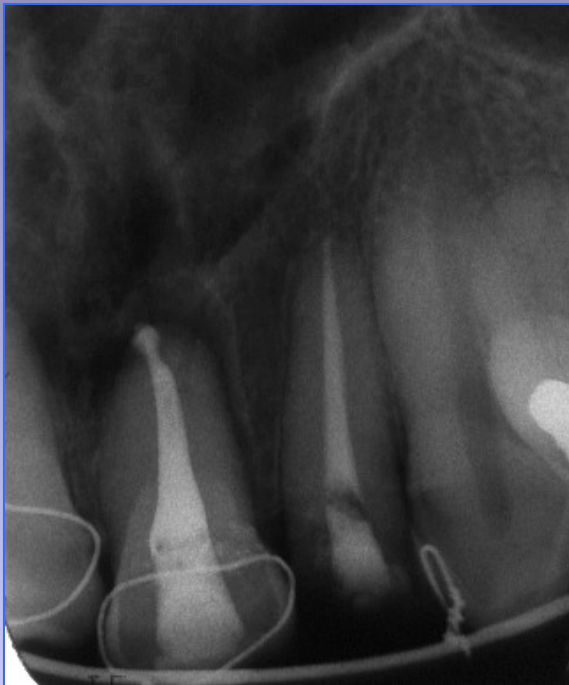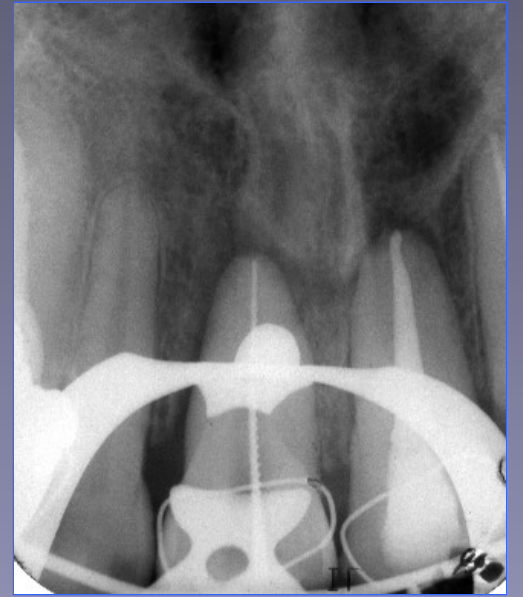
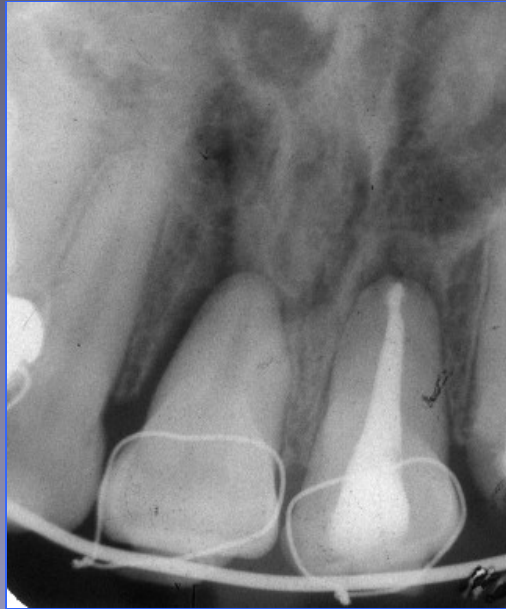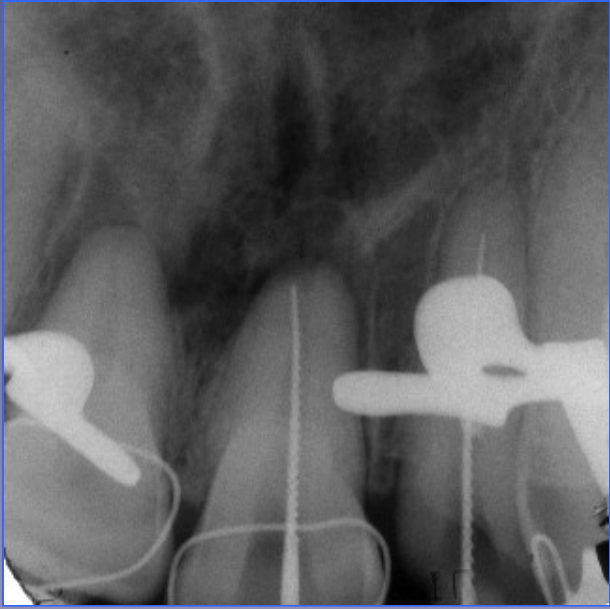






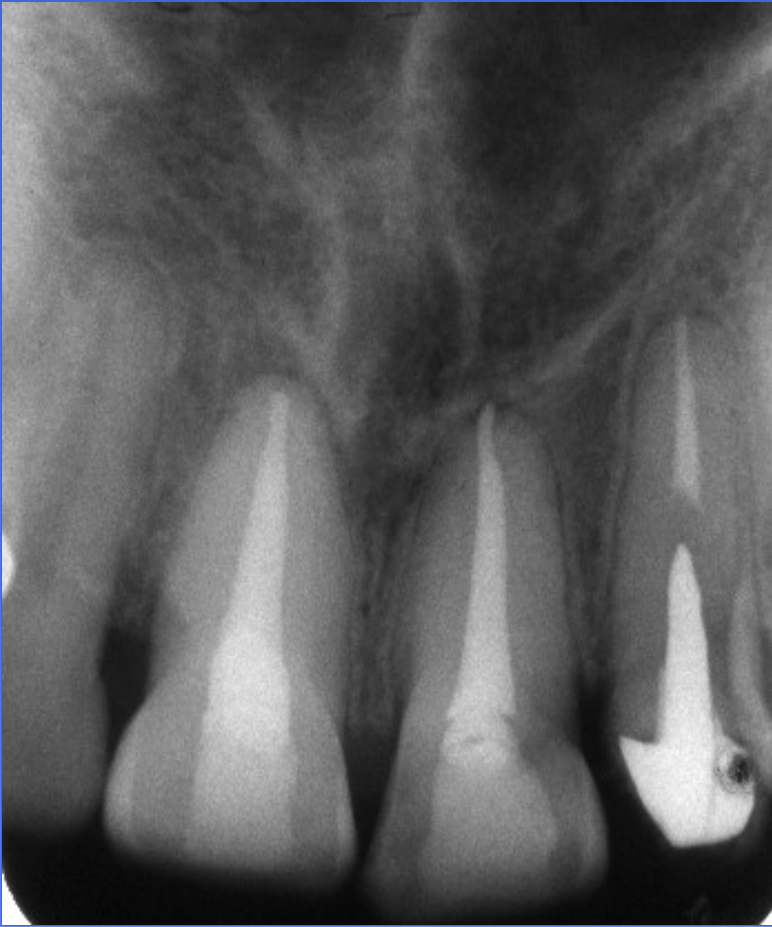




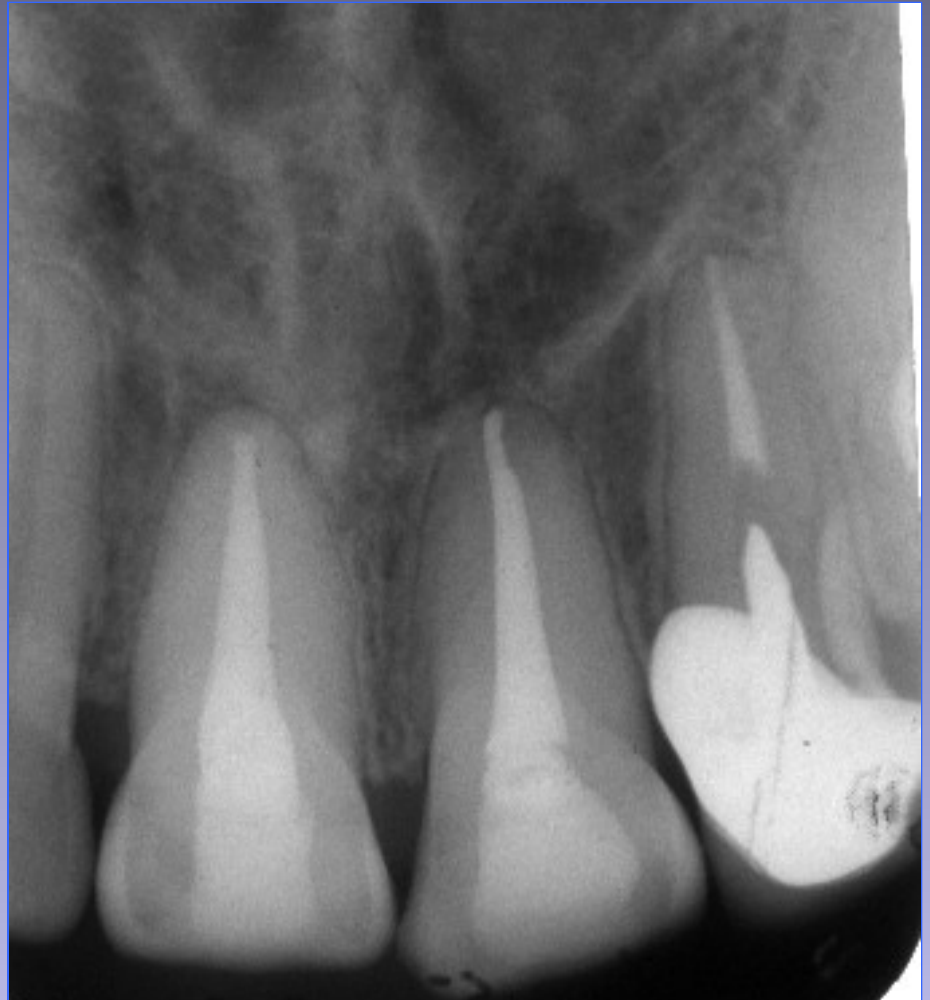


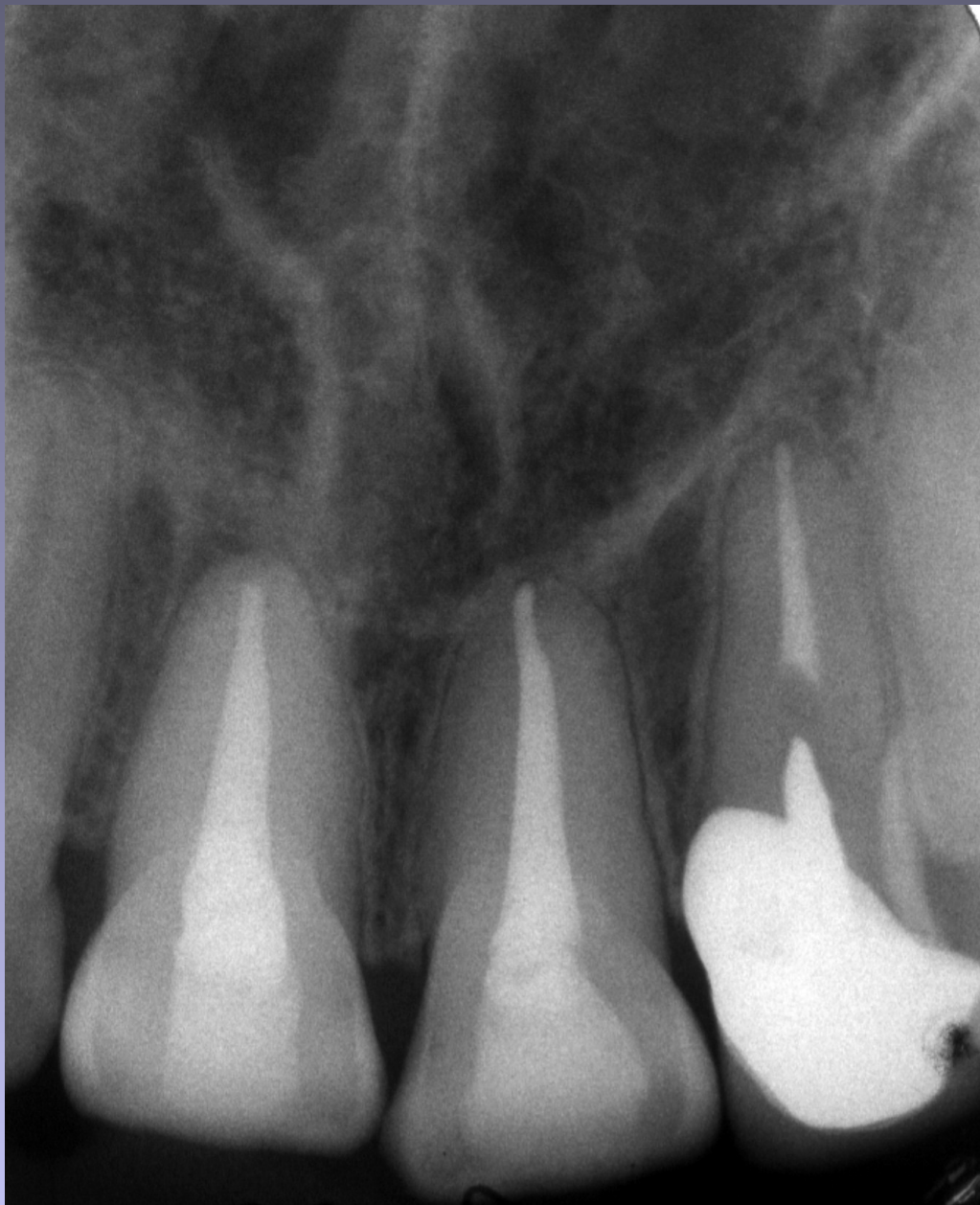Control 6 meses

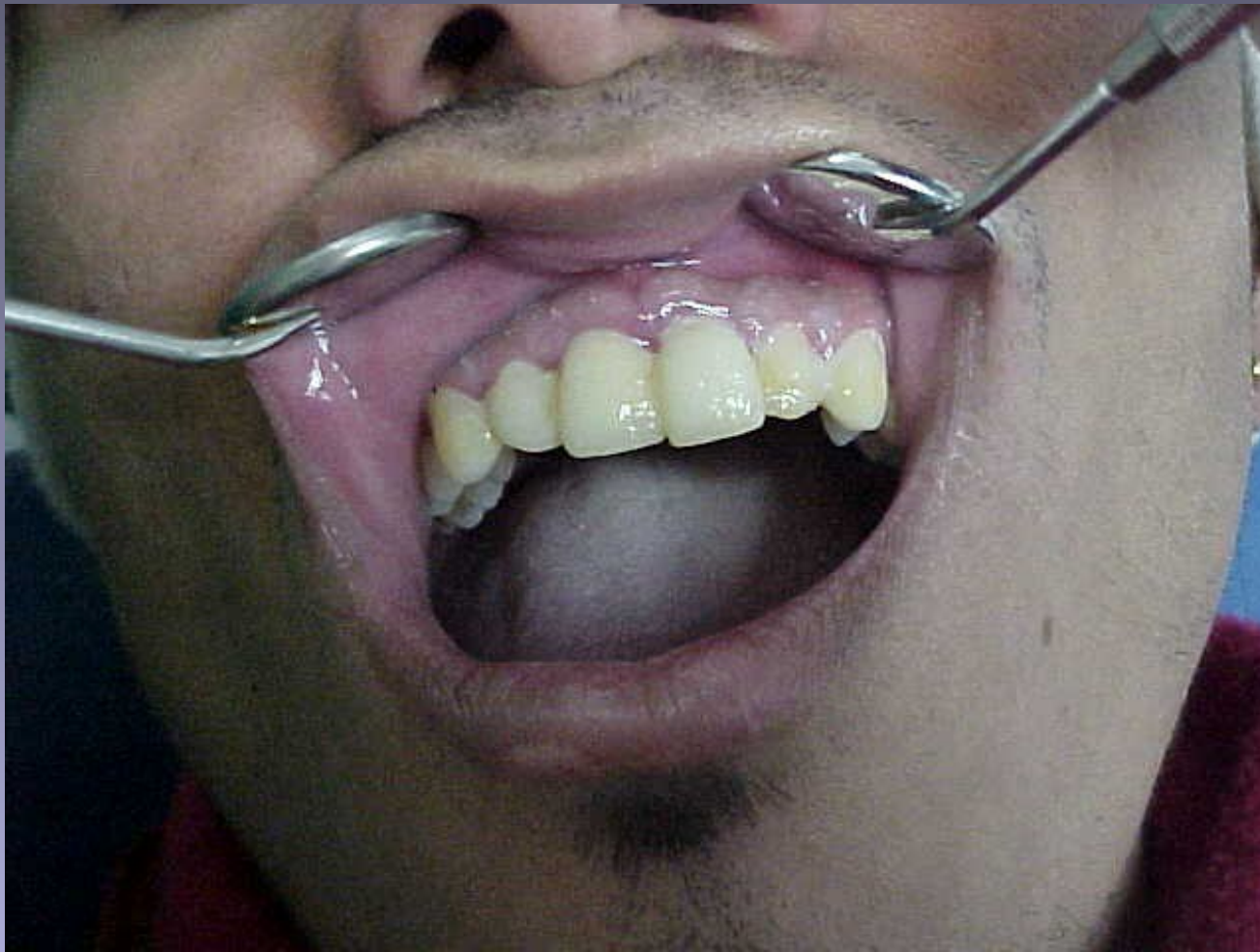

Control 2 años

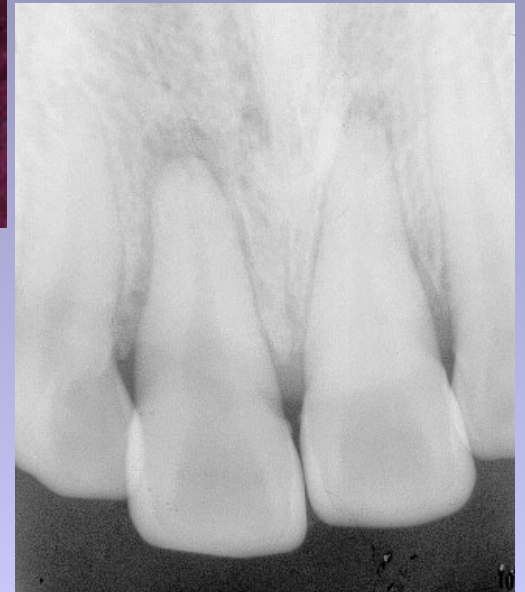

**Reparación de la
Fractura ósea**

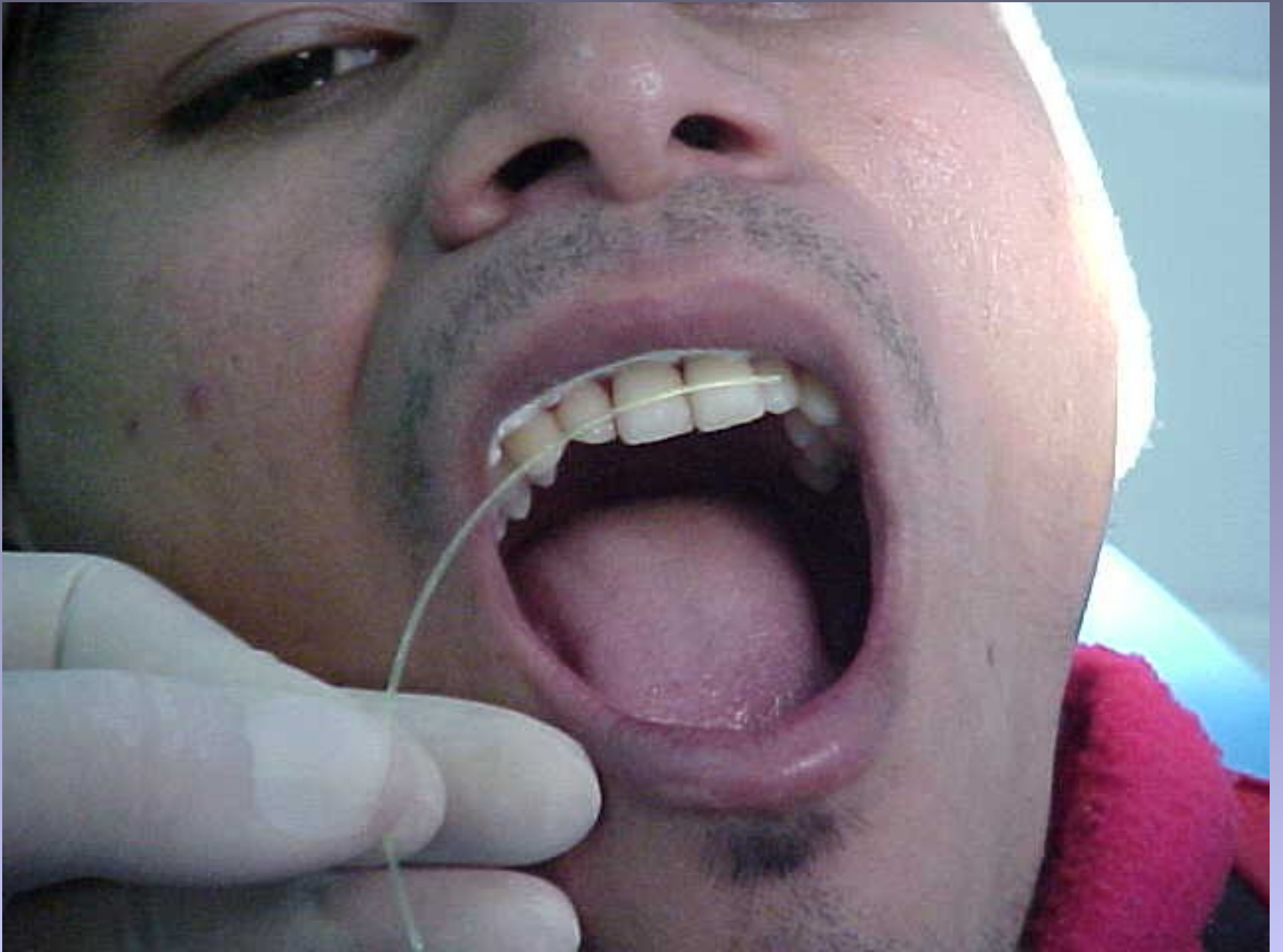**Reparación apical
Endodóntica.**

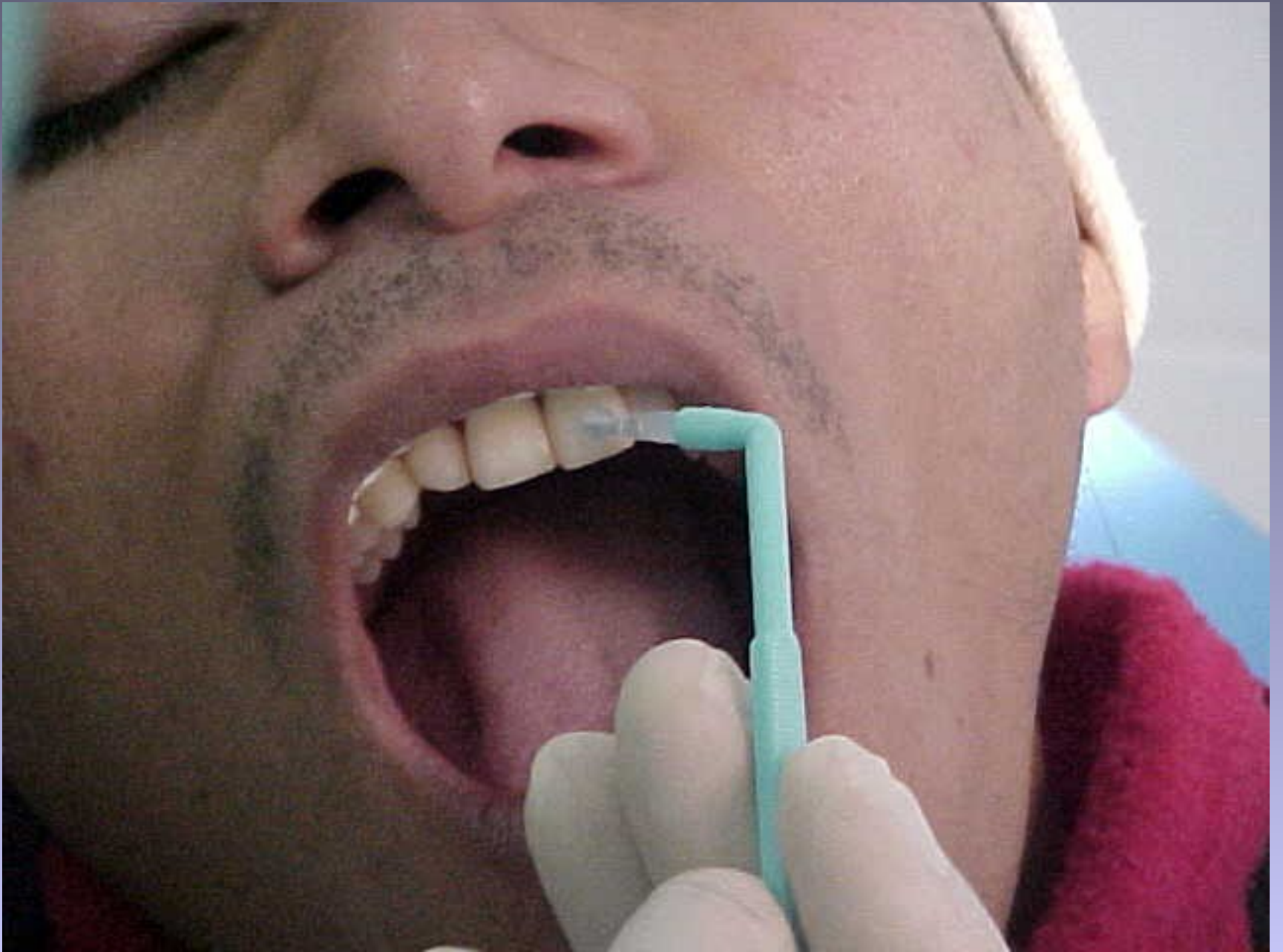

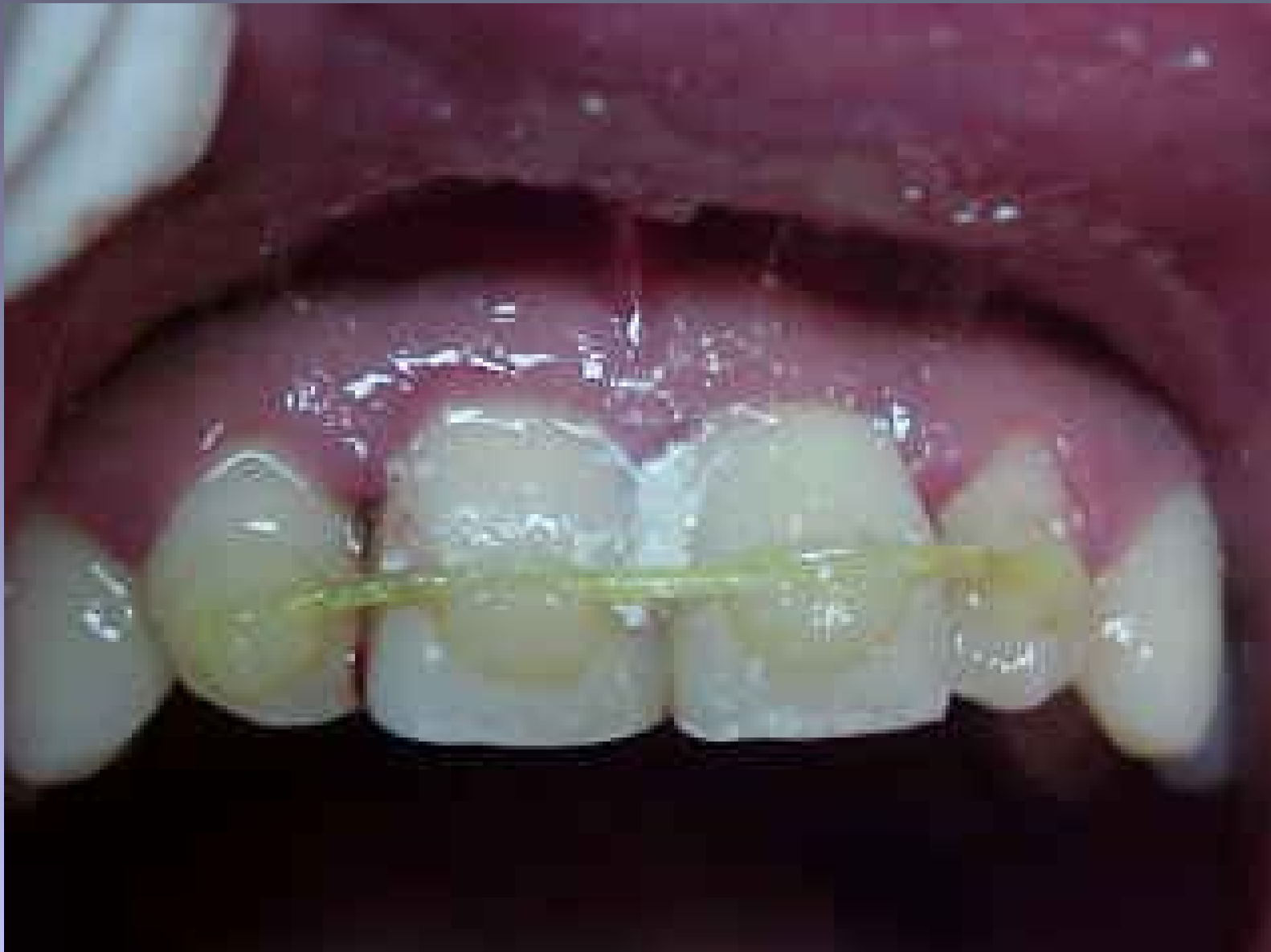Avulsión

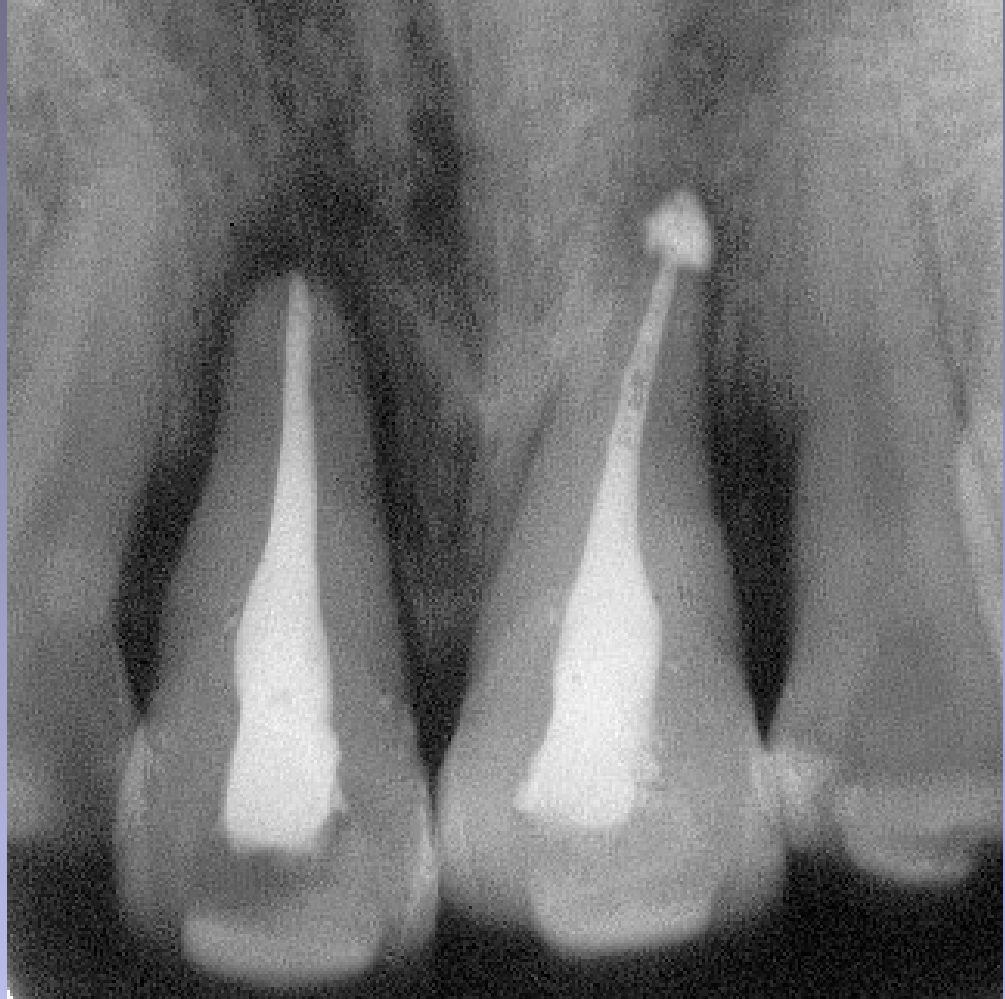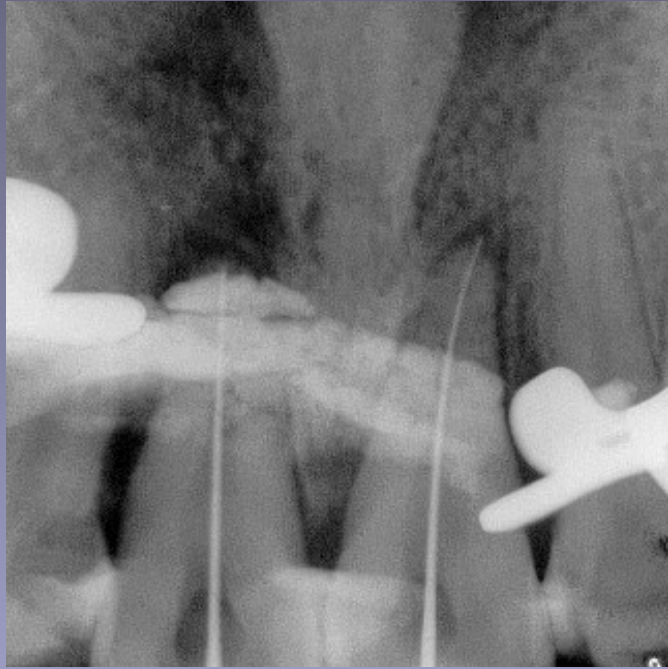


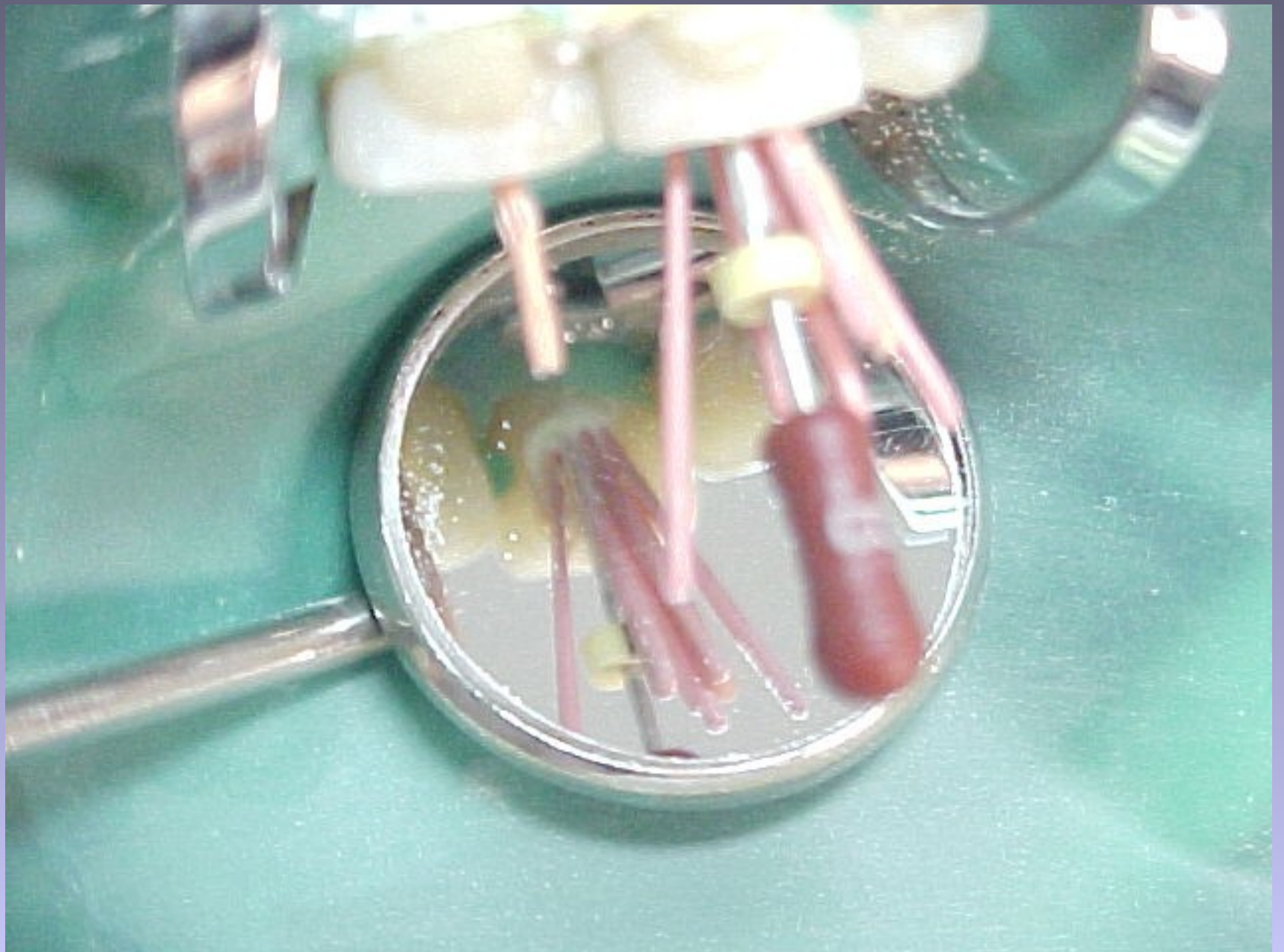



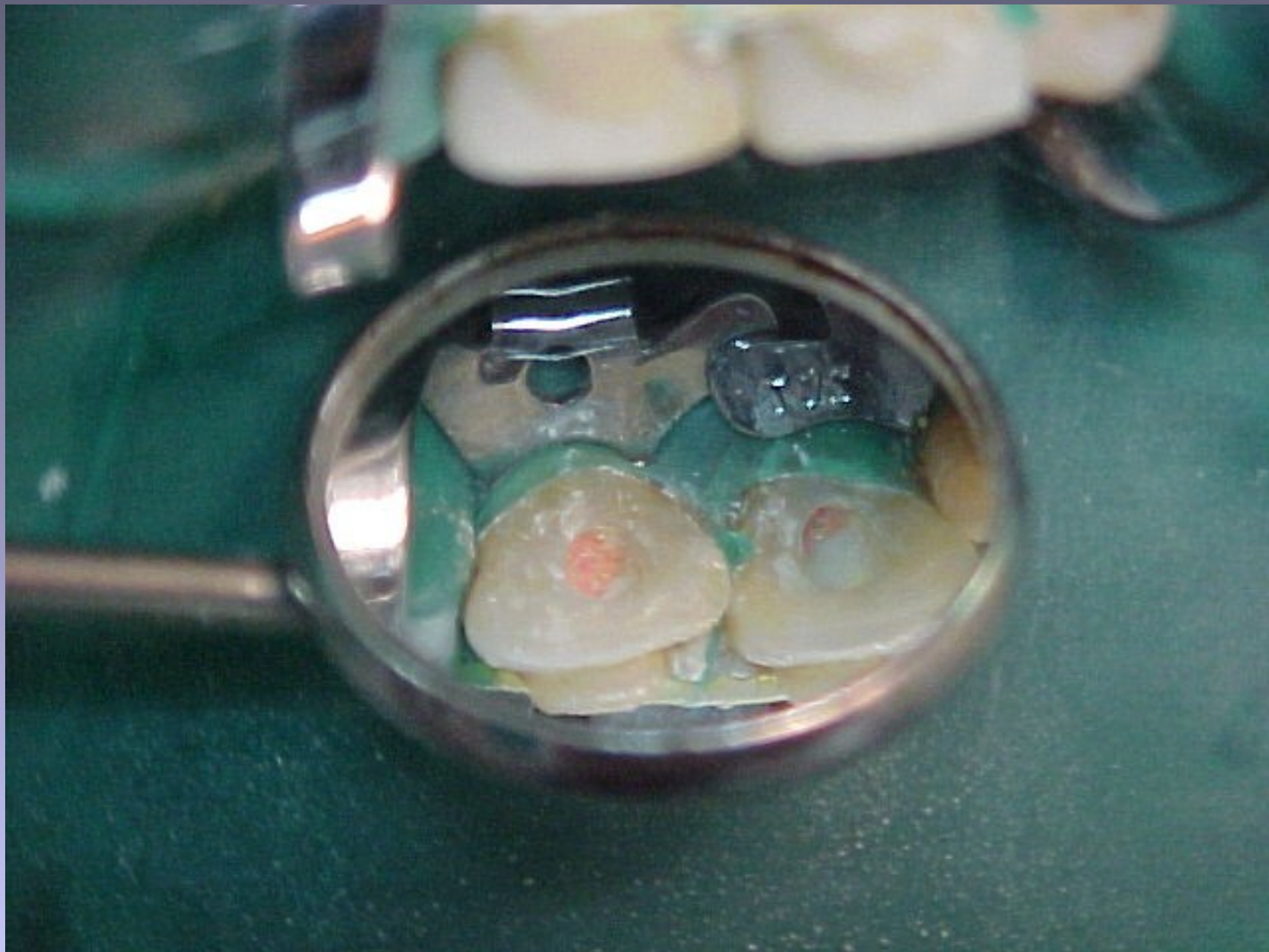


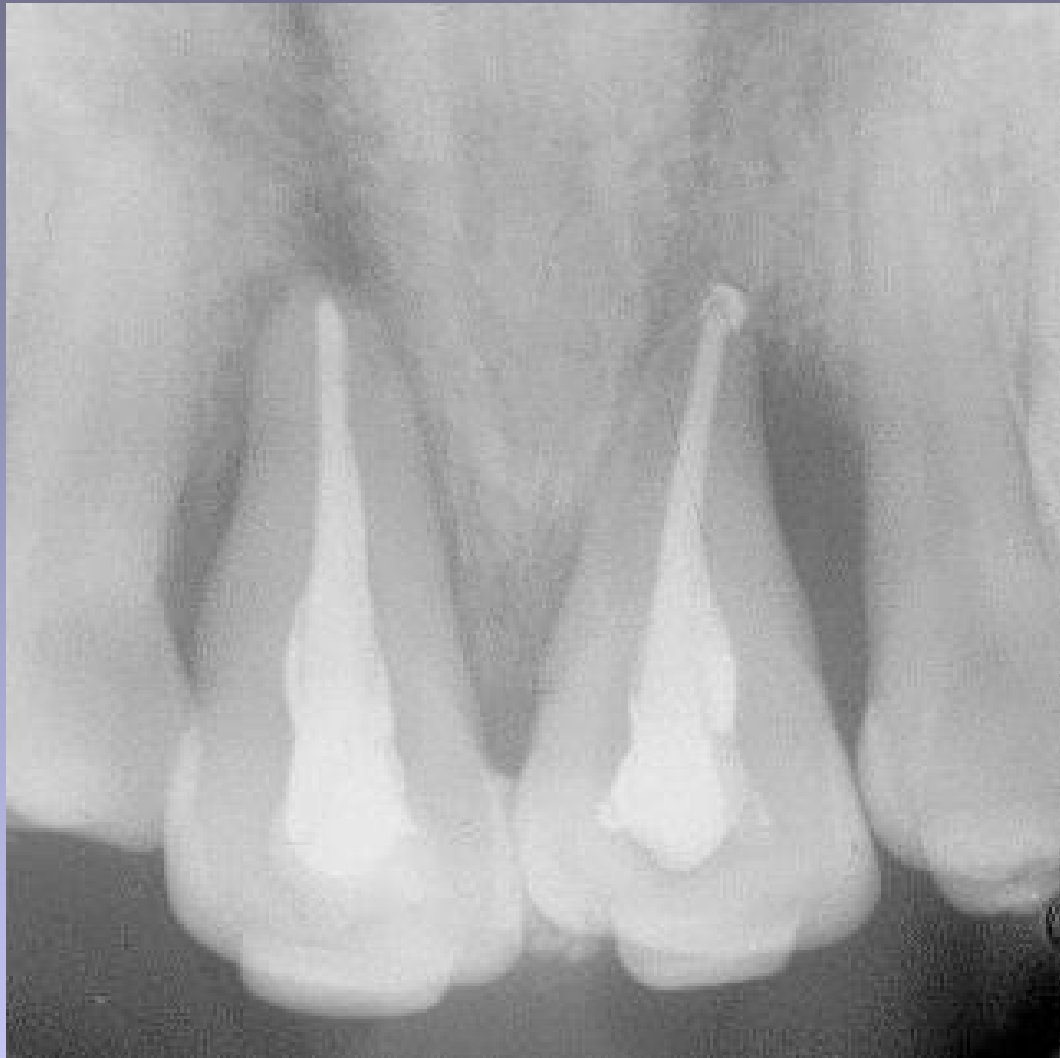




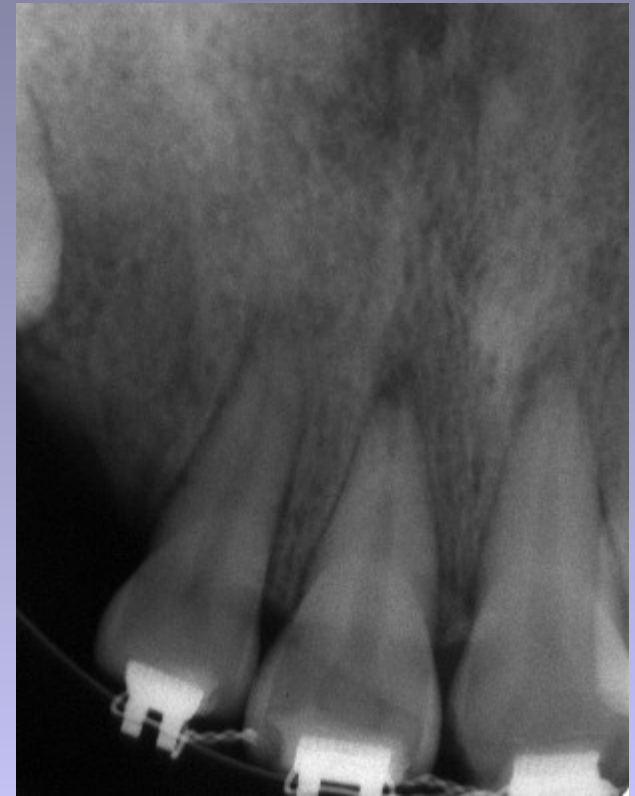
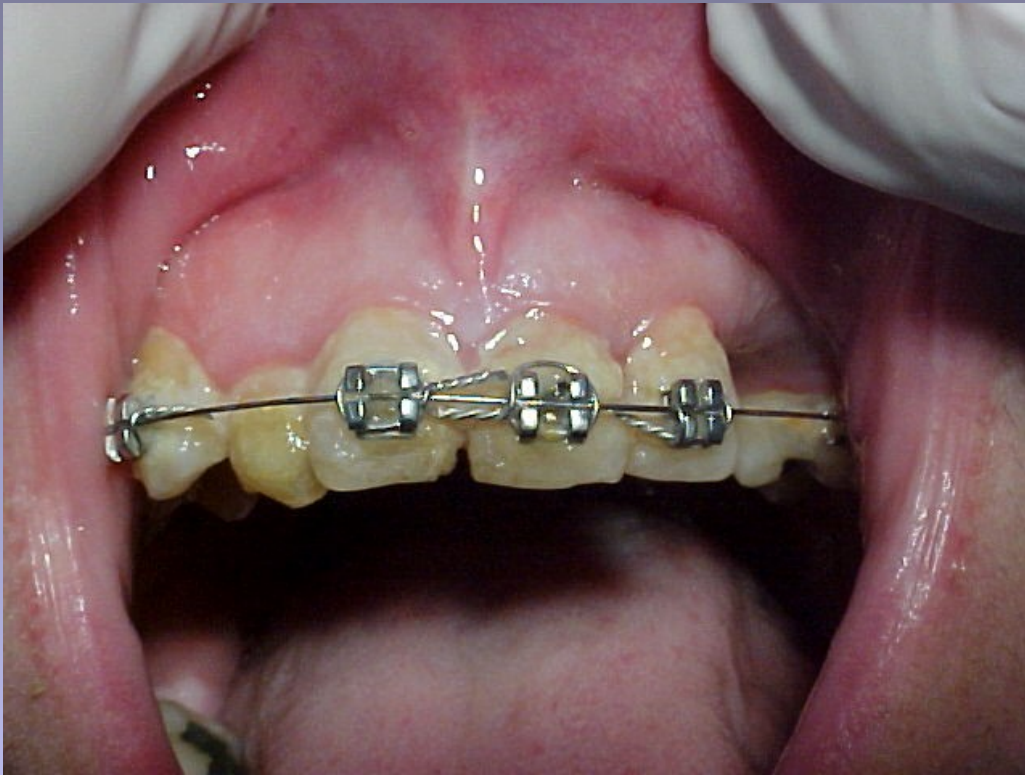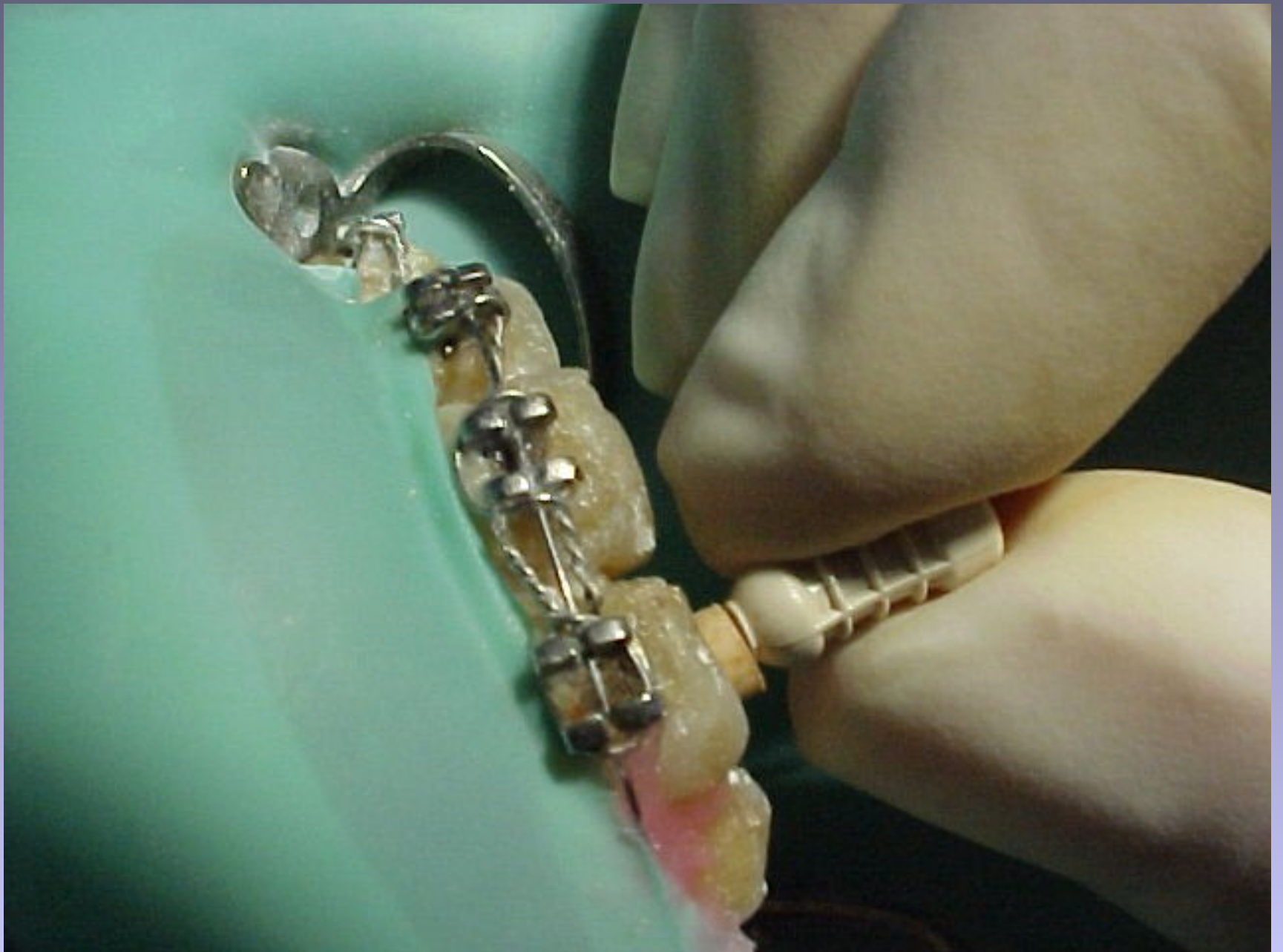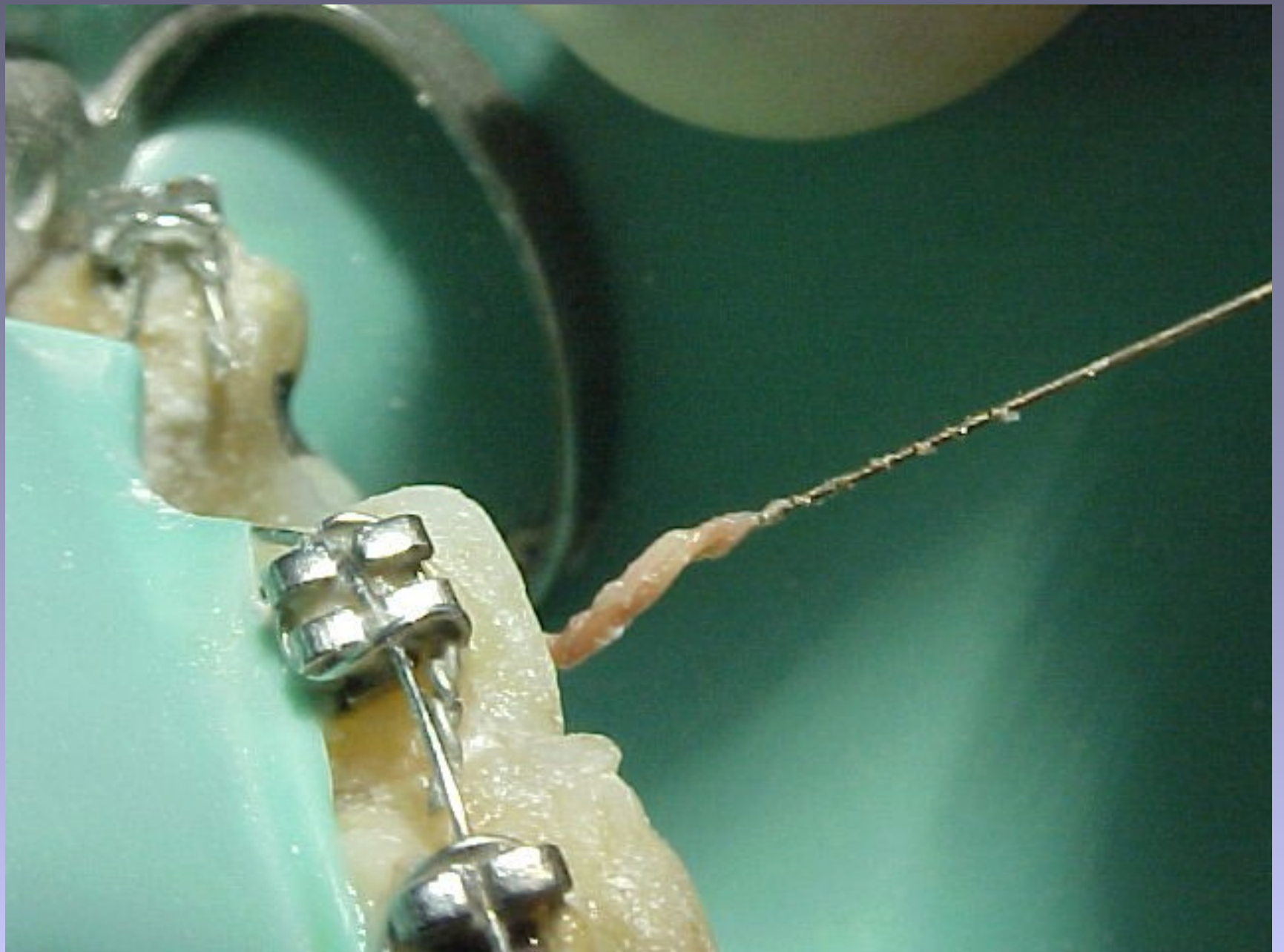


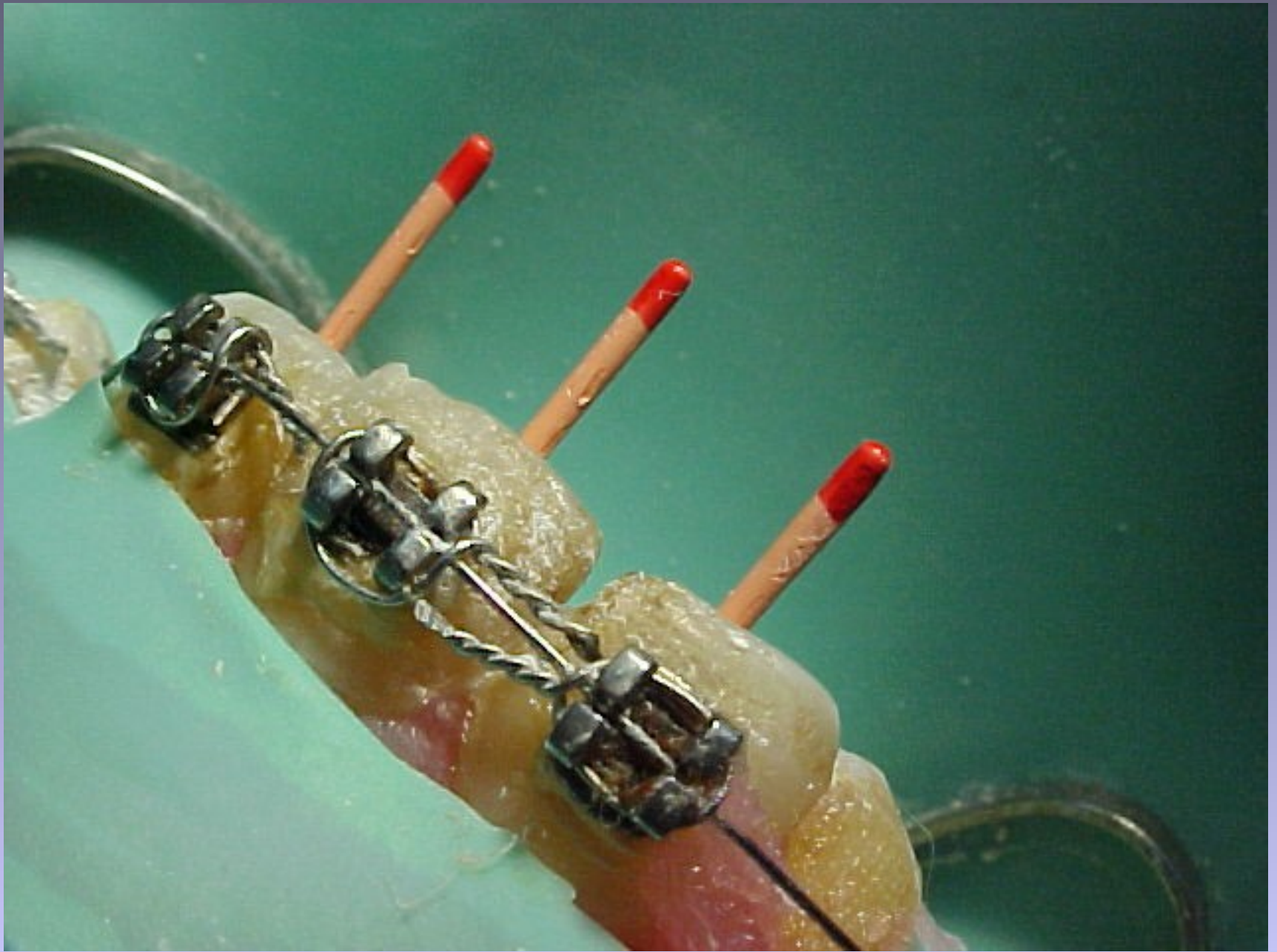


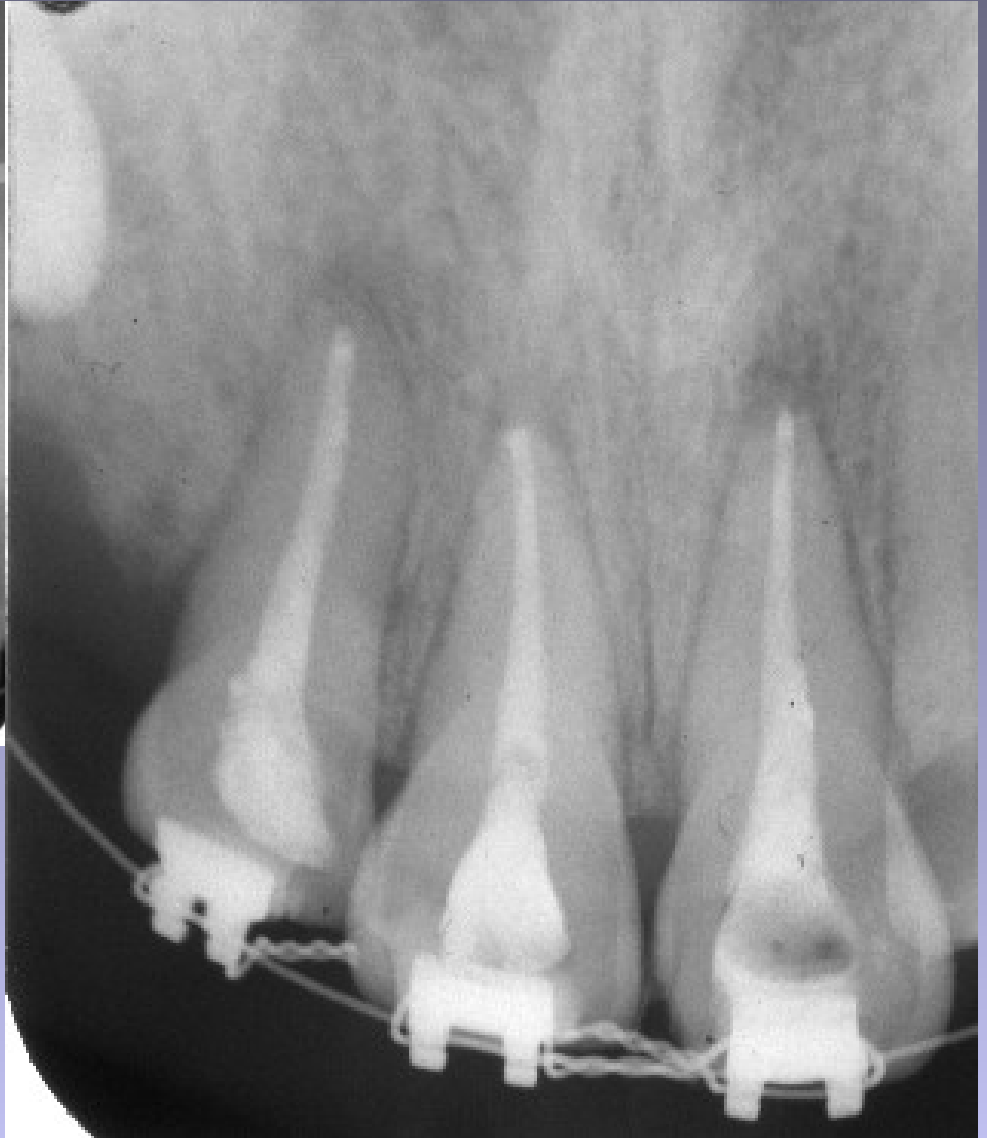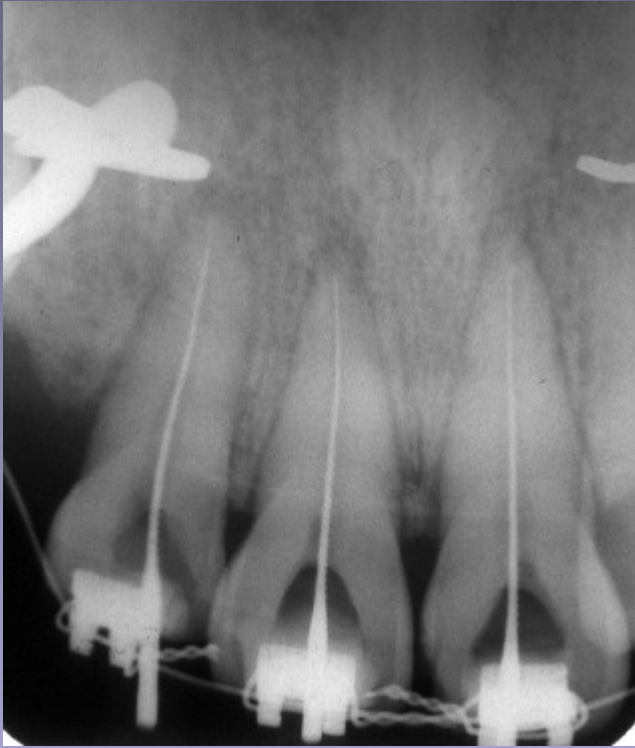Luxaciones

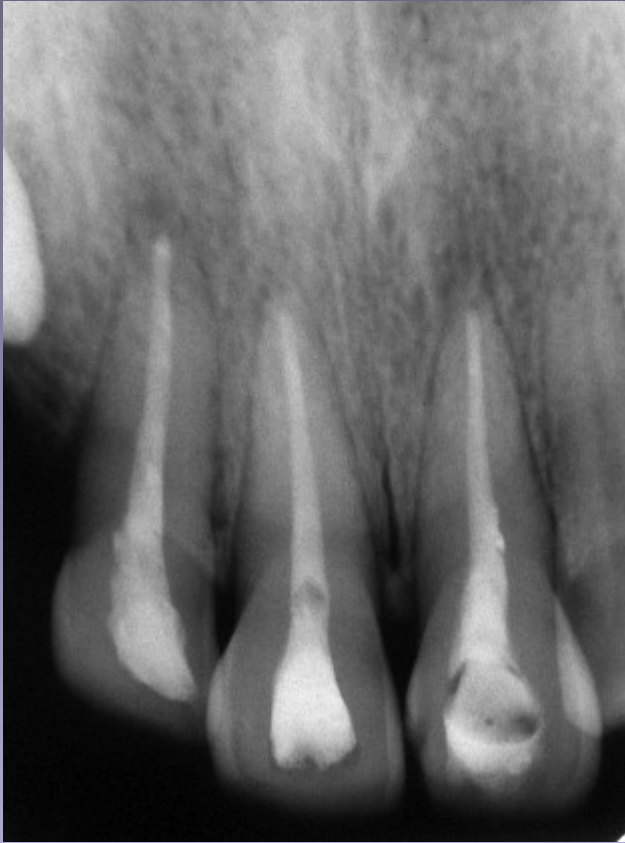




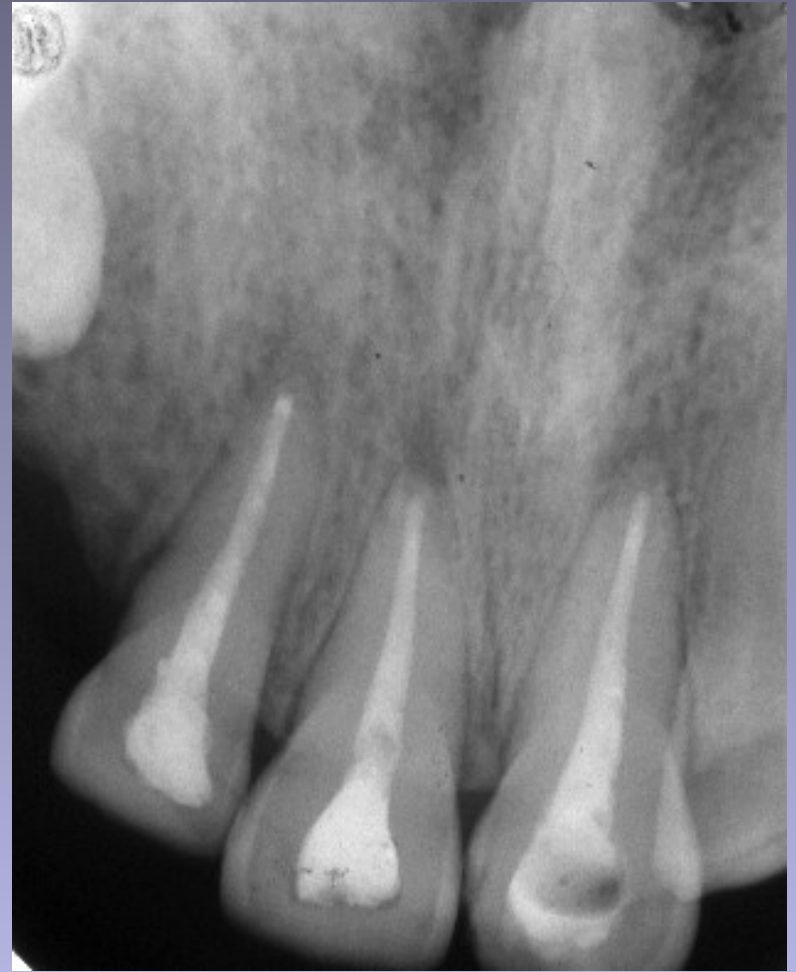






Control 4 meses



Control 7 meses