



Received: May 2012– Accepted: August 2012

Facultad de Odontología  
Universidad Nacional de Rosario

## Clinical Case

### Severe Coronary Fracture Complex Treatment

Karim del Valle Llahyah  
Ernesto Radica  
Domingo Radica  
Martha Siragusa

✉: [karlla@arnet.com.ar](mailto:karlla@arnet.com.ar)

## Desarrollo

A male patient of 9 years old arrives at the Guard Service of the Dentistry Faculty because a blow in the face had caused a fracture of the clinical crown of N° 21 tooth. He was given antibiotics and analgesics. He was referred to the specialty service so that professionals decide about the correct therapeutic treatment to follow.

The patient arrived by his own means and because he is a minor he was accompanied by a responsible adult. He had an edematous upper lip. His general systemic state was without any pre-existing pathologies. The patient reported that about 15 days ago he was hit in the face during a football game. The impact of the ball had caused him an almost a total crown fracture of tooth N° 21 with radicular involvement. Some surgical emergency procedures were practiced and then he was derivated to the Endodontic Specialty with the corresponding card with the patient data and the current history of the teeth involved. Partial pulp removal, calcium hydroxide application and reconstruction of the crown with composite had been done.

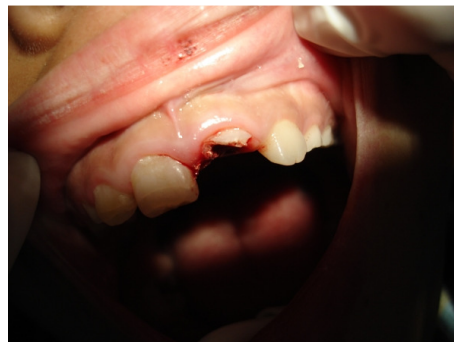

Photo 1

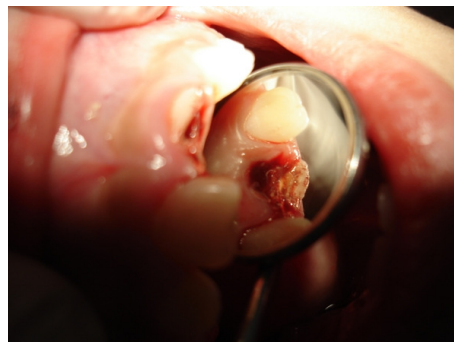

Photo 2

**Presumptive diagnosis:** root crown fracture with pulpal death process.

### **Extraoral inspection and examination:**

The upper lip had a slight injury just above the compromised piece with a small lump. He had no asymmetries on either side of the face. No adenopathy can be palpated on the neck; cutaneous fistulas were not observed either. Despite the concussion, at the time of inspection, there were no bruises on the face, but his expression showed discomfort and pain.

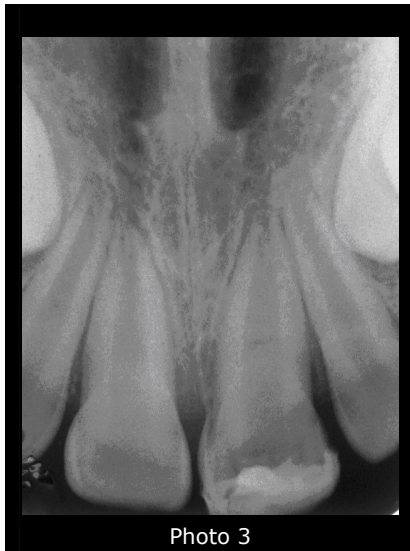### **Inspection and intraoral examination:**

- a) hard tissues. Dental plaque was widespread throughout the mouth. There was absence of N° 84 & 85 teeth and N° 16 & 26 show occlusal amalgam restorations properly sealed and without leaks. The No. 21 tooth had a plastic restoration totally mismatched.
- b) soft tissue. The DP 21 gum was swollen and edematous because of the blow suffered days earlier. He has the upper lip hurt and unremarkable cheeks, tongue and lower lip. It can be observed in the inserted gingival of both arches in the vestibular surface a light brown pigmentation of congenital type.

**Palpation:** As regards the vestibular and palatal zone that surrounded No21 tooth he shows pain. The alveolar ridge in that area has no bulges or crackles.

**Percussion:** this clinical method was not performed in order to avoid greater inconvenience. Beside, neither thermal nor transillumination or electrical tests were performed.

### **Diagnostic images:**



An analogue x-ray of the N° 21 tooth was taken, using the Long-cone technique. A widening of the periodontal ligament space, with incomplete apical maturation but close to be ended was observed. There were enlarged pulp chambers. Distally the alveolar ridge seems to be quite diffuse. The fracture cannot be noticed radiographically, but, mesially there is a radiolucent area, up to the third and a half cervical of the root, as a shift of the alveolar cortical, which looks discontinuous, and the ligament space widened mesially and centrally. Apical root reaching its maturation. N°11 tooth was also taking into account, and it was kept under observation to see how it reacts in apical because it can also might have suffered rupture of the neurovascular bundle due to the proximity to the tooth to be treated.

**Definitive diagnosis:** Complex crown fracture and root crown fracture with pulpal death contaminated by severe trauma.

Most dental injuries occur in the age group between 7 and 10 years old due to falls, home or school accidents. They occur mainly in the anterior region of the mouth, affecting more the maxillary arch than the jaw.

These fractures are oblique and affect crown and root. The anterior teeth show the so-called CHISEL fracture type which diagonally separated the crown and extends in a subgingival level to the root surface. They look like a crown fracture, but they are more extensive and serious because they include the root and the pulp.

An important aspect of the crown-root fractures test is the removal of all fragments before the treatment plan.

Crown root trauma is more a periodontal than an endodontic challenge. Root elongation must be achieved in order to get a good seal in crown restoration.

**Work Protocol:** Root canal treatment referred to periodontics and orthodontics specialty, to obtain a clinical crown lengthening maintaining healthy gum tissue and then performing the appropriate rehabilitation.

**Signed consent:** because the patient is a minor, the treatment to be done is explained to his mother, who accompanied him. She was also told about the importance of monitoring and remote control of the child and her responsibility to accompany and assist him. It was made it clear that the treatment may have complications or failures, and that the treatment success depends largely on the child's biological response. The adult is compromised to attend the controls when necessary or when the professionals considered so. Furthermore she is made responsible for carrying out the restoration after treatment. She signs agreeing with all the above.

**Analgesia:** subperiosteal infiltration analgesia was performed in vestibular groove depth at No. 21 tooth level. It was done with Lidocaine Hydrochloride 2% and Epinephrine 1:50000

**Removal of broken dental elements:** Carefully, with cotton tweezers, the coronary remaining with debris of composite restoration was removed and gently, a small portion of the palatal root was also removed. A cotton swab in complete septic state was removed from the duct.

**Isolation of the operative field:** relative isolation of the operative field with cotton rolls through vestibular was made as it was considered the advisable procedure due to preserve gums of more laceration or damage the fracture support tissues. The patient was given a saliva ejector for his comfort.

**Cameral Opening:** because of the accident the camera was already exposed and the conduct in plain sight, only the minimum necessary to remove sharp or square edges with cooled turbine and extra-long conical stone was done.

**Irrigation-aspiration:** in order to initiate the intra-canal operative maneuvers, it was performed, firstly, a profuse irrigation with plenty of hydrogen peroxide (10 volumes), so as to decontaminate as much as possible the canal input, and to aspirate to remove all the contaminated material. It was not irrigated with hypochlorite because without absolute isolation, soft tissue necrosis can be caused and it may, also, accidentally fall into the oral cavity and be swallowed.

**Pulp removal:** gently, the pulp tissue was attempted to be putting together with a broach, introducing the instrument until a slight resistance was felt, it was withdrew one or two millimeters and two or three clockwise turns were made. It was pulled so that it could engage and remove out the dental pulp.

As seen in the picture, dental pulp was exposed to ischemia with its stromal cohesion with congestion and in its initial step of decomposition pathways.

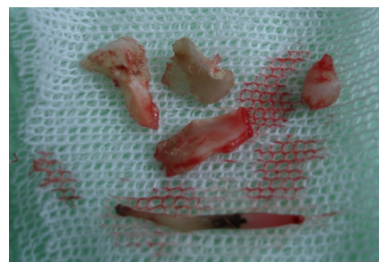

Photo 4

**Irrigation-aspiration:** Irrigation with lime water was performed in the canal (because the tooth has not quite reached apical maturity and irrigation with hypochlorite may cause its transfer to the periapex leading to necrosis, hard tissues inflammation and infection and much pain).

Lime water is prepared by saturating calcium hydroxide powder with distilled water and leaving it to settle. In this way it can be taken to the canal with a syringe and irrigate. Calcium hydroxide has antiseptic and antimicrobial properties because it is highly alkaline.

**Registration of the work length or conductometry:** The work length was recorded by the tactile method also called CDC limit.

A smooth size 80 K-file of 21 mm was selected and introduced slowly into the canal with reciprocating movement, reaching a length of 18 mm. There the reference was established on the remaining vestibular incisal edge with rubber stops placed on the file.

Then, an orthoradial X-ray was taken to corroborate the work length; it was revealed and determined that it was correct. So the work length was established at 18 mm of the remaining coronary-vestibular edge.

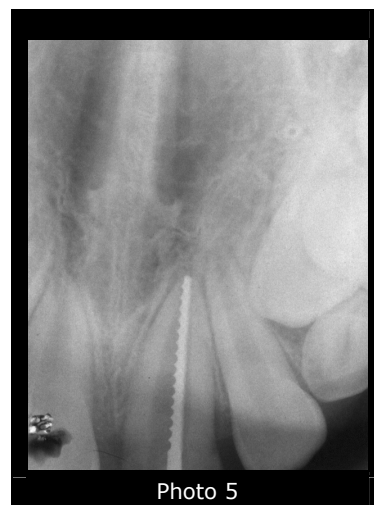


Photo 5

**Surgical preparation:** This procedure removes the organic content of the root canal and the carving of a matrix to hold the obstruction mass is achieved. After the cleaning of the conduit with the previous manoeuvres the carved of the conduit at the apical level was done, giving retention shape and resistance to confine the final filling material inside the conduit and of convenience or gradual conicity to facilitate the seal. In this particular case the only instrument used in apical was the smooth file N° 80, which remained as memory file (last tool used to carve the apical matrix). In this case it coincided with the file used in the conductometry. Then the length was reduced to 3mm, ie the end stop was adjusted to 15 mm of the reference and a smooth and very carefully perimeter filing was made, without excessive pressure to avoid further damage to the support apparatus of the piece. Thus a good way of convenience was obtain. The irrigations with lime water were repeated and finally it was rinsed with saline and the canal was dried with N° 80 sterile paper coins.

**Final shutter:** the final shutter was decided in the same session to avoid recontamination of the canal for possible leaks.

This surgery maneuver aims to replace the contents of the conduit by a permanent, waterproof and good tridimensional compaction material

Gutta-percha cones were used: principal cone No. 80 and accessory cones. The gutta-percha is the dried juice of the Isonandra Gutta tree. Exist in nature as 1,4-polyisoprene and is harder, more brittle and less elastic than natural rubber. There are two crystalline forms: Alpha and Beta. The alpha form is naturally obtained from the tree. Once processed it is known as Beta, which is used for filling root canals. Current cones are composed of approximately 20% gutta-percha, 65% zinc oxide, 10% radiopaque substances such as salts of heavy metals and 5% plasticizers or resins. The gutta-percha has an excellent property which is its ability to deform to a lateral pressure on the rigid walls of the conduit, this property allowed to use a cold lateral condensation technic. At the same time it needs to adhere to the dentin walls an agent or cement sealer. SEALAPEX: Calcium Hydroxide- Based Root Canal Sealer cement. The package presents two tubes containing the base and the catalyst.

Because its contain calcium hydroxide Sealapex acts stimulating bone repair and maintain the canal free of microorganisms while it promotes periapical healing.

Base:	CALCIUM HYDROXIDE 25% ZINC OXIDE 6,5%.
Catalyst:	BARIUM SULFATE 18,6% TITANIUM DIOXIDE 5,1% ZINC STEARATE 1%

The main cone was Selected: N° 80 (which coincides with the memory instrument preset during the surgical preparation). The adjustment in the conduit was verified taking into account to keep the 18 mm length according to the references already established. Then it was immersed in NaOCl to disinfect the gutta-percha and proceeded to the choice of spacers, which were fitted with rubber stoppers to 2 o 3 mm short of the surgical preparation length With a Lentulo spiral in micro motor the cement was carefully carried to the N° 21 tooth, and then the main cone was cemented. Lateral condensation spaces to the bigger side of the tooth, in this case distally, was done, placing fine accessory gutta-percha cones until the root canal was filled and not enter more accessory cones (Cold Lateral Condensation Technique). Finally, a Landmore instrument was heated to cherry red to cut the cones either just at the conduit inlet and then they were compacted manually with vertical condenser with gentle apical pressure. Lastly a cleaning of the conduit inlet with a cotton swab soaked in alcohol was carried out, also eliminating residual cement sealant. The opening cavity was plugged with zinc phosphate cement. The final radiograph is taken which shows a good seal at the apical level, regular in the middle and mesial parts of the conduit, good seal at the coronal level with continuity between the gutta-percha and the phosphate cement, which ensured against possible leaks.

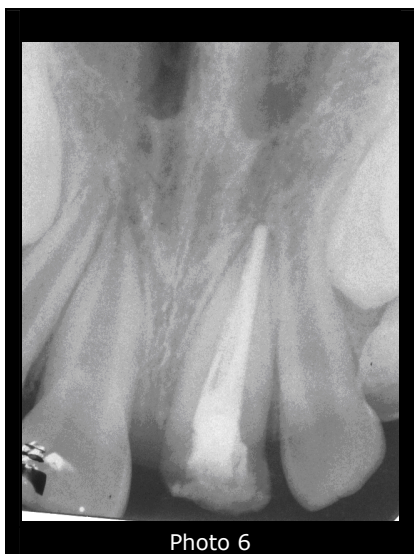

Photo 6



A week later, the patient was referred to the Department of Periodontics and Orthodontics. He is asked to attend for a check-up at six months.

Professionals Dentists in charge of the mentioned chairs, being aware of the case, and after evaluating the different options, decide, due to the child's age and the amount of attached gingival, that a Coronary Orthodontic Extrusion, was the most appropriate.

The extrusion consists, basically, of a coronal root movement produced by the application of orthodontic forces. This "dental eruption" produces the expansion of periodontal and gingival fibers dragging the entire periodontium and obtaining a coronal migration of the alveolar crest and the gingival margins.

The first thing done was the acid-etching of a small surface of enamel that was exposed in the N° 21 teeth, an orthodontic button that was set when composite polymerization and braces on teeth N° 11, 12 and 22 were set. A stainless steel wire was carved and placed into the root canal. Traction began, first with wire and then with rubber band without any type of surgery, so the root along with the bone was tensed to coronal.

Then a syndesmosis was made fortnightly to eliminate the adhesion of fibers to the root so it was emerging trying to get a biological space for future reconstruction. This was visible with the change of the button to braces (which is larger), and the position of the interincisal papilla was maintained and it was even growing which gave a better aesthetic. The crown section was temporary rebuilt with composite and the interradicular with fiberglass. The total development of the child is expected to be able to implant an abutmen and final crown.

The objective of this technique is to preserve bone, periodontal ligament, the inserted gingiva, so an acceptable periodontal gingival health is achieved. The extraction and implant placement are not recommended because the child's growth is not over, and if this root was removed the bone would be lost altering the bone development.

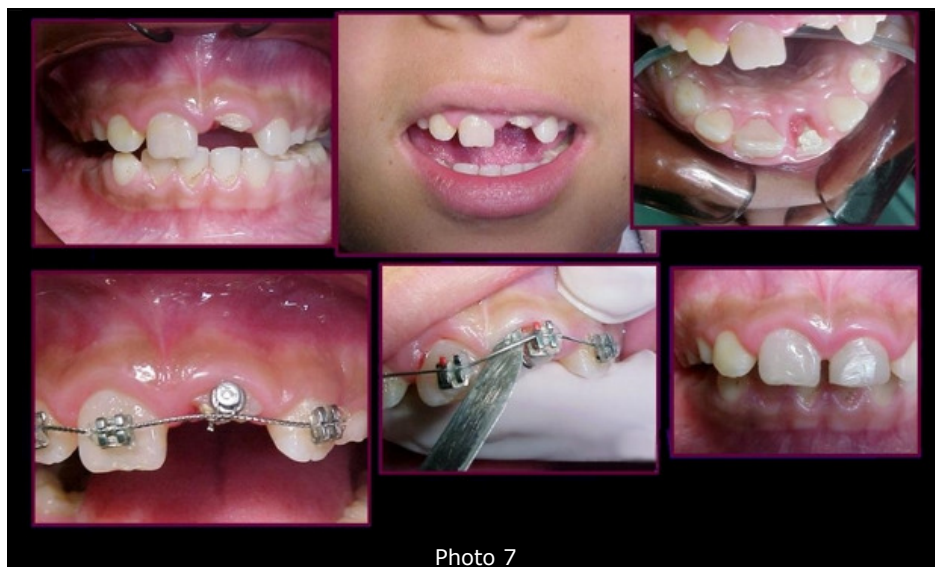

Photo 7

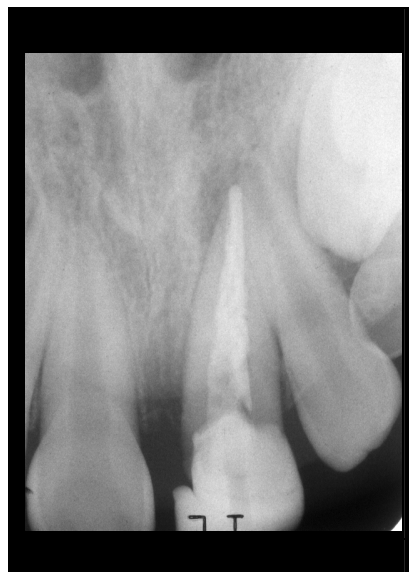**First clinical and radiographic control:** After seven months: March 2011.

After seven months of endodontic as well as orthodontic and periodontal treatment, the patient attends the established control. The performed restoration was hold in his mouth with good adaptation and quite acceptable aesthetic. The biological space occupied by the interincisal papilla was very well preserved, if we consider the characteristics he had when he arrived to the first consultation after the accident. There was not pain, fistula, edema or tumours. Neither symptoms to the vertical and horizontal soft percussion.

It was radiographically observed a radiolucent image at apical that could be developing tissue. When the periodontal ligament area, where there was displacement of alveolar cortical to mesial and central, is observed it appeared completely healed.

The radiopaque image of the restoration appears well suited distally but somewhat deficient mesially.

Second control established at 5 or 6 months.



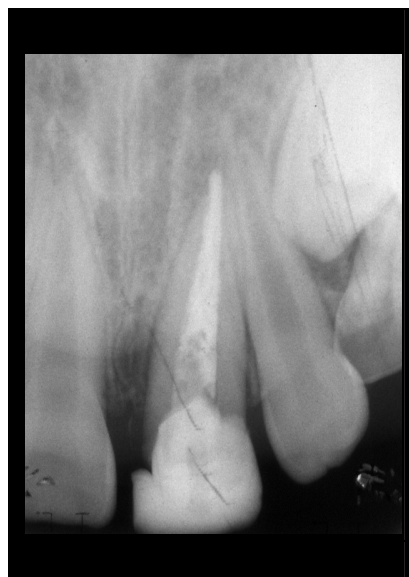**Second clinical and radiological control:** August 2011.

After a year of the final filling, the patient still has the aesthetic restoration made in the mouth by colleagues and in perfect biological clinical and functional state, just like he was five months ago, in the first control. He does not show any symptoms, he is in complete clinical normality, without fistulas, edema, mobility or tumor.

The radiograph shows a visible apical healing and repair improvement. Plastic restoration has the same characteristics that in the previous control.

It can also be observed the ectopic eruption of the permanent canine impacted on the N° 22 lateral, because of lack of space due to be still in the mouth the temporary canine. So he was referred to the orthodontics chair for evaluation.

Note that the final restoration has not yet been completed due to the patient's age and waiting for the full development of the root.



### Case Evaluation:

The restoration of a tooth destroyed at the alveolar crest level, is compromised from the biological and restorative point of view. If the tooth is restored under these circumstances, we will be ignoring the biological dimensions of space and it will be needed to further the margins of our restoration, in order to be able to display them in a healthy tooth structure. The result will be a poor gingival response for the transgression of epithelial and conjunctive insertions. Given a situation like this, we should expose healthy dental structure that allows us to place our restoration margins respecting the dimensions of the biological space. Thus, the extrusion is proposed as an alternative to extraction or to the crown lengthening surgery.

Taking into account the extent of injury with which the patient comes to the Specialty, I can say that this is a successful case, since the chances of keeping the tooth in the mouth were almost impossible.

The patient has not clinical symptoms; there are no fistulas, mobility, or pain on chewing. Despite showing a provisional restoration the gingival tissues are completely normal and healthy, even more the interincisal papilla is in its biological space giving aesthetic back.

From the beginning of the treatment until the last radiographic control, it is observed at apical level that the periodontal ligament space has dwindled. The root has been slowly matured and it is possible to see a closing line that appears already closing the root, reaching maturity and apexification. The radiographic image of the last control suggests a slow restoration at the apical level where there are no signs of bone resorption or post-treatment pathology. The alveolar cortical doesn't seem to recover, they are still hazy, and at the mesial side more reabsorption could be seen.

